This is a digital copy of a book that was preserved for generations on library shelves before it was carefully scanned by Google as part of a project to make the world's books discoverable online.

It has survived long enough for the copyright to expire and the book to enter the public domain. A public domain book is one that was never subject to copyright or whose legal copyright term has expired. Whether a book is in the public domain may vary country to country. Public domain books are our gateways to the past, representing a wealth of history, culture and knowledge that's often difficult to discover.

Marks, notations and other marginalia present in the original volume will appear in this file - a reminder of this book's long journey from the publisher to a library and finally to you.

Usage guidelines

Google is proud to partner with libraries to digitize public domain materials and make them widely accessible. Public domain books belong to the public and we are merely their custodians. Nevertheless, this work is expensive, so in order to keep providing this resource, we have taken steps to prevent abuse by commercial parties, including placing technical restrictions on automated querying.

We also ask that you:

+ *Make non-commercial use of the files* We designed Google Book Search for use by individuals, and we request that you use these files for personal, non-commercial purposes.

+ *Refrain from automated querying* Do not send automated queries of any sort to Google's system: If you are conducting research on machine translation, optical character recognition or other areas where access to a large amount of text is helpful, please contact us. We encourage the use of public domain materials for these purposes and may be able to help.

+ *Maintain attribution* The Google "watermark" you see on each file is essential for informing people about this project and helping them find additional materials through Google Book Search. Please do not remove it.

+ *Keep it legal* Whatever your use, remember that you are responsible for ensuring that what you are doing is legal. Do not assume that just because we believe a book is in the public domain for users in the United States, that the work is also in the public domain for users in other countries. Whether a book is still in copyright varies from country to country, and we can't offer guidance on whether any specific use of any specific book is allowed. Please do not assume that a book's appearance in Google Book Search means it can be used in any manner anywhere in the world. Copyright infringement liability can be quite severe.

About Google Book Search

Google's mission is to organize the world's information and to make it universally accessible and useful. Google Book Search helps readers discover the world's books while helping authors and publishers reach new audiences. You can search through the full text of this book on the web at `http://books.google.com/`

LANE MEDICAL LIBRARY STANFORD
2 45 0172 8119

LANE

MEDICAL LIBRARY

LEVI COOPER LANE FUND

TRAUMATIC
INJURIES OF THE BRAIN
AND ITS MEMBRANES

WITH A SPECIAL STUDY OF
PISTOL-SHOT WOUNDS OF THE HEAD
IN THEIR MEDICO-LEGAL AND
SURGICAL RELATIONS

LANE LIBRARY

BY

CHARLES PHELPS, M. D.

SURGEON TO BELLEVUE AND ST. VINCENT'S HOSPITALS

WITH FORTY-NINE ILLUSTRATIONS

NEW YORK
D. APPLETON AND COMPANY
1897

LANE LIBRARY

COPYRIGHT, 1897,
BY D. APPLETON AND COMPANY.

W593
P54
1897

PREFACE.

THIS work is designed to be a concise and systematic exposition of the injuries which the brain suffers from external violence, a division of brain surgery which has the greatest practical importance and has received the least careful attention. It is believed that it will not only be of interest to surgeons, but will meet the requirements of general practitioners in whose experience such injuries are infrequent, and who in exceptional instances have urgent need of the aid to be derived from a wider clinical observation than their own opportunities have permitted. It has been based essentially, if not exclusively, upon an observation of five hundred consecutive cases of recent occurrence. These cases are so large in number, and so varied in character, and in so many instances are complete in the record of essential historic and necroscopic detail, as in themselves to afford material for a comprehensive history of intracranial traumatism. The picture they represent is incomplete only in the illustration of secondary pyogenic infection involving the brain substance. In view of this clinical deficiency, the consideration given to cerebral abscess has been supplemented by some account of the conditions of septic invasion and of the degenerative processes which it occasions, abstracted, by permission of the distinguished author, from Macewen's "History of the Pyogenic Inflammations of the Brain and Spinal Cord."

The generalizations which have been made, and the conclusions which have been reached, from clinical observation, have been verified in each instance by necroscopic examination.

In an appended series, all those cases in which necropsy was had, and a certain number of others which terminated in recovery or in which necropsy was otherwise impracticable, have been collated. This course has permitted the preservation of continuity in the text by the omission of interpolated illustrative cases, has afforded a means for the disproval of possible unwarranted or erroneous deductions, and has preserved much material for the use of independent observers hereafter. They have been classified simply from their relation to cranial fractures, and this, though an imperfect method of classification, is, by reason of the multiplicity of lesions in individual cases, the only one which has seemed practicable.

The lesions which attend pistol-shot wounds of the head have been considered apart from general injuries, as a method more clearly presenting their distinctive characteristics. Their complete history has necessitated an abstract of the results of a series of cadaveric experiments, instituted to determine for legal purposes the extent to which the conditions under which they have been inflicted can be predicated from the appearances they present. These observations have been sufficiently extensive to better define not only the positive value, but the limitations, of medical evidence in such cases than has been heretofore possible.

This portion of the work which directly concerns medical jurisprudence is especially designed for the use of the legal profession in more precisely estimating the proper weight to be given to expert testimony in cases of this character.

The author has much pleasure in acknowledging his indebtedness to his colleagues of the Fourth Surgical Division of Bellevue Hospital, Dr. Jno. W. S. Gouley and Dr. Wm. F. Fluhrer, and of the Surgical Service of St. Vincent's Hospital, Drs. Stephen Smith, Frederick S. Dennis, and Jos. D. Bryant, through whose courtesy his opportunities for clinical observation have been greatly ex-

tended. He is also under very great obligation to successive house staffs of the same hospitals, and to the medical officers of the Coroner's Office during the past six years for the constant aid and co-operation which have made possible the collection of the great mass of facts which the nature of this work has involved. He has finally to make acknowledgment of the skilled marksmanship and otherwise valuable assistance rendered to him by Drs. J. H. Titterington, Henry L. Whitener, and Harry L. Hibbard, late of Bellevue Hospital, and by Drs. John Freeland and Jno. D. Gorman, in the difficult and laborious task of cadaveric experimentation.

34 West Thirty-seventh Street,
July, 1897.

TABLE OF CONTENTS.

PART I.

General Traumatic Lesions.

A PRELIMINARY CONSIDERATION OF CRANIAL FRACTURE.

PAGE

Classification of Injuries of the Head, ... 1
Cranial Fracture, ... 2
Classification, ... 2
Fracture of the Cranial Base, ... 3
Direct and Indirect, ... 4
Mechanism, ... 6
Complications of Cranial Fracture, ... 11
Symptomatology and Diagnosis, ... 12
Fractures of the Vault, ... 12
Fractures of the Base, ... 13
External Hemorrhages of Cranial or Intracranial Origin; . . 13
their Comparative Frequency in Different Forms of Basic Fracture, ... 14
their Diagnostic Value, ... 18
Escape of Brain Matter, ... 21
Watery Discharges, ... 21
Œdema of the Mastoid Region, ... 23
Implication of the Cranial Nerves, ... 24
Localized Pain, ... 26
Indirect Symptoms from Intracranial Complication, . . . 27
Prognosis, ... 28
Concomitant and Consecutive Complications, ... 30
Treatment, ... 32
Shock, ... 33
Fracture of the Base, ... 33
Fracture of the Vault, ... 34
Incision, ... 35
Elevation of Depressed Bone, ... 36
Trephination, ... 39

CHAPTER I.

Pathology.

PAGE

Direct Lesions, ... 42
Classification, ... 42
Hemorrhages, ... 43
Epidural, ... 44
Pial, ... 46
Cortical, ... 46
Dangers of Hemorrhages, Shock, Exsanguination, and Diminution of Cranial Capacity, ... 48
Terminations in Absorption and Cystic Degeneration, . . . 51
Thromboses of Dural Sinuses, ... 52
Contusion, ... 53
General Contusion of the Brain, ... 53
Anatomical Conditions, ... 53
Duret's Theory of Displacement of the Cerebro-Spinal Fluid, . 55
Concussion and Compression, ... 56
Prescott Hewitt—Observations of Contusion, ... 56
Von Bergmann's Theory of Concussion and Compression, . . 57
Structural Alteration Attends All Brain Injuries, ... 58
Limited Contusion of the Brain, ... 59
Anatomical Conditions, ... 59
Contusion of the Meninges, ... 61
Hemorrhage, ... 62
Subarachnoid Serous Effusion, ... 62
Laceration of the Brain, ... 63
Anatomical Conditions, ... 63
Terminations, ... 66
Indirect Lesions—Secondary Inflammations, ... 68
Due to Accidental Infection of Primary Lesions, ... 68
External or Distant Origin of Pathogenic Germs, ... 71
Infrequency of Occurrence, ... 73
Macewen's History of Intracranial Infection, ... 74
Acute Leptomeningitis, ... 77
Acute Serous Leptomeningitis, ... 77
Purulent Leptomeningitis, ... 78
Red Softening, ... 79
White Softening, ... 79
Cerebral Abscess, ... 80
Secondary Abscess, ... 83
Pyogenic Abscess, ... 83
Necrosis of Cerebral Tissue, ... 84
Localization of Primary Lesion Determines the Alternative of Meningitis or Abscess, ... 85
Possibility of Intracranial Inflammation without Infection, . . 86

PAGE
Arachnitis a More Exact Term than Leptomeningitis, ... 88
Encephalitis Always Pyogenic, ... 89
Cirrhotic Inflammation—Atrophy, ... 89

CHAPTER II.

Symptomatology.

Direct Lesions, ... 91
Hemorrhages, ... 92
Unconsciousness, ... 93
Delirium, ... 95
Condition of the Pupils, ... 95
Temperature, ... 97
Pulse, ... 98
Respiration — Marked Infrequency from Compression of the Medulla, ... 99
Tabulation of Cases, ... 100
Cyanosis and Pulmonary Œdema, ... 103
Psychical Disturbances, ... 104
Influence of Complications, ... 104
General Contusion of the Brain, ... 107
Variability of Symptoms, ... 108
Severe Cases, ... 108
Mild Cases, ... 111
Cases Complicated by Hemorrhages, ... 113
Limited Contusion of the Brain, ... 114
Laceration of the Brain, ... 115
Temperature, ... 116
Pulse and Respiration, ... 121
Asymmetrical Radial Pulsation, ... 122
Condition of the Pupils, ... 124
Loss of Consciousness, ... 125
Psychical Disturbances, ... 126

CHAPTER III.

Symptomatology—*Continued.*

Symptoms Indicative of the Localization of Lesions, ... 129
Mental Disorders in Cases of Laceration of the Frontal Lobes, . . 129
Differences in Symptomatology as the Right or the Left Frontal Lobe, or as the Superficial or Deeper Portion of the Left Lobe, is Involved—Tabulation of Cases, ... 130
Illustrated by Histories of Pistol-Shot Wounds, ... 136
Conclusions, ... 138

PAGE

Derangements of Muscular Action, ... 138
Paralysis, ... 139
Incoördination, ... 139
Clonic and Tetanic Spasm, ... 139
Symptoms from Lesion of Corpus Striatum, ... 141
Optic Thalamus, ... 141
Fornix, ... 142
Gyrus Fornicatus, ... 142
Pons, ... 143
Temporal Lobe, ... 143
Conjugate Deviation, ... 146
Loss of Urinary and Fæcal Control, ... 147
Secondary Inflammations, ... 148
Arachnitis, ... 148
General Symptoms, ... 150
Abscess, ... 153
Superficial, ... 153
Deep, ... 154
Analysis of General Symptoms, ... 157
Localizing Symptoms, ... 159
Progress and Terminations, ... 161

CHAPTER IV.

Diagnosis.

Direct Lesions, ... 164
Unconsciousness as a General Indication of Traumatic and Idiopathic Lesions, ... 164
Characteristics of Opium Narcosis, ... 165
" " Uræmic Coma, ... 166
" " Apoplectic Coma, ... 166
" " Alcoholic Coma, ... 166
" " Traumatic Coma, ... 167
Diagnosis of Traumatic from Alcoholic Coma, ... 168
Coexistence of the Two Conditions, ... 169
Temperature, ... 170
Delirium, ... 171
Diagnosis of Traumatic from Apoplectic Coma, ... 172
Coexistence of the Two Conditions, ... 172
Diagnosis of Traumatic from Opium Narcosis or Uræmic Coma, . 173
Differentiation of Traumatic Lesions from Each Other, . . . 174
Comparative Symptomatology, ... 174
Unconsciousness, ... 175
Temperature, ... 176
Respiration, ... 177
Pulse, ... 177

PAGE

Condition of Pupils, ... 179
Mental Disturbances, ... 180
Muscular Disorders, ... 181
Loss of Urinary and Fæcal Control, ... 182
Aphasia—Not from Hemorrhage, ... 182
Unconsciousness, Temperature, Pulse, and Respiration, as the Essential Factors in Diagnosis of Intracranial Lesions, . . 185
Secondary Inflammations, ... 185
Arachnitis, ... 185
Abscess, ... 188
Diagnosis, when of Early Formation, from Primary Contusion, . . 188
Diagnosis, when of Later Development, from Results of Vascular Lesions and from Tumor, ... 189
Symptoms Common to All Organic Diseases of the Brain, . . . 190
Symptoms Common to Abscess and Tumor, ... 190
Diagnosis of Abscess from Tumor, ... 191

CHAPTER V.

Prognosis.

Direct Lesions, ... 193
Statistical Results in Five Hundred Original Cases, ... 193
Relative Danger of Fractures of Cranial Base and Vertex Dependent upon Complications, ... 195
Relative Danger of Different Intracranial Complications, . . . 195
Analysis of Recovering Cases, ... 198
Prognostic Indications from Individual Symptoms, ... 201
Secondary Inflammations, ... 204
Arachnitis, ... 204
Abscess, ... 205

CHAPTER VI.

Principles of Treatment.

Direct Lesions, ... 206
Shock, ... 206
Operation for Intracranial Injuries, ... 208
Epidural Hemorrhage, ... 208
Conditions of Operation, ... 210
Subdural Lesions, ... 212
Pial and Cortical Hemorrhages, ... 212
General Contusion, ... 214
Laceration of the Brain, ... 215
Arachnitis, ... 216
Summary, ... 217
Late Pathic Conditions, ... 219
Dangers of Operation, ... 220

PAGE

General Conduct of Operation, ... 222
General Treatment, ... 223
Secondary Inflammations, ... 227
Arachnitis, ... 227
Abscess, ... 228
Superficial, ... 228
Deep, ... 230

PART II.

PISTOL-SHOT WOUNDS OF THE HEAD.

CHAPTER VII.

MEDICO-LEGAL RELATIONS.

Observations Made upon the Cadaver, ... 235
Extracranial Lesions, ... 239
0.38 cal., Head, ... 239
0.38 cal., Body, ... 250
0.32 cal., Head, ... 254
0.44 cal., " 260
0.22 cal., " 266
Generalization of Results, ... 276
Modifying Conditions, ... 286
Characteristics of Cutaneous Wound of Exit, ... 289
How far Wounds Inflicted during Life Differ from Those Produced in Cadaveric Experimentation, ... 290
Comparative Importance of Different External Conditions Enumerated in Estimating Range and Calibre, ... 292
Medico-Legal Importance of the Study of These Lesions, and the Necessity of Sufficiently Extended Experimentation, . . . 295
Decisive in only a Limited Number of Cases, ... 297
Cranial Lesions, ... 297
Peculiarities Common to all Calibres of Ball, ... 298
Cranial Penetration, ... 298
0.44 cal., Pistol of Most Efficient Type, ... 300
0.44 cal., Pistol of Inferior Type, ... 302
0.38 cal., ... 302
0.32 cal., ... 304
0.22 cal., ... 306
Modifying Conditions, ... 308
Dimensions of Cranial Wounds, ... 312
0.44 cal., ... 312
0.38 cal., ... 312
0.32 cal., ... 314
0.22 cal., ... 314

PAGE
Summary, ... 314
Cranial Wounds of Exit, ... 315
Cranial Comminution and Fissuring, ... 320
0.44 cal., ... 320
0.38 cal., ... 322
0.32 cal., ... 324
0.22 cal., ... 324
Intracranial Lesions, ... 326

CHAPTER VIII.

Surgical Relations.

Symptomatology, ... 334
Profundity of Unconsciousness, ... 337
Immediate Subjective Symptoms, ... 338
Diagnosis, ... 342
Fluhrer's Probe, ... 344
Nélaton's Probe, ... 344
Girdner's Telephonic Probe, ... 345
Use of Röntgen Rays, ... 346
Acupuncture, ... 348
Diversion of the Bullet, ... 349
Examination of the Eye and Orbit, ... 350
Examination of Cervical Region, ... 351
Treatment, ... 353
Shock, ... 353
Several Views as to Further Treatment, ... 354
Illustrations from Published Cases, ... 355
Results of Expectant Treatment, ... 356
Incision of Dura Mater, ... 358
Operation with a View to Drainage only, ... 360
Analysis of Published Cases with Reference to the Results of Retention of Bullets within the Cranial Cavity, ... 360
Conclusions, ... 366
Analysis of Published Cases with Reference to the Comparative Danger of Retention and Removal of Bullets Deeply Situated within the Cranial Cavity, ... 366
Conclusions, ... 370
Treatment of Superficial Wounds of Entrance and Exit, . . . 371
Exaggerated Estimate of the Danger of Operation, ... 372
Details of Operation, ... 375
Counter-Operation, ... 379
Circumstances Adverse to Counter-Operation, ... 382
Disinfection and Drainage, ... 384
Prognosis, ... 387
Statistics, ... 387
Treatment, ... 390

THE CONDENSED HISTORIES OF THREE HUNDRED INTRACRANIAL TRAUMATISMS.

CASES VERIFIED BY NECROPSY.

PAGE

Fractures of the Cranial Base, ... 395
Fractures of the Cranial Base from Pistol-Shot Wound, . . . 477
Fractures Confined to the Cranial Vertex, ... 493
Fractures Confined to the Cranial Vertex from Pistol-Shot Wound, . 503
Encephalic Injuries without Cranial Fracture, ... 513

CASES UNVERIFIED BY NECROPSY.

Unclassified 537

Intracranial Lesions from Pistol-Shot Wounds with Recovery, . . 577

INJURIES OF THE BRAIN AND OF ITS MEMBRANES.

PART I.

GENERAL TRAUMATIC LESIONS.

A PRELIMINARY CONSIDERATION OF CRANIAL FRACTURE.

INJURIES of the head may be topographically classified as superficial or extracranial, cranial, and intracranial.

These may occur independently or may variously complicate each other.

The external injuries may be excluded as of no importance in a consideration of intracranial lesions except as aids in diagnosis, and in the case of cutaneous wounds, as a possible means of infection in meningitis or in the course of cerebral abscess.

The cranial injuries are contusion and fracture, and of these contusion followed by consequences of moment is infrequent and has no closer relation to intracranial injury than have contusions of the more superficial parts. Fractures so usually complicate, or are complicated by, structural changes in the brain or its meninges; and are often so directly connected with the pathic results of intracranial lesions, either by osteal hemorrhage or by affording a channel for the invasion of septogenic germs, as to justify some particularity of attention to their peculiarities.

Fracture.

The classification of fractures of the cranium is primarily the same as of fractures of other bones:

I.

Simple.
Compound.
Comminuted.
Complicated.

II.

Complete.
Incomplete.

III.

Direct.
Indirect.

Secondarily or specifically they may be again subdivided:

I.

Fractures of the vault.
Fractures of the base.

II.

Linear or fissured.
Punctured.
Depressed.

The last may be either singly or doubly camerated.

A much simpler and therefore better classification, which has the additional advantage of a definite relation to diagnosis, prognosis, and treatment, may be derived from the one just presented.

I.

Integral.
  Complicated.
  Non-complicated.

II.

Regional.
  Fractures of the vault.
  Fractures of the base.

Fractures of either the vault or base may be simple, compound, or comminuted, punctured, linear, or depressed, direct or indirect, though the relative frequency of these subdivisions varies greatly in the two primary forms. Fractures of the base are ordinarily simple and linear, while those of the vault are not infrequently compound, comminuted, depressed, or punctured. Both are almost invariably caused by direct violence, and, while both may be either complicated or non-complicated, a complication in fracture of the base is more characteristic and often occasions not only differences in prognosis but in methods of diagnosis and requirements of treatment. The presence or absence of a complication is of essential importance, and as its recognition, probable result, and treatment may be influenced by the region of injury, the corresponding divisions of fracture, whether or not they are accepted as a formal basis of classification, must always be those of the greatest practical value. The other distinctions which may be made in the characters of a fracture, if not insignificant, are at least of minor importance; whether the osteal wound be simple or compound, linear or depressed, or comminuted, is of little moment in view of the present

resources of surgery; and one is often converted into the other in the course of preliminary examination.

All fractures which involve the base, though originating in the vault, are to be regarded as basic, because it is upon the implication of this region that their characteristic conditions depend. In a certain number of cases, violence is inflicted through the eye, nose, or mouth, or inferior temporal region, by bullets or exceptionally by sharp-pointed instruments; but exclusive of these there are few instances in which a fracture of the skull does not have its beginning in the vault. In the appended series of cases, as verified by necropsic examination, there are 146 fractures of the base, of which 18 were from pistol shot and 1 from another form of violence directly applied to the point of basic lesion; there are 34 fractures confined to the vault, of which 14 were from pistol shot; in 147 fractures of the vault, therefore, not of pistol-shot origin, the base was implicated in 127. There existed in but 12 of the 127 a basic fissure independent of a fracture of the vault, and in several (6) of these another fissure extended from vault to base. These 12 cases in which force was indirect, that is to say, in which the fracture began and ended in the base, though the force was applied to the vault at a distance and transmitted through parts which maintained their integrity, are instances of what has sometimes been called injury by *contrecoup*, and similar to what is much more frequently encountered in the brain. In each case by the history as well as by existent wound or contusion, it was proven that the force was primarily exerted upon the vault, nor was there in any one the slightest reason to suspect that the effect of violence had been conveyed through the spinal column. The concurrence of direct

fracture was noted in 6 cases and there was intervening brain laceration in all but 2. The direct force in 6 cases was applied to the parietal region, and in 3 of these was transmitted to an orbital plate or to the crista galli and sphenoid surface; in 5 it was applied to the occiput, and in 3 of these also was transmitted to the orbital plates; but in the others the indirect fracture was produced in the middle or posterior fossa or upon the surface of the intervening petrous portion. It is evident therefore that it is not always the most fragile portions of the cranium which give way. In 10 of the 12 cases the counterfracture was no more than a fine short fissure, which could have had no influence in the display of symptoms and could be of no real importance in contravening the general statement that fractures of the base are continuations of fissures which have their origin in the vault at the point of injury. In the 2 cases remaining the counterfracture was directly contributive to the death of the patient. In one the fissure widely curved through both orbital plates and the fractured edge of each was raised and tilted forward, and on the right side it deeply lacerated the base of the frontal lobe; the frontal sinus was also opened into the cranial cavity. In the other a smaller osseous lesion was no less disastrous; the fissure was fine and extended only from the anterior inferior angle of the parietal bone across the squamous portion of the temporal to the petrous junction, but a minute triangular portion of the inner table was detached and had lacerated the arteria meningea media at its bifurcation with resulting profuse and fatal hemorrhage.

The conditions which govern the character and extent of cranial fractures are the violence of impact, the extent of surface involved, and the physical properties of the cra-

nium, its elasticity, composite structure, degree of thickness or density, and its vaulted form. The concentration of force when the head is struck by an object of limited size and definite outline tends to the production of comminuted and depressed fractures confined to the region of impact. The diffusion of force when the head itself is the impinging object, as in falls from a distance, equally leads to extended fissures with or without crushing at the point of direct injury. The observation of cases, however, shows that the physical properties of the cranial vault are ordinarily such that even when force is concentrated, if the instrument of violence be other than a pistol shot or some sharp weapon, the effect is much more than likely to be diffused. A great degree and concentration of violence and a tenuity or brittleness of a part undoubtedly favor restriction of fracture to the site of injury, as wider diffusion of force and the elasticity and average density of the skull account for its more frequent extension by fissure to a distance.

The precise mechanism of basic fracture has been experimentally investigated by various surgeons, who have arrived at somewhat different conclusions. The recent summary of the opinions of these experimenters by Roswell Park, in Dennis' "System of Surgery," precludes the necessity for their repetition.

The usual basic fracture unquestionably extends between the region in which primary injury is received and the corresponding basic fossa of the same side; and the explanation of Aran, that force follows the shortest anatomical route and in the direction in which there is least resistance, seems adequate. If the middle fossæ, alone or in contiguity, suffer oftener than the others, it is because

the middle region of the vault is most exposed to violence. If force is too great for its entire expenditure at the point of impact, or resistance too obstinate, it traverses the bone till exhausted; that it should be propagated in direct lines, modified only by inequalities of resistance, is as plainly in accordance with natural laws as the riving of wood or iron by the wedge. In some instances the force is too great to be restrained by any resistance which it may encounter, and transgresses the limits which may be set by "natural buttresses," or abandons the squamous to follow its direct course through the denser petrous portion. The theory of Hare, that the elastic skull, compressed between two poles, like a melon gives way in the middle, and that the fracture extends in both directions, seems far-fetched and not substantiated by appearances which the fissures present when examined for corroboration. The comparison of the exact site of superficial contusion with the commencement of a linear fracture of the vault indicates that not infrequently force may be transmitted through the bone for a certain distance before disruption begins.

The limited number of cases in which independent fractures, more or less trivial, occur at the base, with or without a fracture of the vault, are less readily explained by the direct propagation of force through the cranial wall. The brain substance and the bone have each been regarded as the medium of transmission. In the well-known case of the assassination of a president of the United States, in which a pistol-shot fracture of the occiput, with lodgement of the bullet near the corpus striatum, caused comminution of both orbital plates, Mr. Longmore believes that the orbital fracture was due to "transmitted undulatory strokes or sudden impulse of the brain substance against these

bony layers." This may be possible in so thin and fragile laminæ as the orbital plates, but it is insufficient to explain the fissuring of bony parts so dense as the petrous portion of the temporal, or the floor of a middle or posterior basic fossa. There are also the special defects in Mr. Longmore's explanation of the counterfracture in the case quoted, that it ignores the fact that the direction of force was parallel to the orbital surfaces, and that it fails to account for the upward dislocation of the fragments. In simple counterfissure of the base, it would seem more probable that the distant lesion was due to the direct transmission of force through the bone. In view of the numerous instances in which force is transmitted for a limited distance through the lateral wall of the vault before cleavage begins, it is not illogical to suppose that in others exceptionally noted its course should have been even longer continued before its eruption. In counterfissures confined to the petrous portion or to the contiguous basic fossæ, it is scarcely possible to conceive, though the skull might be compressed to the point of bursting, that the rupture should have occurred in its most rigid if not absolutely inelastic portion. The effect of distant violence, in causing not only indirect fracture but limited osteal hyperæmia and extravasation, is illustrated in Case CXXV. of the appended series and represented in Fig. 44. There are occasional indirect basic fractures which are more readily explicable, or even necessarily dependent, upon the supposition that the skull has been violently compressed. In Case CIV. of the appended series, the circumstances of injury and the effects which it produced concur to make this explanation inevitable. The head was struck upon the occiput by a descending elevator and forced forward, with

the chin resting upon an iron railing as an approximately fixed point. Fracture was confined to the anterior basal fossæ, and extended from the posterior border of the cribriform plate upon the right side by a wide sweep outward and forward, and then inward through both orbital plates. The roof of the orbit was elevated and tilted forward, and the frontal sinuses were opened into the cranial cavity. Continued force and resistance acted at the extremities of the occipito-mental diameter, and violent disruption occurred in a vulnerable region at its centre. In a recovering case, No. CCLIX., in which force was similarly applied, fracture through the anterior and middle fossæ into the petrous portion was doubtless produced by the same mechanism.

It is impossible to believe that the mechanism of fracture is always the same. In a careful necropsic examination of cranial fractures included in the appended series of cases, there are a rather limited number which immediately involve the base, all but one from bullet wound, and a scarcely larger number which may be termed indirect and are of questionable origin. All the others, more than ninety per cent. of the entire number, are the result of violence inflicted upon the vault, and of these more than seventy-eight per cent. extend to the base. If pistol-shot fractures be excluded, the percentage of those which extend from vault to base is increased to eighty-five. The inspection of basic fractures of this predominating class has suggested nothing but an origin at the point of injury. They negative in their appearance Hare's opinion that diffuse blows produce their effect at a distance from the point of application, and, as such evidence is entitled to more weight than conclusions, which must be

more or less theoretical, derived from experimentation upon the cadaver, these fractures must be regarded as in general the product of direct violence. The very small proportion of basic fissures which are obviously indirect are very likely of variable as well as questionable origin; apart from such unusual antecedent conditions as severe and demonstrable compression of the head between two fixed points, exemplified in Case CIV., they afford no positive etiological data; whether force is generated by insupportable distortion of the elastic vault, or is transmitted like the electric current without change in the osseous structure traversed to its point of discharge in some basic region, or is propagated by undulations in the brain substance, is a problem still confined for its solution to the domain of theory and of individual probability. These indirect fractures have been called *contrecoup*, since they are developed in a region directly or approximately opposite to that in which violence has been inflicted, and the term may be conveniently and allowably retained without involving a theory of their production; its application to fissures of the base which are continuous with fractures of the vault is unwarranted.

A study of the one hundred and eighty cranial fractures in the appended series of original cases which were subjected to post-mortem examination discloses many facts concerning the details of their character and mechanism which are of interest and value, but are not essential to the discussion of intracranial lesions.

The peculiarities of depressed, comminuted, or perforating forms of cranial fracture are adequately described in general text-books of surgery. Simply as osseous lesions they have been robbed of their significance by ad-

vancements in the methods of surgical practice. In their greater liability to intracranial complication they retain their special importance; a degree of violence sufficient to comminute the bone is likely to extend its effects to the subjacent structures; depressed fragments become new sources of injury; and perforating fractures almost necessarily involve cerebral or dural wound. Their results are more serious and their treatment demands more active intervention than do simple fissures, but it is by reason of the complication rather than by the greater injury which the bone has sustained. The necessity of removing comminuted or of elevating depressed fragments of bone scarcely increases the gravity of prognosis. The most insignificant fissure may be associated with fatal intracranial hemorrhage, while the largest comminution, if uncomplicated, may be devoid of danger. It is the complication and not the fracture which dominates the case.

The complications of cranial fracture are cerebral and meningeal, and in either one may be laceration, contusion, hemorrhage, or septic inflammation; and to these may be added hemorrhage from the osteal vessels. The septic inflammations are rather sequelæ than complications, since they are not direct products of the same violence which causes the fracture, but the result of a later infection for which the fracture has afforded opportunity. All these conditions may equally occur in the absence of fracture, as primary and independent lesions, and as such will be given later consideration. Fractures which are practically uncomplicated may occur both in the vault and in the base, though some degree of cerebral contusion will probably attend even the most inconsiderable of simple fissures. If

the symptoms of this contusion are trivial and transient, it may be properly disregarded in classification as well as in treatment.

Symptomatology and Diagnosis.

The very frequent coincidence of fracture with intracranial lesion has led to much confusion in symptomatology and consequent prognosis. Loss of consciousness and variations in pulse, temperature, and respiration, with other undoubted indications of intracranial complication, are still enumerated among the symptoms of fracture. These inaccuracies are of consequence, since a lack of well-defined conception of the nature of lesions or of the significance of symptoms begets errors of treatment.

The direct effects of fracture are few and usually not difficult to discover. It may be briefly stated that fracture of the vault is to be recogized by tactile or visual sense; that these methods are always practicable; that no others are defensible; and that there is no justification for the neglect to resort to both when one is insufficient for exact diagnosis. If the fracture be compound, there can be no doubt of its existence, provided the wound be of sufficient size to disclose the osseous surface; if the wound be too small for thorough exploration, the fracture may be regarded as essentially of the simple variety. The simple fracture, if depressed, may be often recognized by palpation through the layers of the scalp, but if doubt exists, or if from symptoms of intracranial complication suspicion arises, certainty should be reached by incision and direct inspection. This covers the whole ground of diagnosis—tactile or visual examination, and, if necessary to that

purpose, unhesitating and sufficient incision down to the cranial surface.

The diagnosis of fracture of the base is sometimes equally direct, but is oftener inferential, and it may be entirely conjectural. If continuous with a fracture of the vault which has attracted attention, it should be incidentally discovered in the course of the examination necessitated at the site of immediate injury, as fissures are readily traceable to a point at which their implication of the base becomes assured. In a very large proportion of cases, however, the basic fracture begins as a simple fissure at the vertex, or upon the lateral aspect of the vault, and with an absence of conditions which suggest direct exploration. The indications of intracranial injury may then afford reasons for inferring the existence of basic fracture, but not with absolute certainty, since the occurrence of independent traumatic lesions is not infrequent.

There is one direct symptom of the fracture which when present may be almost pathognomonic: it is an osteal or intracranial hemorrhage which through some channel becomes visible at or beneath the surface. Its source may be the vessels of the diploe, of the meninges, or of the brain, and its escape may be from the ear, nose, or mouth, or into the subconjunctival or subcutaneous cellular tissue. The fracture very generally traverses some portion of the base which permits the appearance of the blood externally in one or the other of these situations. The comparative frequency with which different basic regions are involved, and the significance of various external hemorrhages of internal origin, are suggested by a summary of these fractures included in the appended general series.

Fractures of the Base.

I. *Results.*

Recovered,	110
Died,	176

II. *Necropsies.*

Fractures continued from vault,	133
Fractures confined to base,	13

III. *Hemorrhages.*

Fractures with external hemorrhage,	67
Fractures without external hemorrhage,	61

IV. *Regions of Fracture and External Site of Hemorrhage* (pistol-shot fractures excluded).

1. *Petrous Portion.*

Hemorrhage from ear,	5
No hemorrhage,	4—9

2. *Petrous Portion and Middle Fossa.*

Hemorrhage from ear,	6
Hemorrhage from ear and nose,	2
Hemorrhage from ear, nose, and mouth,	1
No hemorrhage,	3—12

3. *Petrous Portion and Posterior Fossa.*

Hemorrhage from ear,	5
Hemorrhage, subcutaneous, mastoid,	1
Hemorrhage from ear and nose,	3
No hemorrhage,	3—12

4. *Petrous Portion;—Middle and Posterior Fossæ.*

Hemorrhage from ear,	6
Hemorrhage from nose,	3
Hemorrhage from ear and mouth,	1

Hemorrhage from ear, mouth, and nose, ... 2
No hemorrhage, ... 2—14

5. *Petrous Portion; Middle and Anterior Fossæ.*

Hemorrhage from ear, . . . 1
Hemorrhage from ear and nose, . 4
Hemorrhage from ear, nose, and mouth, ... 1
Hemorrhage from ear and nose and subconjunctival, . . 1
Hemorrhage, subconjunctival, . 1—8

6. *Both Petrous Portions and All Basic Fossæ.*

Hemorrhage from one ear, . . 1
Hemorrhage from both ears, nose, and mouth, ... 1—2

7. *Petrous Portion and All Basic Fossæ of the Same Side.*

Hemorrhage from ear, . . . 1
Hemorrhage from ear, nose, and mouth, ... 1—2

8. *Petrous Portion; Anterior and Middle Fossæ; Basilar Process.*

Hemorrhage from ear, nose, and mouth, ... 1

9. *Anterior Fossæ.*

Hemorrhage from nose, . . 2
Hemorrhage from nose and mouth, 1
Hemorrhage, subconjunctival, . 1
No hemorrhage, ... 5—9

10. *Middle Fossæ.*

Hemorrhage from nose, . . 3
Hemorrhage, subconjunctival, . 1

No hemorrhage, ... 13—17

11. *Posterior Fossæ.*

No hemorrhage, ... 21

12. *Anterior and Middle Fossæ.*

Hemorrhage from nose, . . 6

Hemorrhage, subconjunctival in both eyes, ... 1

Hemorrhage, subjunctival, in both eyes, nose, and mouth, . . 1

No hemorrhage, ... 5—13

13. *Posterior and Middle Fossæ.*

Hemorrhage from nose, . . 1

No hemorrhage, ... 4—5

14. *Posterior and Anterior Fossæ.*

Hemorrhage, nose, . . . 1

15. *Anterior, Middle, and Posterior Fossæ.*

Hemorrhage from nose, . . 1

No hemorrhage, ... 1—2

V. *Summary of External Sources of Hemorrhages.*

Hemorrhage from ear, . . 26

Hemorrhage from ear and nose, . 9

Hemorrhage from ear and mouth, 1

Hemorrhage from ear, nose, and mouth, ... 6

Hemorrhage from ear, nose, and subconjunctival, . . . 1

Hemorrhage from nose, . . 17

Hemorrhage from mouth, . . 1

Hemorrhage from nose, mouth, and subconjunctival, . . 1

Subconjunctival hemorrhage, . 4

Subcutaneous, mastoid hemorrhage 1—67

This study of hemorrhages has been confined to the first class of basic fractures, those in which fissure extends from a site of injury in some part of the vault. The cases in which fracture originates in the base are almost exclusively pistol-shot wounds, and are not often attended by distant hemorrhages and rarely involve a question of regional diagnosis.

The inferences to be derived from the tabular analyses are so obvious as scarcely to call for explanatory comment. It will be observed that hemorrhage from the ear has occurred in more than one-third of the total number of cases, in all of which the petrous portion has been implicated; that hemorrhage from the nose has occurred in more than one-fourth of all the cases, and when significant has followed fracture of an anterior fossa or of the anterior part of a middle fossa; that there has been subconjunctival hemorrhage in six cases, in all of which the fracture traversed an anterior fossa; that buccal hemorrhage has been noted three times, twice in conjunction with epistaxis; and that the subcutaneous hemorrhage resulted from an inclusion of the mastoid process in a fracture through the posterior fossa. The anatomical necessity which absolutely limits these external indications to fracture of positively definite regions is manifest. The causes of their frequent absence in fractures of the same arbitrarily defined basic fossæ are not less obvious. If the fracture of the petrous portion does not involve the auditory cavities, or that of the middle fossa involve the sphenoid bone, there can be no escape externally of the blood effused; if the fracture of the anterior fossæ does not traverse the ethmoid bone, and the injury to the orbital plates is trivial, the slight hemorrhage which it occasions

still fails of outlet; the only possible route by which blood extravasated in the posterior fossæ can reach the surface is through the fasciæ of the neck, except when the mastoid process is implicated, when it may force its way through the periosteum and be visible subcutaneously behind the ear. The amount of hemorrhage from an occipital fracture is insufficient often to penetrate the deeper cervical fasciæ, unless it be from a pistol-shot wound, and its becoming subcutaneous is only a recognizable possibility. The occurrence of a visible hemorrhage as an indication of simple fracture of the base depends upon the implication of the mastoid or petrous portions of the temporal, the ethmoid or sphenoid, or the orbital processes of the frontal bone; and its undoubted value as a symptom, positive or negative, is dependent upon the relation, suggested by Aran, which these parts bear to the regions of the vault most exposed to injury. The apparent proportion of basic fractures attended by external hemorrhage is somewhat diminished by the inclusion in the totality of cases of a certain number in which the early history was imperfect or absent, and in which the hemorrhage might have been present but was not assumed.

It is possible that these hemorrhages may occur as a coincidence rather than as a result of fracture, though their interpretation in such an event is not likely to be difficult. A hemorrhage from the ear accompanying a pistol-shot wound of the temporal fossa was found in Case CXXXVIII. to have resulted from a rupture of the tympanum by concussion, but extremities of violence by blows or falls upon the head, which have shattered the vault or base, have not incidentally produced a similar lesion, nor can such a result be expected under any conceivable circumstances apart

from the shock of an explosive at close contact. A wound of the external meatus may also occasion a moderate hemorrhage, or blood from a wound of the scalp which has filled this canal may be momentarily deceptive, but such sources of error are eliminated in the preliminary examination. If ordinary care be exercised in excluding these occasional non-essential hemorrhages, this direct symptom may be regarded as fairly pathognomonic. A failure to discover the wound of the tympanum is not material, since when linear it may be closed and invisible after hemorrhage has ceased, but a lesion of the external meatus cannot be hidden from observation.

The amount of blood which escapes from the ear, or the period at which hemorrhage occurs, its continuance, or its relation to serous discharges, while perhaps indicative of the extent of cranial or internal lesion, is not essential to the recognition of a petrous fracture. The simple knowledge that the hemorrhage exists, with exclusion of such possibilities of error as have been suggested, should be sufficient to establish the fact that this part has been fractured. The promptitude, freedom, and persistence of a hemorrhage from the ear which succeeds an injury to the head merely confirm the opinion which an otherwise inexplicable effusion has justified, and to this extent are factors in the case.

The subconjunctival, nasal, and buccal hemorrhages are less frequently positively diagnostic. Direct orbital contusions which involve the eye, or epistaxis from superficial injuries of the nose, may be coincident with basic fracture, and the estimate of the clinical value of a hemorrhage in one of these situations may therefore require careful inquiry into the manner in which injury was re-

ceived, and a study of all the attendant symptomatic conditions. If the history shows, and the superficial lesions confirm, a limitation of the field of violence to a cranial region, and there is evidence of intracranial complication, the dependence of an ocular or nasal hemorrhage upon fracture can be properly inferred; while the existence of a contusion of the nose or of an ecchymosis of the face or orbit will render its origin more or less uncertain. There are really few cases in which even this class of hemorrhages cannot be correctly interpreted. The amount of blood lost or extravasated in this instance is of more importance than when the ear is the seat of discharge. An extensive subconjunctival effusion or a profuse flow from the nose at the outset, with perhaps subsequent hæmatemesis, affords a stronger presumption of fracture than trivial loss or discoloration, which might have been caused by trifling injury. After the lapse of twenty-four hours the beginning of a slow oozing from the nose or of a spreading discoloration beneath the subconjunctiva is more significant.

The relative proportion of fractures of the base indicated by the external appearance of osteal or intracranial hemorrhage is greatly increased when comparison is extended to the whole number of cases observed. In 115 cases in which fracture extended from vault to base, comprising recoveries as well as deaths in which necropsy was unattainable, 99, or eighty-six per cent., were attended by external or superficial hemorrhage; when no characteristic hemorrhage was present, diagnosis was made by incision. In the aggregate of this class of fractures, 224 recoveries, and deaths both with and without necropsic examination, 154, or seventy per cent., were associated with a visible

hemorrhage which could be considered diagnostic. It is evident that the escape of blood externally, notwithstanding its obscurity in some instances and its failure of recognition in others, has in itself been sufficient to determine the existence of fractured base in a very large majority of cases included in the appended summary of observations.

There are besides hemorrhage direct symptoms, of occasional or exceptional occurrence, which may be of great diagnostic value. The escape of brain matter from the ear is absolutely pathognomonic, not only of petrous fracture but of cerebral laceration. In one of two cases in the appended series, No. CCLIV., it followed profuse hemorrhage and was delayed till the second day; it was an intermittent oozing for twenty-four hours, amounting to one drachm or more; it was not followed by serious effects of brain injury, and the patient recovered. In the second case it was accompanied by profuse hemorrhage from the nose and mouth, but by none from the ear; the patient died in a few hours and escaped necropsic examination. It is more frequently observed in fractures of the vault, and very rarely through the nose.

Serous discharges from the ear are also infrequent. In the entire series of two hundred and eighty-six cases of deaths and recoveries, there are altogether thirteen instances, but in three it was undoubtedly a declining phase of hemorrhage which in each had continued for a week, gradually lessening and becoming serous before its cessation; and in a fourth, an intermittent sero-sanguinolent discharge, which appeared on the eighth or ninth day, was clearly aural and inflammatory. In the nine in which it was an actual symptom, it was primary and independent in two only, Nos. LXXIII., CCXXX., and in one of these

was followed by recovery. In the recovering case it began suddenly and very profusely a short time after the patient's fall from a considerable height, and continued for several days; the development of symptoms of intracranial complication was followed by a late mastoid inflammation, which was relieved by a trephination otherwise barren of result. The second case, in which the discharge was also profuse, proved fatal from pulmonary œdema in a few hours; the petrous portion was fissured and the brain extensively lacerated subcortically, with only slight arachnoid hemorrhage in the frontal region. The discharge in both instances was probably cerebro-spinal, in view of its profusion and almost immediate occurrence. In the seven cases remaining, the serous fluid, which was abundant and usually clear, was preceded in each by a free hemorrhage lasting from a few hours to the fourth day; three were followed by recovery and four by death and necropsy. In two of the necropsic cases, death was caused by purulent meningitis and there had been no intracranial hemorrhage; in one there was a large arachnoid serous effusion at the base, and in the other a moderate arachnoid effusion with excessive œdema of the brain substance; in one the posterior surface of the petrous portion was comminuted and in the other a fissure traversed its central portion. In the other two necropsic cases, petrous fracture was accompanied by large and firm epidural and arachnoid clots in a contiguous basic fossa, and in one of them by thrombosis of the superior longitudinal, lateral, and petrosal sinuses and internal jugular vein, with a localized œdema in the posterior cerebral region confined to the meshes of the pia mater. The three recovering cases in which serous discharge followed hemorrhage were not of identical charac-

ter; in one it was coincident with an extrusion of brain matter on the second day and continued twenty-four hours; in the other two it occurred on the second and fourth days and was of brief duration.

All the sources to which these watery fluxes have been ascribed seem to have been exemplified in these few cases. In three it was demonstrably the final phase of hemorrhage, and in one the outcome of aural inflammation; in two it was no less positively the cerebro-spinal fluid, and in two an inflammatory arachnoid effusion; in one at least certainly, and in others presumably, it was the result of the coagulation of blood following an intracranial hemorrhage. In this way it often happens that exclusive theories are disproved by the results of sufficiently extended observation.

The diagnostic value of watery discharge is very limited; if it is primary and profuse, it is pathognomonic; if, as these observations seem to show, it usually follows a hemorrhage, when it occurs at all, it adds nothing to the already assured certainty of fracture.

Another and still more infrequent symptom of basic fracture is an œdema of the mastoid region. In the single instance noted, No. LXII., it accompanied fracture of the posterior fossa which traversed the groove for the lateral sinus, with obstruction of that vessel by a thrombus. The occurrence of such a symptom must necessitate the joint condition of a venous obstruction to cause the œdema and of a fracture to permit its appearance in a cranial region. It could hardly be apparent at any point where the superficial tissues are thicker than those which so thinly cover this bony prominence. In one of the instances cited of secondary serous discharge from the ear, it is possible that

the same conjunction of thrombosis and fracture may have contributed to the result.

The implication of a cranial nerve may discover the existence of a fracture, even if otherwise unsuspected. It must be practicable, however, fairly to determine that functional disturbance or abeyance does not depend upon intracranial lesion before it can be attributed to structural injury of the nerve while within its bony conduit or foramen. It is possible that any cranial nerve may be crushed or compressed in this manner, though, with the exception of the second and seventh pairs, it is in the highest degree improbable. In the appended series of cases, there are numerous instances in which each in turn has suffered functional loss or disturbance from intracranial lesion, but it is only in case of the second and seventh that similar conditions have been demonstrably due to implication of the nerve in the line of fracture. The frequency with which this complication occurs is probably overestimated. Facial paralysis in connection with head injuries is of constant occurrence, and fractures of the petrous portion involving the part through which the nerve passes constitute a large proportion of all those extending into the base; yet a cranial rather than an intracranial origin of this condition is rarely suspected, and is still more rarely disclosed on necropsic examination. There is in general neither osseous displacement nor retention of coagula to lacerate or compress the nerves, and only one or two examples can be found in the whole of the appended series.

The lesion of the optic nerve at the optic foramen by compression from the osseous fragments is less exceptional than the injury to the facial, and is more readily discoverable, not only after death but during life. Callan published

nine cases and has since increased the number of his observations to seventeen. The appended series of cases includes six, of which four were recognized only upon necropsy, and of these three had died without the recovery of consciousness and the fourth had suffered no loss of vision. In one only was the nerve implicated in the fracture. In the two cases in which life was preserved, the patient upon the restoration of intelligent consciousness discovered loss of vision. Ophthalmosopic examination made on the third day in the first was negative, though the pupil did not respond to direct exposure to light; fifteen days later atrophy of the optic nerve had begun. In the second case the ophthalmoscopic examination was not made till the fourth week; the pupil was then insensitive to light and atrophy of the nerve was in progress. Entire loss of vision was permanent in both cases. These six probably represent nearly if not quite the whole number of cranial injuries to the optic nerve in the series of two hundred and forty-five basic fractures.

The necropsic examinations, when the anterior fossæ were involved, were made with a view to the detection of this complication, and if the patient recovered it certainly could not have escaped observation; if there were others, they must have been confined to the very few instances in which death occurred without previous restoration to consciousness, and in which opportunity was not afforded for post-mortem examination. The injuries to the nerve are much fewer even than the implications of the optic foramen in the line of fracture.

Callan gives this description of the lesion and its manifestations: "It is due to a fracture of the sphenoid bone which compresses the optic nerve as it passes through the

optic foramen, and is more likely to happen if the blow is received upon the frontal bone, but may result from a fissure which extends from another cranial region. Monocular blindness is immediate and generally with total loss of all light perception. The eyeball protrudes and diverges, and the pupil is enlarged and non-responsive to light. Optic-nerve atrophy begins within two weeks."

The two cases cited conform to this description, except that hemorrhage chanced to be insufficient to cause ocular protrusion or divergence. In only one of the necropsic cases did the fracture involve the sphenoid body.

The cases in which sight is destroyed by direct wound of the orbit, as from pistol shot or by profuse hemorrhage into the orbit or globus oculi in fracture propagated from the vault, are of less diagnostic interest, because the condition is obvious and readily apprehended.

There is still another and perhaps final direct symptom of basic fracture which may suggest its existence and location in the absence of more positive indications. It is an acute localized pain, different from the frontal, occipital, or diffused headache which is common in all forms of intracranial lesion. Its limitation and intensity serve to distinguish it from the pain of internal injuries, while it is disproportionate to the amount of superficial contusion. In fracture limited to the posterior fossa, in which other direct symptoms are often wanting, it may afford the only ground for suspicion, and when it involves the mastoid process its import may be confirmed by the later appearance of subcutaneous hemorrhage. It has been often noted in the cases appended, and its significance often established in subsequent post-mortem examination. This symptom, which has been generally if not en-

tirely overlooked, is sufficiently important to deserve attention.

The evidences of intracranial complication which have been so often regarded as symptoms of basic fracture are indirectly diagnostic of that lesion, but only in so far as they explain or confirm its direct indications; they are of themselves insufficient, since all of the intracranial lesions may exist independently, just as fracture may occur without complication. The cranial and the intracranial lesions, however, concur in a large majority of cases, and while the direct symptoms are usually adequate to a diagnosis of the fracture, there are still cases in which an element of doubt remains, to be resolved, possibly, by the recognition of an internal injury. A profuse hemorrhage or serous discharge from the ear, with certain restrictions as to the conditions under which it occurs, or the extrusion of brain tissue, may render the existence of a petrous fracture certain; but a nasal hemorrhage or a localized pain, however characteristic, can hardly determine an ethmoid or sphenoid or a mastoid fracture with equal certainty, and confirmation is naturally sought in the fact of intracranial complication. The possible error in the use of this means of diagnosis has been in ascribing to it undue importance, and in a consequent depreciation of the value of direct symptoms. Some minor degree of cerebral contusion may exist in any case in which violence has been sufficient to produce fracture, but, if so, its indications are so often slight and transitory, and early histories are so often imperfect, that this assumption is impossible of verification. The presence therefore of even trivial intracranial injury cannot be regarded as essential and much less as of primary importance in the diagnosis of fracture, which really

occurs much oftener without complication than without the evidence of direct symptoms.

Fractures of the base were for a long time regarded as shrouded in mystery, and, like the intracranial traumata, as problems to be satisfactorily solved only by necropsic examination. The means afforded for their diagnosis are certainly not unusually restricted; the possibility of tracing the fissure from its origin in the vault, the evidence of external hemorrhages, serous discharges, or extrusions of brain tissue, the localization of pain, and the concurrence of complicating intracranial lesions, suffice in by far the larger number of cases to remove them from the domain of obscurity and conjecture.

Prognosis.

The prognosis of cranial fracture demands some consideration. It concerns repair, the loss of function, and by a possibility the danger to life.

The restoration of the bone in simple linear fracture is effected by a definitive callus and is perfect; even a trace of its existence is eventually discoverable in only the most exceptional instances. At the base, in which fracture is almost invariably of this form when propagated from the vault, and in which frequency of occurrence and of recovery would presuppose frequency of disclosure in the dead-house if evidence of closed fissures remained, it is practically unknown as an ancient lesion. A cranium discovered and lost in the morgue of Bellevue Hospital many years ago, by a youth ignorant of its pathological value, exhibited a line of fracture across both middle fossæ with slight displacement of the posterior segment upward, and with

union long perfected. This specimen was perhaps unique. If the fissure is widely opened and the patient survives the complications with which it is likely to be attended, it will be approximately closed by the elasticity of the skull before repair begins. In any event the process is slow and may extend over many months. An exception to the almost invariable closure of an open fissure occurs in one of the appended cases, in which, with a fracture through the median line of the frontal bone extending into an orbital plate, perceptible separation and mobility of the segments existed five years after a comminution of the vertex. The very unusual instances cited, the displacement of segments of the base and the lack of union in fissure of the vault, are merely curiosities of surgical experience. The established rule as to the absence of displacement and the perfection of union in this class and variety of cranial fractures is unaffected. Fracture of the orbital processes of the frontal bone occur under special conditions, and displacement of fragments which sometimes directly lacerate the frontal lobes are not uncommon; they are consequently allied to fractures of the vault rather than of the base. The only dangers directly attributable to linear fracture are essentially confined to the orbital region, and are the laceration of the brain by elevation of an orbital fragment and implication of the optic nerve in its foramen of exit. Displacement elsewhere in the base or in the vault without comminution is practically impossible; implication of other cranial nerves is very exceptional, and no subsequent harm can come from the simple process of repair. Depressed or displaced, and comminuted, fractures are limited to the and orbit, regions in which the bone is comparatively and are often prolonged by simple fissures. If the

bone is composed of two tables, depression may be confined to either, and if the inner be the one depressed, the outer is usually but not invariably fissured; and if both are depressed, the inner is likely to be the more extensively involved and often comminuted. These simple facts are of common acceptance. If the displaced fragments can be restored to their normal position without loss of substance, the lines of fracture only remain and will unite as readily and with as little incidental danger as primitive fissures. If loss of substance results from the displacement and necessary removal of fragments, the unaided osteogenic properties of the pericranium, diploe, and dura are insufficient to replace the portion which is lost. The dense fibrous structures which then occupy the osseous hiatus imperfectly protect the cranial contents from external violence, and this structural weakness is a source of danger proportionate to the extent and situation of the enfeebled part. The detached fragments, when completely separated and depressed, may become the source of additional dangers; they may be encapsulated in the dura and by irritative pressure lead to remote neuro-psychic disturbances, or they may be necrosed and occasion dural or peripheral abscess.

The complications of depressed fracture are twofold: there are concomitant intracranial lesions, as general meningeal or cerebral contusions or distant lacerations produced simultaneously by the same violence which causes the fracture, and common to all its varieties; and there are superadded the localized wounds inflicted by the dislocated fragments. The coincident injuries have no part in the prognosis of fracture: the consecutive lesions constitute whatever elements of danger it possesses. Hence a

seeming paradox. The fissured fracture of the base is often followed by a fatal result, while the depressed and comminuted fractures of the vault generally end in recovery. The harmless fissure of the base is likely to be associated with grave concomitant lesions, and being in bad company is held responsible for the fatalities to which these complications directly lead; the more dangerous fractures characteristic of the vertex are oftener complicated only by the direct and accessible injuries of their own production. The coincident lesions are in a majority of instances beyond remedy, though not equally beyond recovery; the consecutive injuries are in larger proportion amenable to treatment. In a minority of cases a wound of a dural sinus or of the middle meningeal artery may be irremediable, or a cerebral laceration made by an orbital fragment may be inacccessible, and it is possible that structural disorganization from crushing violence may be irreparable; but ordinarily the hemorrhages and lacerations at the site of fracture are manageable and infection is preventible if surgical interference is sufficiently early and complete.

It is therefore true that in themselves cranial fractures are important only in exceptional cases. Their prognosis is really the prognosis of their complications. Neither the shock of an uncomplicated fracture nor the hemorrhage from the osteal vessels is ever fatal. Its methods of repair involve no subsequent dangers, and if it occasions loss of substance which necessarily fails of osteogenetic restoration it can only increase a bare chance of remote disaster from some future exposure to violence. The fatalities which follow in its train are in the vast majority of cases due to concomitant lesions with which it has only

an accidental and innocent connection. The consecutive complications for which alone it is responsible are usually amenable to control, and there remains only a residuum of scattered cases beyond the pale of relief to justify its evil reputation.

The tabulation of cases of fractured base or vault, with reference to the percentage of recoveries or its relation to the region involved, is useless, except it be to determine the probability of a fatal complication, or its more frequent occurrence in different parts. The fracture is rarely more than an incident. The generalization supposed to be justified by the discovery that in a certain number of cases of fractured base recovery followed in all in which injury was survived for twenty-four hours, is a familiar illustration of the idleness of purely arithmetical conclusions. It is well known that the issue of coincident intracranial lesions is not usually determined in that length of time. An analysis of the results and conditions of fractures included in the appended series of cases will show a fatality in nearly two-thirds of those which involved the base and about one-third of those which were confined to the vault, but in the total of three hundred and fifty there are less than a score in which the fracture was the determining cause of death.

Treatment.

The treatment of cranial fracture is essentially local. If the osseous lesion is devoid of intracranial complication, there will be no general indications to meet, and if complicated, the general treatment will not be modified by the coexistence of fracture. The initiative of treatment in the presence of grave complication will be constitutional.

Shock is the most urgent primary condition, and until reaction has been established, no local interference is permissible except it be for the control of hemorrhage by the simplest possible means. If the hemorrhage is serious it may be proper to go farther, even to the extent of invading the cranial cavity, since in emergencies even laws are held in abeyance—but always with discretion. The general principle that the resort to local measures must await the restoration of nervous and vascular force, except for the relief of hemorrhage by which depression is prolonged, is a fundamental law in surgery. The neglect of this precept is one of the most frequent errors of inexperienced practitioners and hospital assistants, and seems especially to prevail in the case of injuries of the head; that life is often thus jeopardized or sacrificed at the outset is manifest not only from observation but in the published histories of cases. In the absence of shock or after reaction has been secured, the injury should receive immediate attention. If operative measures prove to be required, early conditions are more favorable than those presented after pathic changes have begun. The principles of surgical procedure are precisely the same as with complicated fractures of the extremities: the establishment of reaction and then, if interference be demanded, a resort to primary rather than to secondary operation.

Fractures of the base rarely admit of direct interference, even for exploration. They are usually inaccessible, and of the linear type which neither involves danger nor requires rectification; it is only incidentally in an examination of a fracture of the vault from which it takes its origin that a basic fissure may be justifiably exposed for inspection.

If a petrous fracture has been made compound by its implication of the internal auditory passage and a rupture of the tympanum, though the danger of infection may be slight, it should be repelled by careful aseptic protection of the external meatus. A similar external communication of an ethmoid or a sphenoid fracture through the nasal cavities is anatomically less favorably situated for the exercise of aseptic precautions. Fractures of the orbit or of the ethmoid bone, the result of immediate violence, are allied to fractures of the vault not only in character and prognosis but in treatment; and the replacement or removal of osseous fragments and the observance of aseptic care in the management of the osseous wound may become practicable and, if so, are no less imperative.

The requirements of treatment in the case of fracture of the vault are more positive. There are simple uncomplicated fissures which are often undiscovered and always unimportant, and which are better left without interference; but complicated fissures and comminuted, depressed, and punctured fractures, even without apparent complication, demand complete exploration, operative reduction to their simplest possible form, and rigid aseptic methods in the immediate and subsequent treatment of the wound. These conditions are absolute, and the particular measures which they necessitate are immaterial, but should be as simple as is compatible with the attainment of the ends in view. It is useless to discuss the propriety of one method of procedure, or the safety of another; it is the necessity of either to the fulfilment of essential indications which must be brought in question. Everything is proper which is indispensable, and anything is safe which can be possibly required for the better comprehension and treatment

of this very simple form of injury. If therefore the existence of a hidden fracture of the vault can be ascertained by palpation, incision should be practised in order to determine its extent and characters; even a doubt in the presence of intracranial complication should be resolved by making direct inspection possible. If the cranial surface is precluded from digital examination by a large or well-defined hæmatoma, incision should still be made, though as yet there may be no indicaton of internal injury. So far diagnosis and treatment coincide. This method is justified not only by the necessity of exploration for the intelligent determination of treatment, but both by theoretical considerations of safety and by the results of experience. It has no conceivable dangers; the matter of infection is within the control of the surgeon, and the amount of additional shock or hemorrhage involved in an explorative incision is inappreciable. This course has been generally pursued in the conduct of cases in the series appended, and the issue has confirmed the opinion expressed as to its propriety. The absence of shock, a fair constitutional condition, and the observance of ordinary precautions; the maintenance of asepsis, the careful repression of hemorrhage, and the restriction of the wound to the limits required for its purpose, are always to be assumed.

If the incision reveals no fracture, or a fine fissure which is deemed unimportant, the wound can be closed and the patient will be none the worse for the means taken to ascertain the nature and extent of his local injury; but if a more pretentious fissure or some other form of fracture is disclosed, exploration and treatment, still conjoined, must be farther extended. The depressed fracture may

be said to include all the others, since it is the possibility of concealed depression which gives importance to cranial comminution or puncture, and removes the first from the class of mere multiple fissure, or the second from the condition of a wound left by trephination. It is the continued uncertainty as to the amount of injury done to the internal table which compels further exploration, even at the cost of operation when the external depression may seem unimportant. The extensive and entirely disproportionate comminution of the internal table and the frequent serious laceration of the brain by its dislocated fragments, with simple fissure or trivial external depression, have been made notorious by reiteration and illustration in every surgical text-book. These conditions often are suggested by no primary general symptoms of complication, and, if unsought, must remain undiscovered at the peril of the patient. The unfortunate results of such neglected fractures have forced themselves upon the attention of every surgeon; immediate septic infection or remoter effects of cerebral irritation or pressure from completely severed or partially detached osseous fragments resting upon or penetrating the brain, including dural or cortical abscess, cerebral necrosis, epileptiform convulsions, and multiform disturbances of functional control, have not yet ceased to be of common occurrence, though with improvement of practice they have notably diminished in frequency. Forty years ago, Dr. James R. Wood, who was often in advance of his time, was the only surgeon of eminence who taught the necessity of elevating depressed bone under all circumstances when not specifically contraindicated. Since then Roberts, Nancrede, and other still more recent writers have advocated it as a general rule of treatment. The in-

junction to refrain from interference with depressed fractures in the absence of complicating symptoms, however, is still widely upheld and respected in the profession, for no better apparent reason than the fact that many patients who are treated upon the expectant plan at least temporarily recover, notwithstanding the recognized dangers to which they are exposed. The influence of tradition and a failure to apprehend the changed conditions of modern surgery often content the general practitioner with the gambler's chance, and the patient takes all the risk.

There may be a slightly wider latitude of opinion allowable when the bone is not obviously depressed, but the probabilities of depression when the vault is comminuted or traversed by an open fissure, or when the fracture is of the punctured variety, are sufficient to warrant a positive solution of the question when it arises. A comminution indicates great violence, limited or diffused, or else structural weakness of the bone, and in either case makes probable greater injury of its deeper part than is apparent upon the surface. A punctured fracture almost invariably involves concealed injury of which the external lesion affords no means of estimate. The exposure of the inner table in both varieties is essential to safety, and should be made, almost without exception, when the general condition of the patient permits. There are sometimes numerous fine fissures, perhaps radiating from a point of impact, without mobility of the intervening parts, and the case is then to be regarded as one of multiple fissure rather than of comminution. The proper course to pursue in the case of a fissure may in some instances seem difficult to decide; it is plain enough when the fissure is insignificant, apparently limited to the outer table, and has been made com-

pound only by incision, or, conversely, when it is wide and deep, and exposed by primary injury. The only rule which can be formulated is that hesitation is always to be ended by sufficient exploration to resolve whatever doubt exists. If the fissure is originally compound, its danger is enhanced by the possibility that infection has already occurred, since it is well known that even closed fissures may have been open in their inception. The concurrence of symptoms of intracranial injury gives additional force to the direct indications for deep exploration, by increasing the probability that the hurt has been sufficiently severe to comminute the inner table.

The exploration and rectification of a fracture, of whatever character, can ordinarily be effected by very simple operative measures, and by the use of correspondingly simple instruments. Depressed bone in a large proportion of cases can be raised by the periosteal elevator, the cranial opening can be sufficiently enlarged by the rongeur, osseous fragments can be removed by any kind of forceps, and intracranial exploration made by the ordinary probe. If the elevator cannot be inserted, a sufficient opening can often be obtained with the burr drill. The use of the trephine is only occasionally required. Comminuted fractures may be exposed and fragments removed with equal facility and by the aid of the same instruments. Even punctured wounds of the cranium may sometimes be enlarged by the rongeur. There is no objection to the resort to the trephine in any case in which it better or more conveniently serves the purposes of the operation. The chisel is best adapted to the examination of fissures and can be supplemented by the trephine if reason is found to suspect internal comminution. The

details of procedure are exemplified in text-books of general surgery.

Trephination has been voluminously discussed, and large tabulations have been made of cases in which it has been a feature in treatment. Whatever of propriety or necessity may have existed heretofore for the marked attention which has been accorded this simple operative procedure, or whatever question may still exist as to its employment in the treatment of intracranial lesions, there can be no longer reason to give it special prominence or to individualize it among the other expedients utilized in the management of fractures. It is simply an incident in treatment, to be used or avoided as the exigencies of a case may suggest, not dangerous in itself, and no more responsible for the outcome than the choice of a knife for making the incision or of a forceps for the extraction of an osseous fragment. The statistical tables which have determined the rate of mortality in cases in which trephination has been employed have also shown the infrequency with which the operation has contributed to the fatal results recorded. It is the complication which kills, not the fracture, nor the means of treatment which the fracture requires. The percentage of deaths for which it is held responsible, three per cent. (Amidon), is, in view of the fallibility of human judgment and the natural errors of inexperience, rather remarkable. It seems probable in the exceptional cases in which operation, whether trephination or some other procedure, and not the lesion, is justly chargeable with the death which follows, that the timidity or recklessness of the operator is likely to be in fault—a timidity which allows the case to drift till the development of symptoms compels interference under unfavorable cir-

cumstances, or a recklessness which impels to operation regardless of the constitutional condition of the patient. There is no apparent reason why trephination should involve peculiar dangers; it is not an operation in which shock need be excessive, nor in which a general anæsthetic even need be employed if deemed unadvisable, or in which the danger of infection, whether from exposure of the diploe or of the cranial cavity need be greater than in the making of the external incision, if it need exist at all. The consideration of treatment in general has been advanced to a higher plane than it formerly occupied, and the proper fulfilment of indications has become of greater recognized importance than the selection of means for their accomplishment. It suffices if these are as simple as may be and devoid of unnecessary danger. Greater discrimination is also exercised in estimating the results of necessarily fatal injuries, and the effects of possibly unsuccessful measures taken for their relief. It is now recognized that trephination is in itself neither a formidable procedure nor necessarily of radical importance, and it has therefore come to be regarded as a less prominent

of a depressed fragment of bone and relief of "compression," the patient in the twinkling of an eye springs from profound coma into consciousness and mental activity, seem to be extinct. Instances still occur in which by the opening of the cranial cavity and incidental elevation of encroaching bone for the relief of intracranial hemorrhage and removal of coagula, cerebral function is presently restored; but these operations concern the treatment of consecutive complication.

Chapter I.

PATHOLOGY.

DIRECT LESIONS.

THE traumatic intracranial lesions, whether they occur independently or as complications or sequelæ of cranial fracture, cannot be predicated upon the amount of violence apparently inflicted. Injuries received by falls upon the head from great distances, or from a mere stumble upon the street, may be in either event trivial or disastrous; force in the one case may be so broken in various ways that its final impact is minimized, as in the other it may be fully conserved or even exaggerated by attendant conditions. Their exact history is rarely attainable. The effect of a glancing blow differs from that of one which is direct, and the comparative elasticity, thickness, or density of the skull will modify the extent and character of intracranial injuries as well as of fracture. The study therefore of different forms of violence, in the necessary absence of essential data, is of no practical utility.

The intracranial traumatic lesions may be classified primarily as:

Hemorrhages.

Thromboses of sinuses.

Contusions.

Lacerations.

And their sequelæ as:

Meningeal and parenchymatous inflammations, which are usually, if not invariably, of a septic character: and

Atrophy.

The primary conditions may occur as isolated lesions or in combination with each other, and the later inflammations which may also coexist develop at any period during the persistence of the direct structural changes upon which they in part depend.

The hemorrhages may be epidural, pial, cortical, or parenchymatous, and the contusions and lacerations may either be confined to the brain or meninges or may involve both structures with a predominance in one.

As previously stated, when the intracranial lesions occur as complications of fracture they may be coincident or consecutive, and usually dominate the symptomatology, afford the indications for treatment, and determine the prognosis of the case.

1. Hemorrhages.

Some confusion has arisen in the nomenclature of hemorrhages as it relates to their nature and location. The use of the term "epidural" is anatomically correct, and as the sources of this hemorrhage are various it would be doubtless difficult or impossible to suggest another which would at the same time denote its origin. The terms "subdural" and "arachnoid" are indefinite as to location, and imply nothing as to source, and are therefore objectionable. These deeper hemorrhages are derived from the vessels of the pia mater and from or through the cerebral cortex, and are always originally situated beneath the visceral arachnoid membrane, though if the extravasation is sufficiently large it will secondarily break through into the arachnoid cavity. This extension has no clinical or

other importance, but to specialize them as subarachnoid rather than as subdural would somewhat more closely define their anatomical position. The designations "pial" and "cortical," as the subarachnoid hemorrhage is of meningeal or visceral origin, are topographically exact and pathologically distinctive. If the prefix epidural is invariably used to characterize a hemorrhage which separates the dura from the cranial wall, "pial," to characterize a hemorrhage into that membrane from rupture of its vessels, and "cortical" to characterize a hemorrhage upon the surface of the brain from laceration of its substance, both the source and location of the hemorrhage will be expressed in a single word with accuracy and conciseness, and the description of cases much shortened and facilitated.

a. **Epidural hemorrhage**, when derived from the diploic vessels, is usually inconsiderable in amount, and may appear externally beneath the pericranium and in the situations noted in connection with basic fractures. If it escape from the cranial cavity, its importance in this form is mainly diagnostic, and if retained, is insufficient to occasion symptoms; but in exceptional instances of compound fracture of the vertex the loss of blood from this source has been excessive. The implication of the dural vessels increases the extent of hemorrhage in proportion to their size, and in case the arteria meningea media or either of its primary branches is involved the danger to life becomes imminent. The effusion from these large meningeal vessels is usually rapid, with early coagulation, and may be as much as six or eight fluid ounces in volume. The lateral aspect of the corresponding cerebrum is sometimes converted by compression into an oblique plane, and

with the dura may remain for a time after the removal of the clot widely separated from the bone, both laterally and at the base. In one of the appended recovering cases the clot from a smaller meningeal branch in the squamous region measured four fluid ounces, and was one and a half inches in thickness in its central portion. The laceration may be occasioned by a wound inflicted by a fragment of the inner table, by rupture in the line of fracture, or by *contrecoup*, and may even occur without cranial lesion. These different forms of injury are all exemplified in the two hundred and twenty-five necropsic cases included in the appended series. The dural sinuses are a further source of large hemorrhages, possibly from direct rupture of their walls but more generally from wound by an osseous fragment. The accumulation of coagula is less than in the meningeal variety, since the fragment which causes the injury so often closes it till disturbed by manipulation. The profuse discharge of dark-colored fluid blood which at once follows the elevation or removal of a portion of bone from the vicinity of a sinus readily indicates the nature of the lesion. The greater longitudinal sinus is the one usually involved and is not infrequently lacerated in fractures of the vertex. The lateral sinus is occasionally wounded, but from its situation is somewhat more subject to rupture from transmitted force. The hemorrhage is less manageable than that from the longitudinal sinus and is a far more serious accident. The wounding or rupture of the other sinuses must be of exceeding rarity except as it occurs in connection with crushing or disorganizing injuries in which all the adjacent structures are concerned.

The several species of epidural hemorrhage may be

variously commingled, but it is likely to be essentially of one distinguishable and predominating character.

b. **Pial hemorrhage** is occasioned by rupture of the vessels of the pia mater and is primarily confined to its meshes. It is one of the results of intracranial contusion and is independent of epidural extravasation. In its simplest form it consists of punctate extravasations analogous to those which occur in the brain substance. It more characteristically forms a thin sheet over the vertex; if it is in larger quantity it breaks into the arachnoid cavity, or less probably dissects the pia mater from the cerebral surface. It may be universal or it may occur in patches, possibly a single one of not more than one inch in diameter, or perhaps covering the vertex upon one or both hemispheres. The quantity of blood effused is never so great as it may be in epidural hemorrhage, and its clinical importance is mainly due to its association with other lesions. There are still cases in which it is large enough not only to occasion symptoms of general and local pressure but to destroy or endanger life.

c. **Cortical hemorrhage** is the direct result of a wound of the brain substance, which may be superficial, or may be subcortical with an access of blood to the surface by rupture of the intervening tissue. It varies in extent from

These several hemorrhages are all of such common occurrence that their comparative frequency is unimportant. In one hundred and ninety-three necropsic cases appended, exclusive of pistol-shot wounds, there was epidural hemorrhage in fifty-four, pial hemorrhage in sixty-nine, and cortical hemorrhage in fifty-eight. Two or more varieties are often coincident, of which one is likely to outrank the others either in extent or in the possible gravity of its results. The epidural blood never penetrates the dura, and never reaches the subarachnoid spaces except that membrane has been ruptured by the violence of the original injury. The pial and cortical effusions may concur, and may be localized in different regions, or may be commingled, and in either case may be discriminated by tracing each to its source, unless a profuse cortical hemorrhage has overflowed the site of a smaller pial extravasation. If no cerebral laceration can be discovered, it is impossible that a hemorrhage should be of cortical origin.

In a large proportion of cases hemorrhage is a distinct factor in the production of symptoms, and often the sole cause of a fatal termination. It is questionable if it is ever an absolutely isolated lesion. It is oftener secondary to brain laceration, but, when primary, some degree of general or local contusion or an independent laceration may still coexist. The same violence which is sufficient to separate the dura mater from the bone, or to rupture the vessels of the pia mater, can hardly fail further to be transmitted to the brain and its effect ultimately concentrated in a limited lesion at a distant point, or diffused in a general contusion of its substance. A hemorrhage is often regarded as uncomplicated, from want of sufficiently careful necropsic examination of the brain throughout its

whole extent. There may be no laceration or other obvious local lesion, and general contusion is readily overlooked or unappreciated. This almost universal fact of complication renders the direct effects of hemorrhage difficult of segregation, and has probably led to the misapprehension of certain symptoms which often follow in its train.

The dangers which attend intracranial hemorrhage are due to shock, exsanguination of the patient, and diminution of the cranial capacity. If the effusion reaches the medulla oblongata, as occasionally happens, life is terminated by direct compression of the respiratory ganglion; otherwise the effect of encroachment upon the intracranial space is diffused. That the loss of blood may be directly fatal is sometimes made obvious when the hemorrhage complicates fracture. In cases in which a dural sinus has been wounded, death has sometimes so promptly followed the removal of an osseous fragment as to make its immediate cause unmistakable; in other cases in which compound fractures have involved a wound of a larger meningeal artery, fatal collapse has so plainly depended upon cardiac failure as to leave no room for doubt. In the larger class of cases in which the blood extravasated has been retained within the cranial cavity, the hemorrhage though insufficient, even when so profuse as is anatomically possible in that situation, to cause exsanguination, may still render fatal a shock from which recovery had been otherwise not hopeless, or may by producing consecutive asthenia be distinctly contributive to the unfavorable issue of associated lesions.

The greater number of deaths in which hemorrhages seem to have been the direct cause are differently occa-

sioned and less simply interpreted. They have been generally attributed to a mechanical compression which the brain suffers, the result of the intrusion of additional matter into a cavity with unyielding walls which the viscus exactly fills; the consequent disturbance of circulation and nutrition, by more or less complete obliteration of the cerebral capillaries, has been as generally held to be entirely adequate to the explanation of all the characteristic attendant symptoms. In this view the effects of hemorrhage, purulent effusion, and bone depressed have been regarded as identical. It has been experimentally demonstrated that when wax, a substance incapable of absorption, is injected into the cranial cavity in excess of a maximum amount of 6.5 per cent., distinctive symptoms are produced, and that when the amount reaches one-twelfth or one-sixth of the cranial capacity, as its situation is epidural or subdural, fatal coma results. As the effect is purely mechanical, and without the possibility of direct brain lesion, there can be no doubt of its dependence upon pressure or compression. The term compression when applied to a solid organ is permissible, since the reduction of its bulk by extrusion of its fluids is no less real than when accomplished by a change in the density of its solid constituents. That the resultant vascular disturbance leads to deficient nutrition must be conceded. It is equally beyond question that it is preceded by displacement of the cerebro-spinal fluid into the vertebral canal, which continues until the capacity of that diverticulum is exhausted, and that then circulatory interference begins. As the tension of the cerebro-spinal fluid is augmented under pressure of continued extravasation and by increasing resistance in the vertebral canal, capillary flow is checked and may

cease altogether, with complete cerebral anæmia and abolition of all functional control. The intercurrence of œdema from capillary transudation may further increase intracranial pressure. If the hemorrhage is epidural, sudden, and profuse, the anæmic condition will be rapidly attained and complete, and its manifestation will be immediate but not instantaneous, and with permanent inhibition of consciousness; if the same extravasation is more gradual, cerebral anæmia may never become complete, or not until time has been afforded for relief; if it be of moderate amount as well as gradually effused, it may be capable of absorption without the necessity of interference. The pial and cortical hemorrhages are rarely sufficiently copious to produce marked cerebral anæmia, but they are associated with other lesions, which contribute to a fatal result. In all these instances of hemorrhage, the serious interference with vascular supply and the occurrence of answerable inhibitory symptoms are comprehensible.

There are other and smaller infringements upon the intracranial space which have been rated as agents of compression, but which are quite incapable of exercising that amount of general pressure which would cause even partial capillary occlusion. The uncomplicated depression of a fragment of bone, however large, could scarcely diminish the cranial capacity beyond the space gained by practicable displacement of the cerebro-spinal fluid, to an extent which would appreciably disturb the general cerebral nutrition. It might by local pressure cause temporary impairment or abrogation of a function controlled by a centre directly involved, but a compression of the entire cerebrum would be inconceivable. The possibility of an epidural or other abscess being permitted to attain a bulk

sufficient to cause general compression should be scarcely more conceivable in the present epoch of surgical practice. The general symptoms which attend these inconsiderable curtailments of the intracranial space, whatever their nature, must therefore be ascribed to other causes than a general circulatory disturbance occasioned by the contraction of cranial capacity. The almost invariable concurrence of other intracranial lesions with hemorrhage suggests their source.

Pressure and compression are mechanical agencies, and not pathological conditions; the action of one is limited, and of the other diffuse. Hemorrhage causes either pressure or compression, as blood is extravasated in small or large amount; depression of bone or the epidural effusion of pus cause pressure. The symptoms of the compression caused by large arachnoid inflammatory effusions are merged in those of the disease in which they mark the final stage.

The attempt to combine the symptomatic and pathic conditions of hemorrhages of different grades, depression of bone, and inflammation, like other unwarranted generalizations, has led to confusion, obscurity, and much misapprehension.

In cases destined to recovery, the blood extravasated ordinarily disappears by absorption, and such a termination is frequent when the amount is small. It is also observed after hemorrhages of considerable extent, when some portion has been removed by the aid of trephination. If after an interval of months the patient dies, its final traces may be sometimes noted as a mere yellow stain above or below the dura. Cystic degeneration is of occasional occurrence, and is most likely to be a transformation

of an epidural clot complicating depressed fracture. In this way it comes to be encountered from time to time in trephining for traumatic epilepsy. The purulent infection of a clot even in the substance of the brain is not only possible but may exceptionally occur without negligence on the part of the surgeon.

2. Thromboses of Dural Sinuses.

The occurrence of thrombi in the dural and basic sinuses, perhaps extending into the jugular vein, which are neither marasmic nor infective, is occasional and not always susceptible of adequate explanation. This condition may affect any one of these canals and is concurrent with other and varying anatomical lesions. The thrombus may be wholly or partially decolorized, is non-adherent, and is likely to extend from the superior longitudinal sinus or torcular Herophili through the lateral and petrosal sinuses. In one of the appended cases the wall of the posterior part of the superior sinus was infiltrated with blood at a point immediately below a compound fracture, with laceration of the meninges and extensive epidural, pial, and cortical hemorrhages. As the thrombosis began at the site of injury, it was probably the result of the direct lesion of the sinus wall. In another case, as the thrombus extended from the jugular vein into the torcular Herophili and a cranial fissure terminated in the jugular foramen, there is again probability of direct injury. In a third case there was no fracture or intracranial injury other than a general contusion and thrombosis of the minute cerebral vessels, most pronounced at the base and upon the left side. The thrombus, which was decolorized, occupied both lateral and both petrosal sinuses. These

cases, in which the thrombi were all of ante-mortem formation, were pathologically independent of each other, and unconnected with pressure or with any inflammatory process within or without their walls, or with any dyscrasia of the patient. They were non-infective and had no appreciable influence in symptomatology. It is conceivable that by closure of the jugular vein they should occasion external symptoms of venous obstruction, and such have been observed in recovering cases in which it was suspected. Their clinical value is yet to be discovered, but their occurrence must be recognized as one of the several intracranial traumatic lesions.

3. Contusion.

Intracranial contusion may be cerebral or meningeal, and in either structure may be limited or diffuse.

a. General Contusion of the Brain.

This condition probably exists in some degree in all cases of intracranial injury, and may affect the entire organ or be confined to the cerebrum. It is infrequent as an absolutely isolated lesion, of rather more common occurrence as an essential change, and almost constant in connection with a considerable hemorrhage or laceration. It has often escaped observation, partly by reason of its diffused character and its coexistence with more obvious alterations of structure, and partly from the still general acceptance of a theoretical basis of functional disturbance as an adequate explanation of symptoms. The visible anatomical changes are: a distention of the parenchymatous vessels, a general formation of minute thrombi, the presence of punctate extravasations, and a more or less distinct

œdema. The punctate extravasations which are characteristic of limited contusion are rarely seen in this general form of the same lesion, and then perhaps only singly and at widely different points. If the hemorrhages are larger, even of the size of a buck shot, they are the result not of contusion but of laceration. It is not an arbitrary distinction, and the line is drawn at punctate extravasations, not only because it is definite but because it is the probable limit at which the effusion ceases to be purely interstitial and becomes destructive of tissue. The minute thrombi are the most characteristic of the several morbid conditions which have been enumerated, since they are almost if not quite unknown after death from idiopathic disorders in which hyperæmia has been excessive. The œdema, which is variable in amount, sometimes appreciable only after some delay and a close inspection upon section, and at other times so profuse that the fluid can be squeezed from the brain by the hand as from a sponge, is notably frequent. All these abnormal conditions, the extravasations, thrombi, and œdema, are simply measures of the general hyperæmia which immediately preceded death. The primary or intervening transient changes which induced the final vascular fluxion can be inferred only from symptoms and analogy. It is demonstrated by Boise that general shock is a hyperirritation of the entire sympathetic nervous system, occasioned by some sudden and more or less violent impression, and causing contraction of the arterioles by stimulation of the vasomotor nerves. The character of its symptoms indicates the deficient vascular supply. The immediate inhibitory symptoms which attend a violent injury of the head would seem to depend upon a similar irritation of the cerebral centres of vascular control with

contraction of the cerebral vessels; to this succeed by continued irritation paralysis and dilatation. The brain is primarily made anæmic; with the secondary dilatation of its vessels, as hyperæmia becomes excessive, it is again anæmic in effect from more or less complete cessation of capillary movement and from œdema. The result of compression and of general brain contusion is the same, and it is the frequent coexistence of contusion with the pressure of depressed bone which has led to the confusion of pression with compression. If the cortical centres recover from the shock, the circulation is readjusted.

In accepting vascular derangements as the source of symptoms in intracranial contusion, it has been sought by some previous writers to interpose certain physical processes between the application of external violence and the impression made upon the nerve centres. Miles, in an elaborate study of this subject, and as a result of experimental and speculative considerations, accepts Duret's theory of the formation of consecutive areas of cranial depression and bulging, causing temporary compression and forcing the fluid of the lateral ventricles into the fourth ventricle and the spinal subarachnoid space; and from overdistention of the fourth ventricle involving rupture of its floor and lesions of contiguous parts, including the medulla. A stimulation of the restiform bodies is assumed to follow, and a consequent efferent reflex action which directly occasions the capillary contraction. It may be objected to this explanation that it is unnecessarily complex, since, from the analogy of general shock, the direct transmission of the nervous impression from the external surface is equally conceivable; and still further that post-mortem examination of cases in which even ex-

treme contusion is found to exist does not disclose such localized lesions in the neighborhood of the fourth ventricle as were said to result from experimentation. The immediate tetanic effects observed in the experiments upon animals, made both by Miles and by Duret, are also absent in contusion of the human brain, unaccompanied by laceration or hemorrhage.

The invention and application of a fanciful term to comprehend all combinations of symptoms and pathic conditions, when the brain is not supposed to be compressed, has met with great acceptance. All traumatisms involving brain symptoms, were for many years classified as cases of concussion or of compression. The classification was simple and of easy comprehension. If the intracranial space was diminished by the intrusion of bone, serum, extravasated blood, or pus, it was compression; otherwise all symptoms were referred to a hypothetical vibration of the brain within the skull, a merely functional disorder produced by violence. Thirty years ago Prescott Hewitt described several forms of contusion, in which he included lacerations, and questioned the occurrence of concussion as a distinctive pathic condition independent of anatomical change. Previous to this time several observers had noted structural alterations in certain suddenly fatal cases which had presented the symptoms attributed to concussion, but had not recognized the existence of perceptible lesion when life was further prolonged or recovery ensued. Mr. Hewitt, in suggesting that all cases of concussion are attended by some appreciable lesion, made a distinct advance in the study of the pathology of cerebral trauma. He did not, however, distinguish contusion from laceration or hemorrhage in the classification of cases. Though a belief

in a physical basis for all cerebral symptoms occasioned by injuries of the head became more widely extended, von Bergmann some years later in a clinical lecture admitted the existence of both concussion and compression, with an etiological difference, and insisted upon their clinical identity. He attributed concussion to a direct injury from a single impulse, modified by the elasticity of the skull, by which the brain suffered a diffuse disturbance without appreciable lesion. He considered it a suspension of cortical activity, followed by a stimulation and eventually by a depression of the medulla. He regarded it as occurring in three degrees: as involving paralysis of the cortex only, as a paralysis of the cortex and a stimulation of the medulla, and as a paralysis of both cortex and medulla with a primary brief and unobserved medullary stimulation. Cortical paralysis was indicated by unconsciousness; medullary stimulation by slowness of pulse and increase of arterial tension; and medullary paralysis by rapidity of pulse and decreased arterial tension. In compression, he regarded the brain condition as identically the same and as manifested by the same symptoms, but as due to change of cranial capacity and not, as in concussion, to change of cranial form. Finally, he considered diagnosis as only possible by the duration of the symptoms. The views of von Bergmann are of too great weight and authority to be lightly questioned; but since the time at which he wrote, further observation has shown that the diffuse disturbance he terms concussion is connected with evident lesion; and, while the vascular derangements caused by compression of the brain substance may be identical with those due to direct injury, recognition must certainly be given to the presence of the compressing agent within the cra-

nial cavity by which clinical as well as etiological differences are established. Concussion and compression, having been consolidated by von Bergmann, should be abolished together, so far as they are terms used to express a pathic condition.

The impossibility of accepting a functional disorder as adequate explanation of the group of symptoms which has been collectively known as concussion, resides in the fact that in recovering cases it is purely an assumption which is contradicted by the necropsic appearances observed in those which are fatal. Structural alterations have been denied, not only without reason but in despite of positive evidence. In every fatal case, when the clinical history has corresponded to that of those which have recovered, a carefully conducted necropsy has revealed organic lesion. In all the instances which have been cited to prove the absence of lesion, not one has been noted with sufficient exactitude to give it the slightest statistical value. There is nothing in analogy to warrant at the present time the assumption that any fatal disorder terminates without involving structural change. Even disorders of the nervous system, long considered functional, have with closer investigation fallen more and more into line with organic diseases. It may properly be held, both from post-mortem observation and from analogy, that brain injury produces structural alteration with the same certainty that it occasions palpable symptoms. If the words concussion and compression be used to indicate a group of symptoms or variations of pathic condition, it is objectionable, both on the score of propriety and of exactitude and as being likely to lead to erroneous diagnosis. If they be discarded, the form of injury the patient has suffered, as

laceration, general contusion, or fracture with hemorrhage, is more likely to be accurately determined than if attention be directed solely to a symptomatic condition that may not clearly exist.

If the cortical centres recover from the shock to which they have been subjected, the circulation is readjusted, the punctate extravasations and serous transudations are reabsorbed, and it is probable no physical vestige of structural alteration remains. There is a subsequent instability of cerebral nutrition, which has been recognized as a sequel of intracranial injury, and, as it also occurs after all lesions in which contusion is a complication, it is probably due to an increased susceptibility of the vasomotor centres, and a consequent liability from trivial cause to the occurrence of transient conditions of either anæmia or hyperæmia. Such persons are often unable to endure serious mental or physical labor, exposure to the sun, moderate alcoholic stimulation, or many other of the fatigues and pleasures incident to ordinary life. This fact was officially recognized in the later part of the war of secession, and men who had recovered from a head injury of any kind were relegated to the invalid corps.

b. Limited Contusion of the Brain.

This lesion may be confined to the cortex, or may exist subcortically in any region of the organ. It may be said to differ from laceration, as a contusion elsewhere differs from a wound. It is a bruising of the tissue with minute hemorrhages and possible molecular disintegration, and in both particulars is distinguishable from general contusion. The hemorrhages are characteristically in punctate form and are thickly scattered among the cells and

capillary vessels. As it occurs upon the surface in a single area, or perhaps in two or more different regions, it may occcupy a space from a fraction of an inch to one or two inches in diameter, and is a simple bruise. It is slightly depressed and variously discolored from dark red to yellowish-gray, and without arachnoid laceration. In the subcortical substance it appears in similar areas as an aggregate of punctate extravasations with or without a yellowish or darker stain of the intervening tissue. In general contusion it may happen that the change is limited to a single hemisphere or to a single lobe, but is still comparatively large, and, as its anatomical peculiarities are different, it is to be regarded rather as a regional form of the general lesion than as a limited contusion.

This is the most infrequent form of intracranial injury, and without complication is almost exceptional. It indicates the direct transmission of a certain degree of force, in place of its entire diffusion; that it stops short of laceration is because force is possibly minimized, in some instances and in some measure, from the amount of resistance which it encounters.

If the lesion is superficial, whether it be a laceration or a mere contusion, it is oftener than elsewhere at the base of the brain, and in the anterior or middle fossa. In itself it is unimportant except as it is contributory to the effects of the general injury, and has no distinctive indications. Its relation to subsequent infective changes will demand later consideration.

c. Contusion of the Meninges.

Meningeal contusion has not been heretofore appreciated or described as one of the distinctive lesions in intracranial injury. It may be more or less prominent than the cerebral contusion which it accompanies, and while it may be the paramount apparent lesion it is probably no more entirely independent of general cerebral contusion than is a laceration or a hemorrhage. It is incredible that force should be so strictly localized as utterly to expend itself in a structure so thin and delicate as the pia mater, to which meningeal contusion is apparently restricted. Its relation in extent and severity to general cerebral contusion is not clearly defined, but they are not always directly proportionate, and either one may be relatively excessive. It may be largely or universally diffused, or may be limited to areas not larger than the localized injuries of the cortex. It is legitimate inference that the evident vascular derangements are produced, as they are in the brain substance, by the shock impressed upon the vasomotor centres. The same conditions, hyperæmia, œdema, and hemorrhages, are apparent. The punctate extravasations are more numerous and more frequently observed, and moderately profuse hemorrhages, which are unknown in the diffused cerebral lesion, are of common occurrence in patches, in thin sheets spread over the vertex, or in quantity sufficient to break into and fill the arachnoid cavity. The difference in the amount of extravasation which follows engorgement of the vessels depends upon the anatomical peculiarities of the pial membrane. The vessels are comparatively large, with feeble support from the loose areolar tissue which they

traverse, while in the brain substance the circulation is maintained through capillaries and arteries of the smallest size, which are greatly strengthened by the denser structure in which they lie. Even in the largest pial hemorrhages it is unnecessary to suppose that there has been rupture of the membrane from direct transmission of force. The vessels give way from the lateral pressure of overdistention, and, if the areolæ are torn, it results secondarily, from the profuseness of the hemorrhagic effusion. Limited hemorrhages which have infiltrated the pia may be demonstrably without laceration of its areolar structure.

Hemorrhage is the usual indication of this meningeal form of contusion, and was observed in sixty-eight of the appended series of necropsies. Its greatest relative frequency was in intracranial injuries without fracture, and its least was in connection with fractures of the vertex. This estimate is independent of simple hyperæmias and punctate extravasations. The termination of these cases is not unlike that of other intracranial hemorrhages in the circumstances of recovery or death.

In place of a hemorrhage, a subarachnoid serous effusion is sometimes encountered, as a result of the hyperæmia which follows meningeal contusion. It is not of frequent occurrence and is readily mistaken for an inflammatory process. It may be recognized as a perfectly clear fluid, confined to limited areas, and unaccompanied by arachnoid opacity. It may cover a single lobe, or a space not more than one or two inches in diameter, and like other evidences of contusion these transudations may be single or multiple. Several instances in which the œdematous may be discriminated from the inflammatory effusion are

to be found in the appended series of necropsic observations. It is not to be expected that it can be detected during life, since even when considerable in amount it is still insufficient to occasion symptoms of compression.

There is a sequel of meningeal contusion in an inflammatory process similar to that of the limited visceral lesion, which will be included in the study of secondary traumatic inflammations.

4. Laceration of the Brain.

Laceration of the brain is the final expression of limited force in its greatest intensity. It may be cortical or subcortical, single or multiple, trivial or important. If less absolutely constant than general contusion, it is even more frequently encountered as an emphasized lesion. In the whole number of necropsies upon which these propositions are based, it occurred in one hundred and twenty-eight, and in ninety-four was evidently the source of symptoms or the cause of death. It is not always possible to determine the extent of the original wound, since so many and so considerable vessels are likely to be ruptured, and the consequent hemorrhage to be so profuse that the brain substance may be broken down to a great distance and in every direction. It is not unusual for an entire lobe to be excavated and disintegrated, or even the greater part of a hemisphere to be similarly destroyed. These enormous subcortical lacerations may break through the cortex, and the extravasated blood spread over the whole surface of the brain; or they may remain strictly confined to the parenchyma in which they originated, enclosed only in a mere shell of the cortical substance. In other cases they are scarcely larger or more important than the most incon-

siderable limited contusion, from which they are distinguishable only by the relatively greater amount of hemorrhage which they involve. Between these extremes they present every gradation of destructive injury. Like fractures and limited contusions, they are oftenest discovered in the basic region, and in the majority of instances affect the frontal and temporal lobes. There is no portion of the brain, however, which may not be wounded; neither the interior of the cerebellum, pons, medulla, optic thalamus, or corpus striatum, nor the fornix or gyrus fornicatus; no ganglion or convolution is exempt from this result of violence. In the cases examined, exclusive of the fractures of the vertex in which lesion was produced by the direct application of force, some part had been lacerated in nearly seventy-five per cent., and in by far the larger proportion it was the inferior surface of the frontal or temporal lobes. Lacerations again, like limited contusions and indirect fractures, almost invariably occur at points directly opposite that at which force has been applied. It has been supposed that this fact, as it affects visceral lesions, is to be explained by a sudden displacement of the brain, which in its rebound strikes against the cranial wall and is bruised or wounded by its sharp or rugged prominences, and that this specially accounts for the greater liability to injury to the inferior surface of the lobes which occupy the anterior and middle fossæ. This theory is unsatisfactory, not only because there is no evidence that such movements take place within the cranial cavity, but because the local superficial lesions by no means usually correspond to the situation of the bony processes and irregularities, and because it fails to account for the central lesions. Their production has been also ascribed to

the change of form suffered by the skull in virtue of its elasticity when subjected to violence, which causes distortion of the brain to the point of rupture. It would seem, if this interpretation were correct, that the brain tissue should give way at one or the other extremity of the lengthened axis, and not so generally in the shortest diameter. Another explanation, which is suggested by Miles, is that in the displacement of the cerebro-spinal fluid by the consecutive cranial depression and bulging, which he believes to follow a blow upon the head, a momentary vacuum is formed at either end of the axis of force, and the vessels of the brain and membranes rupture from lack of support. Granting the correctness of the premises, superficial vascular lesions might occur in this manner, but hardly the considerable laceration of tissue, which is often in excess of the injury to vessels. It is still more difficult to conceive of lacerations in the central portions of the brain as being produced by these transient and distant if not trivial fluctuations of the cerebro-spinal fluid, while the immediate and firmer support of the general parenchyma remains intact, and the delicate walls of the pial vessels perhaps remain uninjured. There remains only the possibility of a direct propagation of force from its point of application, in straight lines through the intervening parts to the site of local injury, with such diffusion through the yielding cerebral substance as is manifest in the general lesions. There is no greater difficulty in accepting this simple explanation than in admitting the similar transmission of force through other media.

The cortical lacerations are, when recent, merely lacerated wounds containing more or less blood coagulum, with underlying shreds and granular detritus of brain tissue;

their base is usually pultaceous and stained with blood or of a grayish color. The contiguous brain matter may be softened or dotted with miliary extravasations, but is oftener of normal consistence and appearance. The wound may be circular, oval, or irregular in outline, not larger than a pea or perhaps covering the whole extent of the inferior surface of the frontal or temporal lobe. The resulting hemorrhage constitutes the cortical extravasation already described. The subcortical lacerations are usually more or less irregular cavities filled with blood, but after the removal of the clot their walls present the same ragged, discolored appearance, and the adjacent tissue the possible miliary extravasations which characterize the superficial lesions.

The subsequent history of these wounds is usually simple. If they are of considerable size, death ensues in a majority of cases before sufficient time has elapsed to permit any change of importance. The end to be hoped for in any wound with loss of tissue is cicatrization. Recoveries are by no means exceptional in which laceration seems to have been verified by symptoms, yet evidences of such a reparative process have rarely been discovered in the course of necropsic examinations. It is probable that small cicatrices are difficult of detection, and that large lacerations are not prone to heal. There is warrant, however, for the statement that fibrous cicatricial tissue may be formed, and the late Dr. Alonzo Clark described in detail the regeneration of nerve fibres after the occurrence of intracerebral hemorrhage. The formation of cysts, areolar tissue, and adventitious membranes, and various degenerative changes have been noted as terminations or results. Mr. Hewitt refers to a case in which two large cerebral

lacerations, uncomplicated by cranial fracture, were examined after many years. The surface was excavated and the arachnoid membrane bridged a cavity filled with serum and loose areolar tissue. In a case of gunshot wound, included in the appended series, the brain track after thirteen years was converted into a membranous canal. The process of reparation is evidently slow. After the lapse of seven months lacerations have been found to be still distinctly limited, uncontracted, softened, rusty in color, and without apparent inflammatory alteration.

The fatalities which immediately follow intracranial injury with laceration, are probably to be ascribed to concomitant hemorrhage or general contusion; those in which the laceration is the essential cause of death occur during a period which may be estimated as extending from the end of the first forty-eight hours to six weeks. During the first few days the contained clot becomes darker and more friable; at a later period, when death seems to have been due to laceration the wound has often assumed a sloughy appearance, which, with the antecedent symptoms, points to a septic infection. No inflammatory changes have been discovered in repeated microscopical examinations.

These several organic lesions represent the whole expenditure of the force derived from external violence, upon the cranium and its contents: fractures limited to the point of impact or propagated to a distance, limited or diffused contusions of the pia mater, wounds and bruises of the brain substance, and resulting hemorrhages from the osteo-meningeal and cerebral vessels, with occasional thromboses of the dural sinuses. These traumatic conditions are variously complicated with each other; and

general cerebral contusion, which is probably a constant factor in all intracranial injuries, may also occur as an isolated lesion.

Secondary Inflammations.

The traumatic intracranial inflammations are secondary to the immediate structural changes which have been described. They are properly sequelæ rather than complications, not only because they are chronologically later, but because the primary lesion comes between them and the receipt of injury. Their development may not be identically the same in all cases, but ordinarily if not invariably there are involved a structural alteration, the direct result of traumatism, which is essential, and a later infection, which is accidental. These two factors in their pathogeny may be considered fundamental. It is always hazardous to proclaim generalizations to be without exception, but the universality of the law that some appreciable injury of cerebral or meningeal tissue precedes its traumatic inflammation is sustained so far as observation is practicable. There are meningites in which the pia mater is so greatly altered by the secondary processes, and chronic abscesses of the brain in which the original lesion is so completely replaced by the purulent effusion, that the antecedent local conditions can only be inferred from the clinical history or from analogy; but in both disorders the vestiges of an abnormal pre-inflammatory state are in many cases recognizable after the inflammation has run its course. The strict limitation of a meningitis to the site of a meningeal contusion is often clearly shown in cases in which infection has taken place through a cranial opening, and in which, while the membranes in the vicinage of the

wound present a perfectly normal appearance, inflammation has been localized over some part of the opposite hemisphere. In other instances there are two or more widely separated sites of subarachnoid purulent effusion, each not more than an inch in diameter, or with an injury of the vertex, a single one of no greater size in some region of the base. It can hardly be supposed that these multiple or distant seats of inflammation were accidentally determined, but it may be reasonably assumed that their diminished power of resistance exposed them to the attack of predatory germs and hence localized the pathogenic process. There are few recent cases in which traces of meningeal or cerebral contusion do not confirm this assumption. The demonstration of the initial lesion in central abscess of the brain is often prevented by the protracted course of the disease, but even after the lapse of months some evidence of the original lesion may be possibly discovered in the minute examination of the wall of the cavity. The position of the abscess is always significant. If the skull has been fractured, the dura wounded, and the surface of the brain lacerated or contused, infection will be followed by superficial suppuration; if the dura remains intact, and the cerebral surface uninjured, the pus formation will occur at a deeper point of limited contusion in some line of transmitted force. In neglected pistol-shot wounds pus may form, either in the course of or upon one side or the other of the track of laceration, and even at two or more foci of inflammation. The severe contusion of the adjacent tissue and the abundant supply of infective material, which may be carried to any depth into the intracranial wound, account for the peculiar situation and frequent multiplication of abscess in cases of this

character. The lapse of time from the reception of injury to death from consequent abscess is usually so considerable that not only the indications of primary lesion may have disappeared, but the early history, if it was ever noted, is ordinarily lost. A mathematical demonstration, therefore, that the seat of central abscess of the brain is always the site of an original contusion or laceration, is even more difficult than in case of meningeal inflammation. The circumstances which tend to establish it inferentially are: its susceptibility of proof whenever satisfactory examination is possible; the confirmation afforded by attainable clinical histories; the fact that it is not directly propagated from the point at which violence has been inflicted; and the greater resistance offered by sound tissue to infection, which renders already damaged parts the natural prey of wandering pathogenic germs. The necessity of some structural injury as an antecedent condition of the establishment of either meningeal or parenchymatous traumatic inflammation seems scarcely in question. Either one of the meningeal lesions, whether limited or diffuse, seems to be adequate, but whether diffuse contusion always precedes diffuse inflammation is uncertain. The antecedent visceral lesions are subcortical laceration and limited contusion; general contusion with a local intensification may possibly be included. The cortical lesions lead to superficial abscess only when directly exposed to infection; those produced upon the side of the brain opposite to the site of injury, and those which occur without cranial fracture, are thus exempt from pyogenic change.

The immediate dependence of these inflammations upon microbic infection, an immigration of pathogenic

germs from without or from some other part of the body, has been proven in repeated instance by cultures of the affected tissue—in so many instances in fact that the only question which still remains is whether they ever originate without foreign intervention. The acceptance of the proposition that traumatic intracranial suppuration is even generally due to microbic invasion was at one time made unnecessarily difficult by the further averment that traumatic brain abscess never occurs without external wound. This is an error and is disproved by rather more than exceptional cases; two are reported by the author in a previous reference to the subject. The knowledge that pathogenic germs may reach the brain from more distant points through its vascular supply renders it at least conceivable that any cerebral abscess may be infective. It must be conceded that in by far the greater number of intracranial inflammations of traumatic origin, whatever structure may be implicated, there has been wound of the soft parts which invest the cranium. The external lesion may be confined to the tegumentary coverings of the bone, but must necessarily involve the periosteum. Simple subperiosteal exposure of the osseous surface, erosion or wound of the bone, punctured, linear, or depressed fracture, in the presence of pathogenic organisms may each lead to intracranial infection. One of these injuries may be more probably succeeded by infection than another, as the microbia are more or less deeply implanted, or otherwise more or less inaccessible to germicidal treatment. In the majority of instances, danger is synonymous with neglect. The osseous surface exposed, eroded, or wounded, or the edges of a compound linear fracture, can be made aseptic even if it require the use of a chisel, and the elevation of

a depressed fracture affords opportunity for the destruction or removal of lurking elements of disease. Fissures of the petrous portion, most frequent of all compound cranial fractures, can be made absolutely aseptic by careful occlusion of the ear. The punctured fracture may be attended by the direct introduction of pathogenic germs into the cranial cavity, or even into the brain substance, which are quite beyond the reach of aggressive measures; but the most thorough practicable removal of tangible foreign substances or fragments of bone and cleansing of the wound, and the most vigorous aseptic care, reduces the danger of infection to exceedingly narrow limits; the greatly diminished frequency of septic inflammations after pistol-shot intracranial wounds, since the wider recognition of the necessity of such a plan of treatment, clearly demonstrates how much can be accomplished by the use of aseptic and antiseptic methods, even under unfavorable circumstances. The most inaccessible osseous lesions, and consequently when infected the most intractable, are fractures through the ethmoid or sphenoid body, or of the occipital basilar process, with wound of the nasopharyngeal mucous membrane. It is not only impossible to subject them to efficient aseptic treatment, but they are peculiarly exposed to septic influences from their direct communication with both the digestive and respiratory tracts. In the usual instance of fracture through the ethmoid or sphenoid cells, derived from the vault, the nasopharyngeal membrane, if wounded, after a certain amount of hemorrhage is likely to be closed by primary union and danger obviated; but

and the imperfection of aseptic methods as they are ordinarily employed, the actual occurrence of traumatic inflammation of either the meninges or the parenchyma of the brain is comparatively infrequent. In the appended series of five hundred cases of intracranial injury of diversified character there are included but three central abscesses and one of the cerebral surface. The last was developed after fracture in the frontal region and in the absence of any surgical supervision, and one of the others had run its course prior to admission to the hospital in which its history was finally recorded; there remain but two which are fairly chargeable to this collection. The puffy tumor of Pott, the once so often observed cranial necrosis with underlying abscess, the late result of neglected and infected superficial wound, and now an almost extinct surgical phenomenon, is unrepresented. The instances of arachnitis are somewhat more numerous, but in some of these an infective origin was not demonstrable upon post-mortem examination; and in others it would seem that infection should have been prevented. The immediate treatment of these cases was for the most part in the hands of hospital assistants of varying degrees of capacity and experience, and aseptic methods, while employed with perhaps more than average care, were not always ideal. The infrequency of infective inflammation, therefore, is not to be ascribed to any exceptional rigor in aseptic management.

It is a possibility that in traumatic inflammation the pathogenic organisms should reach the cranial cavity through other channels which they are known to traverse in idiopathic cases, as through the tonsil, or Eustachian tube, and middle ear, or in the general circulation; but

this would be so purely a coincidence, and so unusual, as to require no special consideration.

There is no reason to suppose that the nature of the invading germ determines the site of infection. Ingress having been obtained, the morbid process may be extended in continuity from without, or may be established at a more distant point which has been made vulnerable by the primary injury. In this relation, the views of Macewen, the most recent writer of authority upon the subject of intracranial inflammation, have been abstracted or condensed so far as they concern the conditions of septic invasion and the degenerative processes by which they are followed.

"In a given case in which a cause of infective inflammation exists on the outside of the skull, from which the interior becomes affected, the alternative, whether meningitis or brain abscess results, depends partly on the anatomical arrangement of the structures and partly on the intensity and rapidity of the inflammatory action; which again may be dependent upon the micro-organism and the virulence of its action. One—or more—of several intracranial conditions, pachymeningitis, leptomeningitis, ulceration of the brain, abscess of the brain, and necrosis of the cerebral tissue, besides the involvement of the intracranial sinuses with disintegrating thrombosis, may result therefrom.

"*The various intracranial lesions which may result from pathogenic and saprophytic causes, and the manner in which organisms reach the intracranial structures:*

"(1) If the inflammatory process be slow, mild, and distinctly localized, involving a portion of the inner table of the skull, then an external pachymeningitis may form,

possibly with pus between the dura mater and the bone, producing an extradural abscess.

"(2) Should this condition persist, adhesive inflammation is apt to spread to the inner side of the dura, locally soldering it to the subjacent membranes and forming a barrier to the further extension of inflammation.

"(3) An increase of inflammatory action may induce degenerative inflammation with softening of the membranes and of the previous effusion, followed by disintegration of the pia and superficial ulceration of the brain tissue. Two conditions may thus result: a subdural or a cortical abscess, as the pia remains intact or as it suffers purulent softening. In either case the abscess is at first localized, but, should the disintegrating process involve the adherent membranes forming the wall, it may rupture and cause an acute leptomeningitis.

"(4) If the cause of inflammation extend to the inner layer of the dura before adhesion of the membranes has taken place, the whole subdural space is open to invasion and an acute far-reaching leptomeningitis is apt to ensue.

"(5) Leptomeningitis and cerebral abscess may form independently of a visible tract of inflammation spreading inward from the initial focus of irritation outside the cranial cavity. In such cases the pathogenic cause has been conveyed through the vascular system by direct extension from the source of infection. This may be done by a thrombosis extending through the veins into the pia or the brain; or the veins may become blocked by a localized disintegrating thrombus, portions of which containing pathogenic micro-organisms may be carried inward by the reversed blood stream, which is permitted by the absence of valves in the sinuses and intracranial and intra-osseous

veins, and is termed a reflex method of propagation. Infective matter may also be conveyed into the brain substance through the perivascular sheaths of the arteries, or partial infective and disintegrating thrombosis may form in an arterial trunk, and particles carried into terminal capillaries occasion minute infective hemorrhagic extravasations with resulting abscess. The occlusion of a large cerebral artery by embolus or otherwise causes extensive necrosis. Inflammation again may spread through the lymphatics or along the course of the perineural sheaths.

"Micro-organisms are the chief cause of intracranial pyogenic processes. In the great majority if not in all cases, they are the cause of both leptomeningitis and brain abscess. Whether the various forms of intracranial disease have each a distinct specific organism which produces it, and it alone, is for the future to decide. It is, however, probable that the same organism may induce several of these intracranial lesions, the modifying circumstances being the degree of its action, its opportunities of access to the intracranial contents afforded by the pathologico-anatomical conditions of the parts, and the degree of the restraining force of the living tissues presented by the individual.

"The pathogenic organisms found in suppurative leptomeningitis and in brain abscess, as tested both by the microscope and by careful plate cultivation in the author's cases, have most frequently been the streptococcus pyogenes and the staphylococcus pyogenes aureus. Occa-

tubercle bacillus, odium albicans, and the diplococcus pneumoniæ of Fraenkel, have been found in more or less exceptional cases of intracranial suppuration.

"**Acute Leptomeningitis.**—When acute inflammation is once established in the loose arachnoid meshwork, it spreads rapidly and widely until the whole cerebro-spinal, subdural, and intraventricular spaces are involved, as well as the pia mater, and in some instances the superficial layers of the brain. The sheaths of the cranial and spinal nerves are likewise implicated for a considerable distance outside the central cavities. When pathogenic microorganisms are inoculated into the cerebro-spinal fluid they spread with remarkable rapidity, finding a suitable temperature and abundant pabulum for their development.

"**Acute Serous Leptomeningitis.**—Hyperæmia is followed by an exudation of clear serum, often containing flakes of fibrin, and occasionally a few leucocytes, and possibly even a few pus corpuscles in the perivascular sheaths of the cortical vessels. The serous effusion may be so abundant and so rapidly produced as to cause death from compression, and when it persists the ventricles become greatly distended. The inflammation may be localized, especially when, extending from without, it involves the visceral aspect of the dura, the inner membrane having become soldered at the periphery of the affected zone, though free in the centre. If seen through a trephine aperture during life, many of the minute arteries seem to be lifted from the pia mater, as if floating in the clear fluid contained in the almost invisible arachnoid meshwork, but are probably resting on the outer strands of the œdematous membrane. The arteries are far more numerous than usually represented, and the veins are

large and full. The pia is swollen, œdematous, and much injected, and the underlying brain is moist and glistening. After death the appearances are greatly altered, and it is often difficult to find by the naked eye sufficient indications to account for the fatal termination; the serum is apt to escape in the removal of the calvarium, there are few capillaries in the meninges, and even the congestion of the white substance disappears to a great extent from post-mortem changes; the only indication of hyperæmia of the white substance is distention of the vessels.

"In **purulent leptomeningitis,** besides hyperæmia and serous effusion, there is great exudation of leucocytes into the perivascular spaces, with intense dilatation of the veins, their periphery being marked with opaque white and yellow exudation caused by degeneration of leucocytes. The coats of the vessels are traversed by leucocytes, and the veins are frequently plugged with granular coagula. The exudation is at first confined to the arachnoid tissue and pia matral clefts and spaces. It may extend to the brain, and through the transverse fissures to the telæ choroidæ, which then swell and become covered with pus and fibrino-purulent exudation. The underlying brain substance is then moist and soft, and the fluid within the ventricles is turbid and sero-purulent.

"If the inflammation is due to infective causes, there is always involvement of the cerebral tissue, especially the cortex, which undergoes extensive inflammatory changes. These may extend into the cerebral cortex by the pial sheaths of the veins, which become filled with leucocytes, or there may be direct extension of the inflammation, facilitated by prior adhesions of the membranes. In such cases

with cells. Accompanying the purulent meningitis there is frequently implication of the interior of the brain in the form of minute extravasations in the perivascular sheaths, and larger ones in the cerebral tissue; the latter being generally surrounded by an area of cerebral softening, which areas may ultimately be the seats of purulent exudation.

"In the formation of **purulent encephalitis,** besides the swelling of the cerebral substance, there is excessive serous and leucocytal exudation, and extravasations of red blood corpuscles, which are of very frequent occurrence in acute inflammation of the brain.

"**Red softening** is a condition occasioned by the coalescence of many of these minute hemorrhages. The red corpuscles are effused into the perivascular sheaths or into the brain tissue itself and are soon followed by leucocytes, which are exuded in large numbers from the vessels. The affected area of the brain is swollen and œdematous, and on section projects above the level of the healthy structure. As the exudation continues, the nerve tissue degenerates; a process of molecular disintegration ensues, in which the minute particles of brain tissue become mixed with the disintegrating leucocytes which have formed into pus cells.

"**White softening** is a condition in which, with very little hemorrhagic extravasation, a primary leucocytal exudation passes directly into pus production and molecular disintegration, as above described. Pathogenic embolism in a cerebral artery or vein of the white substance occasions hemorrhagic extravasation, accompanied or shortly followed by an exudation of leucocytes, which infiltrate the extravasation and contiguous brain tissue. These leuco-

cytes rapidly degenerate into pus, while the neighboring nerve tissue disintegrates and liquefies. These emboli may be accompanied by anæmic or hemorrhagic necrosis, as an artery or a vein has been blocked. This may be indicated by the parts during operation: when they are œdematous and glistening they are anæmic, and therefore due to arterial thrombosis; and when they appear as reddish-brown sloughs they are hemorrhagic, and due to venous thrombosis. When large arteries are blocked, a necrosis of extensive area may occur, which may be afterward separated. Such large necrotic portions may also arise from very acute and infective inflammation.

"**Cerebral Abscess.**—The pus contained varies much in color and consistence. When mingled with much disintegrated tisue which has been infiltrated with extravasations of blood, it is of a dark-brown color; when free from such extravasations it is greenish-yellow in color, probably from the presence of the bacillus pyocyaneus; when very fœtid, it is thin, serous, and generally contains many minute sloughs, and when connected with disease of the middle ear may also contain the bacillus pyogenes fœtidus. Micrococci are abundant, especially at an early period.

"**Peripheral Changes.**—The vessels of the tissue surrounding and forming the boundary of an acute abscess may be seen in all stages of inflammation, from hyperæmia in the outer zone to thrombosis in the inner. Surrounding the vessels are masses of exudation cells, mingled with extravasated red corpuscles; and the glimpses of

nizable, on account of the exudation cells not only filling the surrounding parts but also the vessel wall and in great measure occupying its interior, the red corpuscles being faintly seen in some, while in others they have entirely disappeared. Irregularly distributed over the surface of the abscess are minute sloughs of an œdematous, grayish appearance, with pus in their periphery and in the pockets and sinuosities in the abscess wall. The surface toward the abscess is flocculent, shaggy, and irregular in outline, with occasional little naked thrombosed vessels projecting into the cavity. As in a process of ulceration in other parts of the body, the small vessels become thrombosed in advance of the molecular necrosis, and so hemorrhage into the abscess is usually prevented. The zone of peripheral brain tissue is œdematous and its vessels are hyperæmic. There is thus no other wall of an acute abscess than a softened and disintegrated tissue filled with exudation cells and extravasated blood.

"The pia and arachnoid over an area of degeneration have often a milky or turbid appearance.

"**Encapsulation.**—When the process of molecular disintegration ceases, and the brain tissue possesses sufficient vitality to assume a formative action, the débris of disintegrated granular cells, leucocytes, blood, and inspissated pus, becomes entangled in the meshes of fibrin, the elements for the formation of which are poured out from the living tissue. Into this mass large numbers of leucocytes penetrate, some of which form bundles of elongated spindle cells. Later a few blood-vessels of the most primitive description project from the living tissue into the membrane and supply nutriment to the leucocytes in their immediate neighborhood. The pus thus becomes encapsu-

lated by a layer of membrane of very low vitality, which shuts off the living brain tissue from the dead pus within. The abscess thus becomes to a great extent stationary; first, because the process of molecular degeneration has ceased, and second, because the leucocytes which penetrate for some way into the living wall of the abscess, and which might be converted into pus were they shed on the inside of the capsule, are principally caught by the meshwork of fibrin, so that few pass into the abscess cavity. As the lining membrane thickens, the difficulties of the transmigration of leucocytes increase, both on account of the great distance they have to travel and the continued formation of fibrous-tissue bundles. Thirdly, this membrane, though it permits the passage of serum from the pus cavity to the vessels of the living tissue, yet prevents the absorption of the particulate portions of the disintegrated pus. The capsule, from one to five or more millimetres in thickness, is generally smooth internally and rather ragged and flocculent externally, and more regular in outline than the boundary of the acute abscess.

"**Absorption.**—A cerebral abscess may become absorbed from changes which take place in its wall from the side of the living tissue. The circumferential pressure of the brain may facilitate absorption of the fluid portion of the pus, while well-formed vessels may be thrown out from the living brain tissue, and penetrating the capsule may thus aid in the absorption of pus débris through phagocytic action. In this way a considerable portion of a small abscess may become absorbed.

"**Growth from within** is possible if the capsule be replaced in part by a layer of vigorous granulation tissue, a fresh supply of pus being formed, which may augment the

size of the abscess and exercise pressure from within upon the capsule, which thus becomes thinned in parts. The abscess may then burst either into the ventricles or into the subdural space.

"**Discharge.**—Abscesses may empty themselves externally through the tegmen tympani, cribriform ethmoidal plate, or posterior condyloid foramen, by adhesion of the membranes and absorption of intervening brain tissue. They may also break into the subdural tissue or into the ventricles, causing acute suppurative leptomeningitis, which in the subdural space may be limited by membranous adhesions previously established.

"**Secondary abscess** may form in the periphery of one already encapsulated. Neighboring tissues are not always tolerant; compression may induce degeneration and atrophy; slight causes may then occasion fresh œdema and inflammation, which becomes purulent. It is probable, however, that a leakage of the contents of the abscess into the compressed tissues in the vicinity may set free micro-organisms which regain their vitality and excite a fresh inflammation. In such case the original abscess may sometimes be found floating in the pus of the one consecutively established.

"**Pyæmic abscess** may be caused by septic matter originating in some distant source, in any part of the body, and carried in the blood stream until deposited in a small vessel producing infective embolism. Disintegrating pneumonia, fœtid bronchitis, pericarditis, or empyema, and infected compound fractures, are among the diseases and injuries from which it is derived. It is multiple in two-thirds of the cases in which it occurs, and it invades both cerebrum and cerebellum. Traumatic abscesses are single

in ninety-three per cent., and are usually situated in the frontal or parietal lobe.

"After an abscess has been evacuated, the brain tissue tends to fill the gap; if the abscess be acute, a few hours suffice; if it be chronic, it may be days before the cavity is obliterated. When the brain has been once closed by the resiliency of the brain tissue, there is a probability that the brain, while more or less fixed to the dura, will remain otherwise free from adhesions. When the wound heals by granulation tissue, the pia mater adheres to the cicatrix, soldering the brain to what becomes a rigid wall. Such an anchoring of the brain is left subsequently to produce a shock on sudden movement, as on rising from a recumbent or sitting position, causing unconsciousness, generally of brief duration. This, when frequently repeated, may in time produce encephalitis over an extended area.

"Occasionally a depression filled with serum, rarely with cerebro-spinal fluid, remains upon the brain surface over the site of the former abscess.

"Necrosis of a portion of cerebral tissue may be caused: (1) by infective embolism or thrombosis of the main artery supplying a portion of the brain, resulting in anæmic gangrene; (2) by embolism of the main veins, with hemorrhagic necrosis; (3) occasionally by localized pressure by a part engorged by extravasations, which may lead to disorganization and death of neighboring brain tissue; (4) by intensity of inflammatory action due to the nature of the micro-organism."

This somewhat extended summary of Macewen's account of the infective intracranial inflammations is justified by the completeness and accuracy with which he has traced their pathic relations, and the attempt to rewrite

their history could be made successful only by trenching largely upon the mass of fact and inference which he has so adequately presented. There are certain considerations, however, which especially pertain to cases of traumatic origin, to which attention may be further directed. In this restricted class, it is the localization of the initial lesion, whether laceration or limited contusion, which determines the alternative of arachnitis or cerebral abscess, rather than the anatomical structure, grade of inflammatory action, or peculiarities in the nature of micro-organisms, to which Macewen in his study of intracranial inflammation attributes the occurrence of pyogenic processes in one tissue in preference to another. The contention that the site of election for these inflammations is in the part which has been weakened by wound or bruise, and thus invites attack from pathogenic germs, or succumbs to pathic processes already established, was made in the original publication of a case of cerebral abscess,* No. XXXII. in the present series. In this instance, in which death occurred at an early period, the formation of abscess at the site of a subcortical contusion was demonstrable. The point of invasion having been determined, the extension of the disease, its intensity, the conditions of its development and progress, may be conceivably controlled by the virulence and extent of the microbic infection, or influenced by the structural characteristics of the tissue involved.

The traumatic intracranial infections have been practically limited to the two which have been specifically mentioned—arachnitis and cerebral abscess—both arising at a point distant from the cranial wound, if one chances to

* New York Medical Journal, vol. li., No. 13, 1891.

exist. The occurrence of the several forms of pachymeningitis and arachnitis, and the formation of subdural and cortical abscess, through the spreading of an inflammatory process by continuity from an infected external wound, though still possible, is in the highest degree improbable, except as the result of gross ignorance or neglect. A diffuse purulent inflammation of the brain substance, which may follow the use of drainage tubes, is probably unknown, as is red softening as an effect of violence. All these conditions may occur in connection with cases of otitis media, from which a knowledge of the phenomena of intracranial infection has been so largely derived. In traumatic infection the micro-organism finds access to the cranial cavity through a direct breach of its walls, traverses some one of the several channels which have been enumerated, and discovers for attack that part of the brain or meninges in which resistance has been minimized by previous injury and to which, in the brain at least, the morbid process is confined. The possibility of accidental infection through the general circulation without superficial wound is too remote to be taken into account.

The question whether these inflammations can arise

examination of the pus of either inflammatory process has failed to disclose the presence of pathogenic organisms. It should be said at the same time that comparatively few cases are subjected to this test, for which facilities are usually wanting; nor is it necessary to regard infection as an essential condition of suppuration. Pus is demonstrably formed elsewhere without microbic intervention, and there is no reason why it might not be so formed equally well in the cranial cavity. The occasional occurrence of purulent arachnitis, or of brain abscess from head injury in which no superficial wound or cranial fracture has been involved, adds to the probability that such is sometimes the case.

The occurrence of amicrobic inflammation is ascribed by Gouley to the irritation of dead atoms which have failed of absorption. It may happen that "individual human cells undergo nutritional alterations, or even starve to death from insufficient pabulum, or from its exclusion by the sudden plugging of a neighboring vessel, and are cast away if there be a proper channel for their exit; or otherwise may be devoured by leucocytes, or taken up as effete material and excreted." In the case of intracranial contusion the capillary obstruction may thus lead to molecular death of meningeal or cerebral tissue, which is ordinarily followed by direct absorption and excretion; or in exceptional cases, in the absence of infection, the dead tissues, like micro-organisms or other foreign matter, may remain, to be at "once attacked by migrated leucocytes which strive to ingest and digest the offending substance, or it may chance that many of these leucocytes die in the struggle, or are so numerous as to crowd themselves to death, and form what is called pus." This explanation, which is

based in part upon Bland Sutton's theory of inflammation, is adequate to the comprehension of a non-infective pyogenic process. Any foreign particles, whether exanimate atoms of tissue or microbia, may be sufficient as irritants to excite the initial migration of leucocytes. If the amicrobic pyogenic process rarely or never occurs as a result of intracranial lesion, it is because molecular necrosis is insignificant and absorption immediate, or because the leucocytal host is victorious in attack.

The conditions which favor or determine the event of a subacute amicrobic arachnitis as a sequel of meningeal contusion are uncertain. Age, previous habits, or constitutional condition have no recognizable influence, and it seems to be independent of the nature of coexistent lesions. Its invasion is usually late, and its general history is best interpreted upon the supposition that, engrafted upon the primary tissue changes, its development is in the usual course of idiopathic secondary serous inflammations in prolonged disease.

The use of the term arachnitis in place of leptomeningitis is a reversion to a more exact nomenclature, and was suggested by Alonzo Clark some years ago on the ground of anatomical propriety. The pia mater is merely a subserous tissue in which the nutrient vessels subdivide, and is analogous to the subjacent tissue which contains the vessels of the pleura or the peritoneum. The inflammation, which is the sum of certain irritant vascular disturbances in this structure, is an arachnitis, as similar changes in the pleural or peritoneal subserous tissue constitute a pleurisy or a peritonitis. The fact that the exudation occurs upon the attached rather than upon the free surface of the serous membrane, in this instance is only an acci-

dent dependent upon its exceptional looseness of attachment.

Reference is often made to a supposed result of intracranial injury, which is designated encephalitis. In a proper sense of the word no such condition exists. A pyogenic inflammation may extend from an infected cranial wound through the meninges and include the cortex, or a similar process in a portion of the brain substance may reach the meninges, and in an arachnitis the contiguous brain surface may also be infiltrated with cells; but a concurrent general inflammation of the several intracranial structures is unknown, from any definitely recorded observation. The term is usually employed as a synonym for cerebritis or phrenitis, which are equally apocryphal. A pyogenic process is evidently not implied, but a simple cellular infiltration of the whole, or of some considerable portion, of the parenchyma. In a minute structural examination of many hyperæmic and œdematous brains, taken from patients who had survived injury for some days or weeks, no evidence of such a form of inflammation has been discovered. The vague descriptions of traumatic cerebritis or encephalitis, which are encountered from time to time, are never consistent with such a disease or verified by necropsy, and are to be regarded as no more than a misapplication of words or pure assumption.

There is a very exceptional form of brain inflammation which is not pyogenic, and is not of the class of pseudo-inflammations just mentioned. It is of a cirrhotic character and results in a true atrophy of the part involved. The leucocytes, which have invaded the region of injury and successfully destroyed the irritant necrotic or other foreign matter which led to their migration, are under

certain unknown conditions formed into a new and contractile tissue in place of undergoing the usual process of fatty degeneration and absorption. It has been produced incidentally in experimental needle punctures, but is so nearly unknown clinically that its history cannot yet be written. The appended series of cases contains a single instance, which is the only one within the knowledge of the writer. This was observed in a necropsy, seven months after the reception of injury, and was confined to the right temporal lobe, which was indurated and reduced to not more than from one-half to one-third its normal size; the original nerve tissue had largely disappeared; an extensive laceration existed upon its inferior surface which presented no evidence of the beginning of repair. The patient had suffered a convulsion on the fifteenth day after injury, and was without further symptoms until subjected to an operation for fractured patella six months afterward. This was followed by severe convulsions and wild delirium, which recurred one month later and occasioned death from exhaustion. Laceration was the prominent lesion, but the secondary interstitial inflammation which supervened might equally well have resulted from a concomitant regional contusion of this lobe. The convulsions which marked the progress and termination of the case seem to have been directly symptomatic, but, as will be established later in a study of symptoms, convulsions are characteristic of laceration of the same part; the seat rather than the nature of the lesion is likely to have determined their

Chapter II.

SYMPTOMATOLOGY.

DIRECT LESIONS.

THE intrinsic difficulty which has been encountered in the interpretation of symptoms, resides in the usual complexity of lesions, and has been increased by their apparent identity in cases in which dissimilar pathic conditions have been found to exist. It is necessary at the outset to recognize the fact that without exception they result from demonstrable organic change. It is also essential to discard the use of comprehensive terms by which it is sought to group or to contrast symptoms without reference to the structural alterations upon which they depend. In this way concussion, encephalitis, and compression will be eliminated from consideration and the study of symptoms greatly simplified. The prevalence of erroneous views of pathology, and unwarranted or faulty generalizations in symptomatology, with the force which they derive from prescription, may be reckoned extrinsic causes of diagnostic uncertainty.

As each form of intracranial injury is attended by characteristic outward manifestations, and as no evidence exists that these occur independently of anatomical change, symptoms should be grouped under the name of their pathogenic lesion. Any other classification of traumatisms is arbitrary, misleading, unphilosophical, and contrary to accepted principles of nosology. These intracranial le-

sions, reaffirmed in brief and arranged with reference to their clinical indications, are: 1. Hemorrhages. 2. Diffuse and limited contusion of the brain. 3. Laceration of the brain. 4. Secondary inflammations of the brain and arachnoid membrane, which are almost invariably pyogenic.

Meningeal contusion is either merged in a general contusion of the brain substance or results in a hemorrhage or inflammation, which may be considered in connection with the same conditions arising from other lesions.

The exclusion from consideration of purely hypothetical disorders, the establishment of an absolute dependence of symptoms upon demonstrated lesions, and the adoption of an exact anatomical classification of these traumatic morbid conditions go far toward making their symptomatology comprehensible. The difficulty which remains, arising from a concurrence of lesions with or without similarities in outward expression, is to be met by the study of cases in which the lesion is single, or in which one of several is primary and of paramount importance. The knowledge thus gained may be applied to the elucidation of more complicated traumatisms.

1. Hemorrhages.

The general impression as to the exceeding frequency of hemorrhage in intracranial injury is justified by an examination of the appended series of cases. In from fifty per cent. to sixty per cent. it occurred in sufficient quantity and in such relation as largely to influence the final result, and to become a determinate factor in the genesis of symptoms. In one-third of this percentage it was the direct if not the sole cause of a fatal termination. In a

very large proportion of the whole number it was secondary to laceration, and while this was in itself often insignificant, the hemorrhage was none the less profuse and the source of both symptoms and danger. In the residue of cases in which it was primary, it was associated with some degree of other structural alteration. The opinion has been already expressed that in all intracranial injuries a certain amount of general contusion of the brain substance will be found to exist, and in few of these necropsies was it so slight as to seem unimportant. There are, however, many instances in which hemorrhage is the essential lesion and which may afford sufficient ground for inductive examination. Thirty-one such cases have been selected for analysis; they comprise eighteen of epidural and thirteen of pial origin. Eight recovering cases, in which the existence of hemorrhage was verified by operation and in which no considerable complication existed, have been added, making a total number of thirty-nine. Some of the necropsic cases have been included, notwithstanding the existence of a well-marked cerebral contusion, because the hemorrhage was large and its symptoms likely to be characteristic.

The one constant symptom in fatal cases was some degree of unconsciousness. In the majority it was profound, or at least complete, from the moment of injury to the end of life. In five others consciousness was primarily lost, and after more or less complete restoration was merged in final coma. In four instances consciousness was retained for some length of time, during which the patient walked for a considerable distance, and then either gradually or suddenly became unconscious. In two cases of late unconsciousness, delirium followed and continued till death

occurred; and in two others, in which unconsciousness was primary, delirium followed hard upon it without a period of conscious intelligence. In the operative cases, in which recovery ensued, and in which it is fair to assume that the effusion was smaller, loss of consciousness was less constant, occurring in but half their number. In two the mental condition remained unaffected, and in one unconsciousness was replaced by delirium. Of three cases in which delirium was a symptom, it was very transitory in two, and in one but moderately prolonged.

The varying phases of unconsciousness, the diverse symptomatic conditions with which it is associated, and the uncertain period of its occurrence, render it impossible to accept the traditional explanation of its existence, that it is solely dependent upon a mechanical compression of the subjacent brain substance by the blood which has been extravasated. It is probable that as a primary symptom—as an instantaneous result of injury—it is due to general cerebral contusion, which is itself an instantaneous lesion. It has been seen that in the larger number of the fatal cases collated it has been absolutely the first symptom, not only at the time of admission but as learned at the scene of accident and noted in the ambulance history. The effusion of a sufficient amount of blood to act mechanically requires an appreciable interval. This is evident in certain of the cases of rupture of the arteria meningea media, in which some hours elapsed before the patient became unconscious, and in which the epidural clot was found to be of enormous size. There may or may not be a restoration of the intellectual faculties between the earlier and the later phases of consciousness. The general cerebral contusion may be so severe that the unconsciousness which

it produces will continue till the effusion has become sufficient to occasion the same condition, and one is lost in the other. It is also possible that the cerebral lesion may be insufficient to arrest consciousness for the time necessary to the effusion of blood in sufficient quantity to act as an immediate stupefying agent, and there is no primary mental obscuration. This opinion as to the manner in which loss of consciousness occurs in intracranial lesions will be strengthened by the wider comparison of cases to be made in which hemorrhage was a contributive rather than an essential lesion, and in the direct study of other forms of injury.

The exceptional occurrence of delirium is probably to be attributed to the cerebral lesion, which was well marked in each instance.

Much importance has been attributed to disturbance of the pupils in traumatic hemorrhage, and a lack of symmetry was observed in the greater part of the cases now subjected to examination. It was unnoted in three of those which were fatal and in three of those which were submitted to operation; the pupils were normal in but five out of the remaining thirty-three. The pupils in the cases of abnormity afforded almost every possible combination of dilatation with contraction. In seven cases both pupils were dilated, the hemorrhage in four being epidural, in two pio-arachnoid, and in one epidural and pio-arachnoid combined; in four cases both pupils were contracted, the hemorrhage being in one epidural, in one pial, and in two both epidural and arachnoid; in six cases the pupil was dilated on the side of injury and contracted on the opposite side, while in two cases the pupil was contracted on the side of injury and dilated on the opposite side, the

hemorrhage in each being epidural and derived from the middle meningeal artery; in three cases the pupil was dilated on the side of injury and normal on the opposite side, the hemorrhage in each being epidural; in three cases the pupil was normal on the side of injury and dilated on the opposite side, the hemorrhage being cortical in two and epidural in one; in one case both pupils were primarily contracted, and later one became slightly dilated on the side of an epidural and of a pial hemorrhage; and in a final case both pupils were at times dilated, and at others only the corresponding pupil, the hemorrhage being pial. There was no instance of contracted pupil on either side without change in its fellow. In the three cases in which both pupils remained normal, the hemorrhage was epidural in one, pial in another, and cortical in the third. The hemorrhages occurred upon every part of the cerebral and cerebellar surfaces, vertex, and base.

There seems to be no change in the pupils which is positively characteristic. In two-thirds of the cases analyzed, the hemorrhage was wholly or in part epidural, and in two-thirds of these again one pupil or both was dilated; but as in the aggregate all sorts of pupillary changes resulted from all sorts of hemorrhages, their observation can be scarcely more than confirmatory of an opinion justified by the collation of other symptoms. The unilateral dilatation of the pupil on the side corresponding to an epidural extravasation, correctly attributed by Mr. Hutchinson to pressure upon the third cranial nerve, is the only pupillary condition which is in any sense diagnostic. If an epidural hemorrhage is sufficiently large, and occupies the anterior part of the middle fossa, it is an almost positive symptom; but in any other form or situation of hemorrhage there is

no reason for its occurrence, and even in large epidural effusion from rupture of the arteria meningea media the corresponding pupil may be normal or contracted and dilatation occur upon the opposite side. The pupillary variations, aside from the dilatation which comes from direct pressure upon the third nerve, are to be referred not to hemorrhage but to coincident cerebral injury. The fixity of the pupil will be usually proportionate to the extremity of its contraction or dilatation, and will indicate the extent or severity of the lesion with which it is associated.

The temperature which attends intracranial hemorrhage is characteristic when considered in relation to surrounding conditions. It hardly requires an examination of cases to prove that the direct effect of a loss of blood is to depress all the vital functions—to diminish temperature, as it relaxes the muscular system or weakens the force of the circulation. If the extravasation is rapid or profuse, it is an essential element of shock, and temperature is at once reduced below the normal standard. If the hemorrhage is not too great to permit reaction, the temperature becomes and remains normal. The coincidence of lesions characterized by an elevation of temperature may counteract the effect of shock and there is no reduction, or there may be even an increase of heat at the beginning; the secondary temperature will then be elevated in proportion to the extent of these coincident lesions. As hemorrhage is never absolutely independent of cerebral injury, if the patient survive the immediate depression of shock there will always be some subsequent elevation of temperature. In comparatively uncomplicated hemorrhage, therefore, the primary temperature should be normal or subnormal as the effusion varies in amount and as shock is more or less

pronounced; and later should be only moderately increased. The facts derived from clinical observation are in accord with these preconceptions. In seven of the necropsic cases previously selected for examination, the temperature was unrecorded; in thirteen it was subnormal on admission to the hospital, and in eight it was from 99° to 99° + ; in two it was 101°, and in one it was 102°. In the three cases last mentioned, general cerebral contusion was sufficiently pronounced to account for the special rise in temperature. In those cases in which it subsequently exceeded 101°, eight in number, there was in each instance some severe coexistent lesion—general contusion in all, which in several was excessive and in two was attended by laceration. In the only one of the eight operative cases in which temperature at any time attained an elevation of 102°, it accompanied the formation of a fungus cerebri. In these thirty-nine cases, best fitted for observation as presenting hemorrhage in as nearly an uncomplicated or distinctive form as the conditions of intracranial traumatism permit, the characteristic temperature would thus seem to range from 99° to 101°, after reaction from shock.

The pulse was unnoted in five cases. It was normal in four cases, in two of which hemorrhage was epidural, covering the convex surface of a hemisphere, and in two was of pial or cortical origin, occupying the inferior occipital fossæ. In ten cases in which the pulse was slow, the hemorrhage in each was epidural and the patient entirely unconscious. In the remaining cases the pulse was frequent and the hemorrhage was of either variety and variously situated. In neither the fatal nor the operative cases was there any further definite relation discovered

between the characters of the pulse and the seat or nature of the hemorrhage, nor between them and the associated symptoms. There is another pulse condition, a want of symmetry in the radial pulsations upon the two sides of the body, which is also found to occur in connection with other intracranial injuries, the consideration of which may be conveniently deferred.

The respiration was sometimes normal at the first observation, or even until the end, but oftener it was accelerated or retarded. It is generally supposed that a full, slow, and stertorous respiration is characteristic of a free intracranial hemorrhage. This was true of a certain proportion of the cases which have been cited, but not of a sufficient number to establish a general rule. The variations from such a standard were constant and apparently independent of the form or location of the hemorrhage. Thus in two large pial effusions over the vertex, respiration was in each primarily unchanged, and later became in one rapid and in the other slow and stertorous. In two large epidural extravasations in the same situation, it was in one stertorous and of nearly normal frequency, and in the other was continuously accelerated without other change. In two other epidural cases it was slow throughout their course, but without stertor. In still other cases, stertor was noted with either slow or rapid respiration when hemorrhage had occurred into the anterior basic fossæ or upon the surface and in the vicinage of the pons. In all these instances some degree of general contusion existed, but no localized complication. In general, the frequency of respiration was oftener increased than diminished. None of the recovering operative cases presented any noticeable deviations from the normal standard. There is one form of

hemorrhage in which the respiratory indication is positive: in this, the effusion, which is always of pial or cortical origin, encroaches upon or covers the medulla, and respiration either suddenly ceases or is briefly continued, with perhaps not more than two to four inspirations per minute; this extreme infrequency of respiratory action is never observed with subsequent recovery of the patient. A number of cases of this character are to be found in the appended series. In thirteen such cases the hemorrhage more or less thickly covered the pons and medulla, in three of which the blood was still fluid; in seven of them it was derived from cortical laceration, and in six from meningeal contusion. In five instances death was sudden and the final respiratory acts were unnoted; and in two others record was neglected. The peculiarities in respiration which they present may be best exhibited in tabular form:

No. 1–5. No record.—Death sudden.

No. 6–7. No record.—Neglect.

No. 8. Respiration, 7 per minute—only one record made. Death in five minutes.

No. 9. Respiration normal till suddenly reduced to 13 and then to 7 just before death in eight and one-half hours.

No. 10. Respiration 13 per minute on admission, reduced to 4 at death in twenty minutes.

No. 11. Respiration 14 per minute on admission; 12 for one and one-half hours; 10 at end of two and one-half hours; 8 at end of three hours; 6 at end of four and one-half hours; 4 at end of five hours; and 2 a few moments later, *in articulo mortis*.

No. 12. Respiration 2 per minute at first record at time of death, thirty minutes after admission.

No. 13. Respiration 5 per minute from first observation immediately after injury till a moment before death twenty minutes later, when it was reduced to 3.

In two instances radial pulsation continued for two and three minutes after respiration had ceased, as sometimes happens after mechanical occlusion of the larynx or trachea.

In an additional case, in which a cortical clot was found upon the pons and some small coagula upon one side of the medulla, the respiration on admission was five per minute when the patient was quiet, but increased to twenty to twenty-five when he was disturbed, and subsequently ranged from thirty-six to forty-six till death. It is probable that the small coagula observed upon the medulla were traces of a larger hemorrhage, which primarily encroached upon its lateral aspect and at that time retarded the respiratory function.

In three cases the hemorrhage covered the medulla, with little or no implication of the pons:

1. After recovery from a brief period of unconsciousness death occurred suddenly twenty-five minutes later. Respiration could not be noted; the hemorrhage was pial.

2. Respiration, 30 per minute on admission; one and one-quarter hours later death occurred suddenly, respiration having dropped to 4. Cortical hemorrhage from a laceration of the cerebellum covered the posterior surface of the medulla; the fourth ventricle was also distended by a clot.

3. Thirty-six hours after admission respiration was suddenly reduced to 4 in the minute, and death followed

thirty minutes afterward. A cortical hemorrhage covered the anterior medullary surface and extended into the spinal canal.

In two cases a pial hemorrhage which reached the pons did not extend to the medulla:

1. Respiration on admission, 21, with occurrence soon afterward of a sudden attack of extreme dyspnœa and cyanosis, which lasted only three or four minutes, and was followed by numbness of both arms. There was no further respiratory disturbance. Death eighteen hours later.

2. Respiration on admission, 21, which later was increased to 42 per minute. No cyanosis or pulmonary œdema.

Though the pons and medulla were both involved in the great majority of instances, the fact that diminished frequency of respiration characterized other cases in which the medulla was alone affected, and was not observed in others in which the extravasation reached the pons without extending to the medulla, clearly demonstrates the medullary origin of this symptom. It seems hardly questionable that it results from direct compression of the respiratory centre. If the access of blood to the medullary surface is sufficiently sudden and profuse, whether at the time of injury or at some later period, the cessation of respiration may be without warning and as instantaneous as in direct destruction of the ganglion; if the afflux be gradual but persistent, its retardation may be as slowly progressive as in the cited case, in which it could be watched through hours. It is remotely possible that the accumulated blood, while still fluid, may detach itself and the incipient paralysis of the respiratory function

be relieved, as is suggested by the history and post-mortem appearances of another of the tabulated cases.

Certain cases in which respiration was equally retarded, and in which opportunity for necropsic confirmation was wanting, have not been described.

Cyanosis and pulmonary œdema, which occurred in but five instances, including the two in which hemorrhage did not extend beyond the pons, are independent of the ganglionic disturbance. These symptoms in this relation are to be ascribed to compression of the intracranial portion of the pneumogastric nerve.

Irregularities of respiratory rhythm, which are occasionally noted in cases of hemorrhage, are due to concomitant cerebral lesion.

The disturbance or abrogation of muscular function was an occasional symptom, and was exhibited in accordance with established laws of cerebral localization. Paralysis occurred in three of the fatal cases and in two of those which recovered after operation; it was hemiplegic in four and paraplegic in one. Muscular rigidity, affecting one side or both, occurred in six cases; and general convulsions in three, in one of which the paroxysms preceded injury; simple twitching of the muscles characterized three others. In each case some part of a motor area was covered by the hemorrhage, which was variously epidural, pial, or cortical, and acted as a paralyzing or an irritant lesion, according to its extent and situation. These motor disturbances, while of great positive diagnostic importance, are so frequently absent that they have no corresponding negative value. In a single case in which there was protrusion of both eyes as well as dilatation of the pupils, there was found an epidural clot in the right inferior

occipital fossa, and a thin cortical hemorrhage which covered both frontal and both parietal lobes as far as the fissure of Rolando.

Psychical disturbances were still more infrequent. Delirium occurred in several instances; in one, which was primary, the hemorrhage, as disclosed by the trephine, was epidural and in trivial amount; in the other and fatal cases, in which the hemorrhage was pial or cortical and in larger amount, there was no apparent closer connection between the symptom and the lesion. In all, a general cerebral contusion was evident, and, as before stated, probably occasioned the mental disorder. Partial anæsthesia, irritability, and restlessness were observed in isolated cases.

In order further to test the diagnostic value of the symptoms observed in this limited number of cases, an equal number of others have been analyzed, in which, though the associated lesions were more severe, the hemorrhage was sufficiently large, absolutely and relatively, to be the source of distinguishable symptoms. They present some points of difference which naturally follow from different attendant conditions. In the larger proportion of both necropsic and operative cases, in which hemorrhage seemed to be the single source of danger, it was of epidural origin. In this group of cases, in which the brain and its membranes are more seriously involved, it is with few exceptions essentially pial or cortical. When these parts are the seat of excessive general contusion without laceration, the pial vessels are the ones to suffer rupture, and in every such instance the hemorrhage if subdural was of this character; in two it chanced to be epidural. When the brain substance is superficially

wounded, the cortical vessels are obviously most likely to be the source of hemorrhage. It is also inevitable that when life is prolonged the symptoms of hemorrhage should be often modified, superseded, or complicated by others characteristic of the additional lesion.

The temperature loses its diagnostic importance. It is generally higher than in the previous instances in which hemorrhage has been complicated. In ten cases it ranged from 105° to 107.8°, and in twenty-six it exceeded 103°. In the cases which terminated fatally within twenty-four hours, which was the usual limit of life when approximately uncomplicated hemorrhage proved fatal, the temperature was still within the limit of 101° +; in four, however, in which death occurred within even less than twelve hours, it rose to 102.2°, 103°, 106.8°, and 107.8°.

Consciousness in these cases, as in those subjected to operation, was less uniformly abolished than when death seemed to result directly from hemorrhage; yet in far the larger number its loss was primary, complete, and permanent. In some it was at first partial, but was progressive and eventually complete; in others primary unconsciousness merged in delirium; in a few instances consciousness was at first retained, only to be lost at a later period. In general, the results of this examination are confirmatory of those obtained in the study of the less complicated cases.

The condition of the pupils was less diversified than in the cases previously detailed. It was normal in about the same proportion of those in which record was made. There was much more frequent dilatation of both pupils; an equal number in which both were contracted; and consequently fewer instances in which the two presented op-

posite conditions. As before, there was no case in which one pupil was contracted without change in its fellow. When both pupils were abnormal the hemorrhage was usually bilateral, and in unilateral dilatation the hemorrhage was usually upon the corresponding side; but in neither case was the rule invariable. In two cases with normal pupils the hemorrhage, which was large in each, was epidural in one and pial in the other, and in both was associated with important lesion of the brain substance.

The pulse, perhaps under the influence of opposing forces, was, whenever registered, usually normal. It was occasionally slow or unduly frequent, and often exhibited that want of symmetry in force and fulness upon the two sides of the body which has been mentioned as occurring in different forms of intracranial injury.

The respiration was unnoted in one-third of the cases, and in many of these it was doubtless unaffected, since in the earlier observations normal conditions were unrecorded. If moderate allowance be made for such omissions, the proportion of mixed cases in which its frequency was from 18 to 24 to the minute, and in which it was without special characteristics, was from one-third to one-half; while in those in which hemorrhage was more nearly an isolated lesion it was exceptionally of normal character. The remaining cases in which it was abnormally slow or frequent were necessarily few.

The muscular system more frequently in this class of cases afforded symptomatic indications. In each instance in which an irregular excitation of functional activity was manifested by either clonic or tetanic contraction, the hemorrhage was complicated by brain laceration; in those in which muscular power was lost or held in abeyance, the

complicating lesion was general contusion. Clonic contractions were relatively frequent; general convulsions occurred in six of the mixed cases. General muscular rigidity was noted in the two classes with more nearly equal frequency. These facts are suggestive of the influence exerted by different lesions.

Since in the group of cases under consideration the hemorrhage is in each instance associated with some serious injury of the immediate seat of sensory and intellectual function, symptoms which depend upon disturbance rather than upon simple oppression of the nerve centres are to be regarded here as only indirect. Delirium, irritability, or restlessness, when of immediate occurrence and when the effusion is moderate in amount, may be considered symptoms of hemorrhage, but only in the sense that a pleuritic pain is counted a symptom of pneumonia. It is unnecessary, therefore, when direct brain injury is a recognized factor, to investigate such conditions while engaged in the study of uncomplicated hemorrhages.

In the many intracranial injuries in which hemorrhage is relatively inconsiderable, its indications will be lost in the manifestations of graver complications; and in other, and perhaps recovering cases, in which it is absolutely insignificant, it may be even devoid of symptoms.

2. Contusion.

a. General Contusion of the Brain.

Notwithstanding the very constant occurrence of diffuse contusion of the brain, it so rarely terminates fatally when uncomplicated by other structural changes that opportunity for observation of its distinctive symptoms is

much more limited than in hemorrhage. There are, however, eight cases of the appended series in which no concomitant lesion existed, or in which if present it was so trivial that it may be assumed to have had no importance in the production of symptoms. In one there was absolutely no perceptible change beyond the general contusion; in two there were also limited and non-infective thromboses of dural sinuses; in two there was a slight pial hemorrhage; in another there was a single small hemorrhage into an optic thalamus; and in the other two there was in each a trivial cortical laceration, with a correspondingly unimportant cortical hemorrhage. In all there was a more or less intense general hyperæmia, which was sometimes more strongly pronounced in some particular region, as anteriorly, posteriorly, at the base, or in one hemisphere, than elsewhere. In four cases the pia was notably engaged; in four there was well-marked or even excessive general œdema; in four, thrombosis of the minute vessels, which generally characterizes contusion, was a distinct feature. The last-mentioned condition is to be regarded as a manifestation of contusion, as it is habitually absent in the hyperæmia of idiopathic disease. In those cases in which death was long deferred, the absence of inflammatory processes was verified by microscopic examination made at the time of necropsy.

The analysis of symptoms in the eight cases is unsatisfactory. The few connecting links which measurably held together the cases of hemorrhage have no corresponding representation. There was no uniformity either in the occurrence of individual symptoms or in their course and termination. In the single one which was absolutely uncomplicated, there was no loss of consciousness

at any time till its final lapse from asthenia; in all the others it was primary, and in three was permanent. There is no other individual symptom which occurred in more than half the cases cited. The pupils were dilated, contracted, or normal; the pulse and respiration were variable. It is true that delirium and mental irritability or apathy, combined with muscular rigidity, convulsions, or some degree of paralysis, occurred in each instance save one, and in that one a profound coma from the beginning held in abeyance all mental and motor functions; but the time of their appearance and the method of their combination had no conformity to rule. Headache, persistent vomiting, and perforating ulcer of the cornea were isolated phenomena, and in one protracted case dementia preceded death. The temperature probably afforded the earliest indication of the intracranial condition. It was never subnormal on admission, and never more than moderately elevated; in five cases it was from 99° to 100°, and in two it was 101° +. Its subsequent course was in general progressive, and with one exception attained a high degree before death ensued. Recessions were observed only once or twice in two cases, which were considerably prolonged.

It is not difficult to comprehend the reasons for the diversity of symptoms, or for their irregular development, in view of the comprehensiveness of the lesion and its different degrees of intensity in different regions. The observation of the fact of regional variations is not limited to the comparatively few necropsies in which uncomplicated general contusion has been found to exist, but is even redundantly confirmed in the far greater number in which death resulted from hemorrhage, arachnitis, or

extensive laceration. It is not unusual in case of a contusion which involves the entire brain to find that its structural evidences are emphasized in one hemisphere, or in certain lobes, or in certain regions, it may be in the cortex, the basal ganglia, or elsewhere. It is not more unusual to find in a largely diffused contusion that some part, as the cortex, one hemisphere, or the cerebellum, has practically escaped. All the characteristic structural alterations are alike subject to localization. The post-mortem inspections of the brain have demonstrated also the instability of the parenchymatous serous exudation; this not only gravitates to dependent parts, but can often be freely expressed by hand after section has been made. The dropsical effusion moves through the brain substance with the same certainty, if not with the same celerity, that it does through subcutaneous cellular tissue. There is no more reason to question the fluctuation during life in the amount or position of serous transudation, or in the intensity of hyperæmia originally established by violence, than there is to doubt their often progressive increase or diminution. The punctate hemorrhages into the brain substance are, of course, not subject to change, and are less influential in the modification of symptoms than the conditions previously described.

These considerations seem sufficient to account for the wide variations noted in symptomatology. It is unnecessary to review the cases which illustrate the dependence of symptoms of cortical irritation upon cortical contusion of the vertex, or of pressure symptoms upon excessive general subcortical hyperæmia and œdema, or of various other combinations of symptoms with structural changes. It is quite possible that wider observation may further illu-

mine the invasion and march of symptoms, but, as these must continue to depend upon unstable conditions, they are not likely even then to become fixed elements in diagnosis.

Some further knowledge of the symptoms which indicate the existence of this form of cerebral injury may be gained from the observation of the very simple cases in which recovery follows without a suspicion of danger being incurred, and also from the analysis of those complicated fatal cases in which the relative value of different lesions can be estimated and their symptoms studied to some extent by the process of exclusion. The condition of contusion can be justifiably assumed in the former class from the absence of known indications of the other intracranial lesions, and in certain instances from the occurrence of similar cerebral symptoms with diffuse structural change when death results from coincident injury of the trunk or extremities. In these relatively unimportant cases there is invariably some loss of consciousness or some mental impairment. In those which are deemed too trivial to require medical attention, a momentary unconsciousness, partial or complete, or some vertigo or mental confusion, with a sense of bodily weakness, and possibly a later headache, comprise the available history. In cases of somewhat greater severity which are admitted to hospital additional symptoms are usually present. Consciousness, which may have been lost for a variable period, has been usually regained. Twenty-five cases of this nature, many of which involved simple fissure of the vertex, but without other cranial or more distant complication, and without coincident intracranial lesion so far as could be determined, were subjected to comparative ex-

amination. The temperature on admission was habitually 99° +; in the exceptional instances it was practically normal or else subnormal from shock; its later extreme elevation was 101°. The axillary temperature was not ordinarily observed, but in one typical case of contusion it was always higher upon the left than upon the right side, usually 0.6°, with a maximum of 1.8°, in a course of four daily observations extending over seventeen days. The pulse on admission was usually moderately increased in frequency, ranging from 90 to 116, but in a smaller proportion of cases was slightly below the normal standard; its later variations were within the same limits. The radial pulsations at the two wrists were sometimes unsymmetrical. The respiration was almost uniformly from 18 to 26; in three instances on admission it was from 14 to 16. In one exceptional and inexplicable case, with a temperature of 99° on admission to the hospital, the pulse was 170 and the respiration 40. The patient, a child, was removed from observation on the third day, and was then in a favorable condition; it is possible the diagnosis was not thoroughly established. The most prominent general symptoms were stupor, somnolence, headache, vertigo, irritability, and restlessness, which were never collectively manifested in a single case. Unconsciousness, or a dazed mental condition, sometimes persisted after admission, and delirium occasionally occurred. Muscular rigidity or convulsions were exceptionally noted. The pupils were usually normal, but when changed were in four cases symmetrically dilated, and in two were contracted, in one of which they were subsequently irregularly dilated, and at times normal. It often happened that not more than one or two of these sym[illegible] observed, and sometimes

after the primary and transient unconsciousness there was absolutely no indication of cerebral injury aside from the rise in temperature.

If the cerebral contusion is of maximum intensity and extent, some hemorrhage or laceration is almost inevitable. Ten cases of this character have been analyzed, in which large pial or epidural hemorrhages have coexisted with excessive or moderate hyperæmia and œdema, or with hyperæmia and punctate extravasations. They have been selected in preference to others in which lacerations existed, as likely to afford a clearer differentiation of symptoms. The loss of consciousness was primary in all, and in three in which it was permanent and profound there was no great accumulation of extravasated blood. In the larger number of cases in which an interval of consciousness intervened before its final loss, hemorrhage was more profuse; in some the relapse was sudden; and in others, in which life was more prolonged, it came at the end of a period of progressively increasing stupor. The initial temperature was often subnormal from shock, and otherwise was not higher than in the simpler cases of contusion or hemorrhage. If the patient survived the immediate effects of injury, its elevation was marked, and in these few instances its final record was from 104.2° to 106.4°. The pulse and respiration increased in frequency with the rise in temperature. The bilateral radial pulsations, as in the previous series of observations, were not always symmetrical, and the respiration at the approach of death sometimes assumed the Cheyne-Stokes character, which is not observed in hemorrhages or in the simpler forms of contusion. The pupils were normal in six of the ten cases; in two they were dilated, in one of

which an epidural, and in the other a large pial, hemorrhage occupied one of the middle fossæ; and in two they were contracted, in one of which a pial hemorrhage, and in the other pial and epidural hemorrhages, covered the left hemisphere. In both cases in which the pupils were contracted there was also loss of urinary and fæcal control, and in both the brain substance was œdematous. Psychic disturbances were infrequently manifested, even when more or less perfect consciousness was maintained for some time in the progress of the case; delirium, irritability, and restlessness were symptoms in but two instances. Disorders of the motor function were present in a larger proportion of cases, and included rigidity, convulsive movements, and full convulsions. The two cases in which general convulsions occurred involved in each a large pial hemorrhage as well as a diffused contusion; but both were susceptible of more direct explanation. In the first, in which convulsions were confined to the fifth day after injury, there was a limited contusion of a temporal lobe; in the second, in which the paroxysms were almost constant from the third hour after injury till death nine hours later, the dura was intensely congested. The relation of lesion of the temporo-frontal region of the brain to such disordered muscular action will be shown in connection with the subject of cerebral laceration. The result of irritation of the dural nerves in the production of intense

areas through the centrum ovale, it can afford no indications separable from those of a modified general lesion. In its more usual form, in which it is confined to the cortex, it differs from laceration only in the extent of local injury to tissue; and the character of the symptoms will not be farther influenced by the fact that the injury is a bruise rather than a wound. It is rarely a fatal lesion, and its existence is likely to be marked by the coexistence of others of greater magnitude or severity. It has been noted in but sixteen of the present series of necropsic examinations, and in none of these had it appreciably contributed to the fatal result, and in but two had it occasioned recognizable symptoms. In the exceptional instances there had been no reason during life to suppose that there was a limited contusion rather than a laceration.

3. Laceration of the Brain.

Cerebral laceration is always attended by some degree of general contusion; in like manner a resultant cortical or intracerebral hemorrhage proportionate to the extent of local injury, and often sufficiently large to have an intrinsic value in the development of symptoms, is almost certain to exist as a complicating condition. It is probable, however, when post-mortem indications of general injury are not pronounced, and laceration is extensive with not more than moderate cortical hemorrhage, that the significant symptoms have been derived from the local destruction of tissue. In the series of cases appended, out of the larger number in which laceration was a condition, there were fourteen or more of this character. They comprise cortical and subcortical injuries variously situ-

ated upon and beneath the several surfaces of the brain, and involve both localizing and non-localizing cerebral areas. As the location not less than the character of this lesion is matter of concern, these instances are evidently too few for generalization. Comparable cases, so far as extent of local injury is concerned, may be wholly unlike in their manifestations, as their situation may chance to trench upon different cerebral centres of control. Methods of comparison and analysis which are fairly adequate to a determination of the significance of symptoms in the different diffused lesions, even when applied to a restricted number of cases, fail when this additional factor has to be considered. The series of fourteen cases of relatively simple laceration is too much attenuated after topographical subdivision to afford a sufficient basis for deduction.

The indication of temperature must be excepted from this general statement, since it seemed to be independent of the region affected. In two instances temperature was not recorded; its course and elevation in the others may be conveniently shown in tabular form:

CASE VI.—103° on admission; 102° five hours later, and then progressive rise to 106.2° at death at end of twenty-four hours.

CASE CLXXII.—98.6° one hour after admission; 104.6° in seven hours; and 105.4° in fifteen hours.

CASE LXXXVIII.—105° before death fourteen hours after admission.

CASE XCIV.—97.6° on admission; 101.7° in nine hours; 102.8° in twelve hours; and 103° in fifteen hours.

CASE XCVII.—98° on admission; 103.2° in six hours; thirty minutes post mortem, 103.4°.

CASE CLXIV.—96° on admission, and 104.8° in one and one-half hours.

CASE XCIX.—98.4° on admission; in three hours, 103.2°; in six hours, 106.2°; and in nine hours, 109.2°.

CASE CIII.—97.6° on admission; in four hours, 103.4°; in eight hours, 100°; in eleven hours, 104.2°; in seventeen hours, 105.4°; and in eighteen hours, 109°.

CASE CVII.—97.6° on admission; in three hours, 99.6°; in six hours, 102°; in twelve hours, 104°; and in twenty-four hours, 105.2°.

The final record in each instance immediately preceded death; the post-mortem observation was frequently if not usually neglected. It is to be understood that some diffuse injury always existed, but in an exceptionally moderate degree, and was least in those cases in which the temperature attained the highest elevation. The remarkable primary rise in temperature which often followed recovery from shock, and its rapid and progressive increase, sometimes continued even after death, and in general without recession when the fatal issue was not long delayed, are in striking contrast to what has been observed in simple hemorrhages and contusions.

The symptoms which attend laceration are better studied in a review of the far larger number of cases in which limited destructive lesions are complicated by other anatomical changes, perhaps equally important. It will then

be necessary to exclude those symptoms which have been found to be referable to the complicating conditions as they have occurred elsewhere in comparative isolation.

The high temperatures which characterized simple lacerations were maintained in the presence of complications. In the sixty-five complicated cases which were analyzed, the initial observation was made immediately upon admission, but was not recorded as primary if some hours or days had elapsed after the reception of the injury; the ultimate observation was denominated final only when made nearly or quite *in articulo mortis*. Rectal temperatures only were noted. The cases of this series, which are so numerous as to be more than representative, have been selected after the exclusion of those which have served to illustrate the relatively uncomplicated hemorrhages, contusions, and lacerations, and in which no inflammatory sequela was discovered.

The primary temperature was unnoted in four cases in which admission to the hospital was deferred, was normal in two, and was subnormal in fifteen; in the remaining forty-two cases it was from 99° to 100° inclusive in sixteen, 100°+ in eight, 101°+ in eleven, 102°+ in six, 103.6° in one, and 106°–106.6° in two.

The final temperature was 109° in one case, 108°+ in four cases, 107°–107°+ in thirteen, 106°–106°+ in seven-

with no more than a single interruption, which was unimportant in degree. The progressive elevation of temperature from the time of admission, immediately after the occurrence of injury, was often exceedingly rapid, as from 94.2° to 105.4° in nine hours, from 98° to 106.6° in nine and one-half hours, from 97.6° to 107° in fifteen hours, from 97.2° to 105.2° in nineteen hours, and from 102.6° to 106° in five hours. An approximately rapid but less remarkable rise in temperature not infrequently marked the last hours of life. In one instance the primary progressive elevation was followed by a depression to 97°+, which persisted nearly a week before the advance of temperature was resumed.

These extreme elevations of temperature have been often coincident with lesions which have involved what have been described as thermogenetic centres, and rather noticeably that part situated near the antero-inferior aspect of the corpus striatum. It is also true, however, that laceration of any portion of the brain is followed by a high temperature; and that the regions in which these supposed centres are situated happen to be most subject to injury. It is therefore questionable how far the study of traumatism has confirmed in this regard the results of certain physiological investigations. The highest temperatures recorded, and those in which progressive increase has been most rapid, have not been confined to lacerations involving any special regions of the brain. They have indicated the extent or severity rather than the situation of the injury, and have included lesions of the frontal, temporal, parietal, and occipital lobes. If the laceration has not been large, the general hyperæmia and œdema have been excessive. It would seem probable from clinical ob-

servation that the high temperatures which attend cerebral lacerations and contusions depend upon general nutritive changes, and not upon specific lesion of the nerve centres. This view is sustained by the history of cases in which no limited lesion existed. In one of these, in which the rise in temperature was phenomenal, there was a large epidural hemorrhage, compressing the brain, and a moderate general hyperæmia with an excessive œdema, which equally involved all parts of the viscus, but no localized injury. The patient was admitted in profound shock and died one and one-half hours later. The temperature was 98.6° at the time of death and immediately afterward; in thirty minutes it had risen to 109°—, a post-mortem elevation of 10.4°. There can be no doubt that the presumed heat centres were exempt from injury, except as they suffered contusion in common with all the rest of the brain substance.

In cases of recovery the reduction of temperature from 99°+ was often very slow, and sometimes occupied many weeks.

It is still impossible to estimate the undetermined importance of bilateral variations in axillary temperatures. The observations which have been made in connection with the appended series of cases have afforded uncertain results, which have been often apparently inconsistent with each other, even in the same case. Temperature is sometimes uniform upon the two sides of the body, but is very often higher upon one than the other, which is not always the same with reference to the side of the head in which the lesion is situated. The differences have ranged from 0.2° to, in one instance, nearly 3°, and have been noted in repeated observations made daily for more than

two weeks. It may be said, with some reserve, that when a difference exists the temperature is rather more frequently 0.2° higher upon the side opposite than upon that corresponding to the seat of cerebral injury.

In a considerable number of cases the final rise in temperature was continuous for a certain time after death. In at least fifty per cent. of observations made after the lapse of thirty or sixty minutes, the post-mortem increase was from 0.2° to 2°, and was exceptionally very much greater; while in the remainder the temperature had fallen or was unchanged. The practical difficulties which prevent the collection of these data in all of a great number of cases, as in the notation of axillary variations, are readily understood. The lesions associated with the post-mortem calescence comprehend all those which have been described. The one which was most nearly constant was laceration, and even this was sometimes disproportionate to the severity of a general hyperæmia or to the amount of a cortical hemorrhage by which it was attended. In the remarkable case in the appended series, to which attention was called in a preceding paragraph and in which the temperature immediately after death was 98.6°, and within thirty minutes rose to 109°, there was no laceration; a large epidural clot compressed the left parietal and temporal lobes, and the brain substance was everywhere hyperæmic and excessively œdematous. There would seem to be little doubt that, at least in this instance, the generation of heat must have been due to post-mortem general nutritive changes rather than to continued activity of special thermogenetic centres. It has not been in general practicable to trace any connection between this phenomenon and the region of the brain affected, and it is not de-

pendent therefore upon injury of so-called heat centres. It must be accepted simply as a continuation of a thermogenetic process, however excited, or as the result of deficient thermolysis, however occasioned.

The pulse and respiration, when laceration was the essential factor in the production of symptoms, were not far removed from the normal standard. If hemorrhage coincidently compressed the medulla, respiration was even fatally retarded; or if general shock was intense, or arachnitis at once supervened upon meningeal contusion, or if various special conditions existed, both pulse and respiration, or either one, might be greatly increased in frequency; but these cases were exceptional. The contrast habitually presented by a practically normal and unaccelerated pulse and respiration, with general symptoms of perhaps great severity, seems scarcely less remarkable than the exaggerated temperatures which have been the occasion of surprise in the same series of cases. In the great majority of instances of serious intracranial injury, whether fatal or not, the pulse has not exceeded 90, or the respiration 26, upon early examination. The pulse when abnormal has oftener than otherwise inclined to fulness and slowness; and, in the absence of statistical data, a moderate diminution of frequency would seem characteristic. The respiration, on the contrary, when disturbed has been usually hastened, even though the circulation has been retarded.

The want of symmetry in radial pulsation upon opposite sides of the body, which has been noted in connection with other intracranial lesions, is also a symptom in cases of cerebral laceration. This condition was first recog-

and since then has been found to exist in from thirty to forty of the appended cases. It is most frequently a primary aberration, but may not occur until a later period in the progress of the case. It is sometimes evanescent, disappearing in a few hours, and again extends over a number of days. The bilateral variation attaches to the strength and fulness of the arterial pulse, which is in all other respects symmetrical. In one instance the fuller pulse was the more compressible; in all others it was also the stronger. The original characteristics of each radial pulse were ordinarily retained as long as a difference existed, but occasionally they were interchanged. In some of these instances the fulness and strength of pulsation upon one side were in startling contrast to its weakness and tenuity upon the opposite; in others the apparent difference was slight, and, to avoid the possibility of error, was excluded from record. In each case in which it was accepted as a symptom it was confirmed by two or more observers, and if not indisputable was rejected. Twenty-one cases in which it was observed terminated fatally, of which seventeen were subjected to necropsy. In the recovering as well as in the fatal cases which failed of post-mortem inspection, the nature of the lesions was sufficiently evident from the general indications. The necropsies disclosed all forms of hemorrhage, epidural, cortical and pial, variously situated; lacerations, more especially of the frontal and temporal, but also of the parietal lobes, and of each of the basal ganglia; and almost invariably some degree of general contusion, which was sometimes the essential lesion. There were hemorrhages without laceraton, and limited contusions without hemorrhage. The inferential lesions, those not demonstrable

by direct inspection, were somewhat less diversified They included five cases of depressed fracture of the vertex, with epidural hemorrhage and frontal laceration in one, and moderate general contusion in four; nine cases of fractured base, with probable hemorrhage in all, and with laceration or general contusion in all but one; and three cases of intracranial injury without fracture. The pulse was fuller and stronger upon the side corresponding to the seat of injury in nine cases, and upon the side opposite in thirteen; in three this relation was unknown, in one instance from imperfect clinical record, and in two others from the existence of distinct lesions upon both sides of the brain. In several of these cases a diffused contusion was well marked or even excessive.

It would seem impossible, therefore, to infer the character or location of lesions from this symptom alone; it is equally so from any correlation which exists between it and others by which it has been accompanied. The first few cases seemed to suggest a relation to the pupillary condition, which larger experience has shown to be fallacious. The pupils are dilated in a considerable number of cases, normal in an almost equal number, and contracted or asymmetrical in others.

An abnormal state of the pupils is of no greater importance in laceration than in other encephalic lesions. The forms and combinations of pupillary variation have been so numerous, and the instances in which no change has taken place have been so frequent, that no inferences of practical value can be derived either from their continued normal condition or from any changes which they may present. In the cases cited in illustration of the symptoms of comparatively simple lacerations, the pupils were un-

noted in one, normal in seven, and variously contracted and dilated in the six remaining. The examination of the much larger number of cases in which extensive laceration was complicated by other intracranial lesions, equally important, has been no less confusing and unsatisfactory. It has been impossible in either class, after the most careful analysis of cases, to trace any connection between the situation and extent of the injury and an attendant irregularity of the pupils. It is evident that pial and cortical hemorrhages in the region of the middle fossa are usually incapable of compressing the motor oculi communis nerve; and no similar explanation of pupillary contraction or dilatation, founded upon the fact of irritation or paralysis of a nerve in its course or at its centre of origin, is possible. The inconstancy of the pupillary phenomena, the varying degrees of sensitiveness to external irritation, as well as the opposing conditions of contraction and dilatation in the same case at different times, while the limited lesion, the laceration, is constant and unchanged, indicate their source in some wider structural change.

The loss of consciousness in different degrees, which characterizes diffuse general contusion, must be a symptom in cases of laceration, since the general lesion is always a complication. It was usually manifest and often long continued if not permanent in the fatal cases which were selected as typical of this form of injury; but exceptionally there was simple obscuration of the mental faculties, and in one instance the mental condition even remained unimpaired. There is no reason to suppose that unconsciousness is ordinarily a direct result of the laceration; but it is not demonstrable, as it was in case of hemorrhages, that the suspension of consciousness when pri-

mary is necessarily due to the accompanying general contusion, because, unlike hemorrhage, laceration is also an instantaneous lesion. If, however, regard is had to the usual small extent of a laceration, as compared with the wide diffusion of the contusion, it seems the less probable explanation in the majority of cases. If the laceration involves a large amount of tissue, it may be sufficient in itself at once to suspend consciousness; it then approaches diffused contusion in the greater area affected, and in the severity of the psychic shock which it occasions. The unconsciousness attributable to the limited lesion would indicate an injury of great severity, and might, therefore, be expected to be profound and probably protracted or permanent. If life is prolonged, the immediate morbid condition will be replaced or supplemented after a variable period by characteristic symptoms. In cases in which consciousness has been retained from the first, the mental condition is often peculiar; it is not that of partial consciousness or of absolute stupor, but of blunted perception. The patient seems lethargic, but can be aroused without great difficulty, and apparently comprehends simple questions in a dull way and with effort, though the effort is quite likely to fall short of compassing an answer; he feels and sees and is capable of effort, but scarcely thinks. From this condition he may immediately pass through somnolence or complete unconsciousness into coma and death, or he may at once regain his mental equilibrium. In a considerable number of instances, in place of this direct solution of a psychical problem, a new series of mental phenomena are interposed between the primary loss of consciousness or the condition of lethargy mentioned and ultimate recovery or death. In a typical case delirium of

some grade or character follows or precedes restoration to consciousness; it may be violent and simulate the alcoholic form of mania, but oftener the patient is simply restless, excitable, incoherent, or perhaps inarticulate in speech, his mind distracted by fleeting fancies, yet amenable to control. A little later he may recognize his friends, converse intelligently and coherently, and during the day and upon cursory examination appear quite rational, though he is still delirious and requiring mechanical restraint at night. He has delusions, fixed or transitory, and his memory is defective or entirely wanting in regard to circumstances or occurrences which preceded his restoration to consciousness. He has often no knowledge of his place of residence, occupation, or family; but, whatever else he may remember or forget, he is absolutely oblivious of all the circumstances attending his injury, and he has no apprehension of his present surroundings. His nocturnal delirium may soon disappear and eventually after the lapse of weeks or even months, his mind may become clear, his memory be restored, and his recovery be complete. In a certain proportion of similar cases the termination is less fortunate, and some degree of permanent dementia remains. In many others the mental horizon never brightens after the inception of delirium, or, if at all, for a brief time only, and death is not long delayed. In another type of mental disorder a condition of apathy follows active delirium, and is likely to be merged in final unconsciousness. In still other cases delirium is of a muttering character from an early stage, and is accompanied by stupor. Certain of these psychical symptoms will be found hereafter to depend upon laceration of a definite cerebral region.

There is often a want of correspondence observed between the severity or mildness of the invasive psychical symptoms and the final outcome of the injury. A violent commencement has not always involved an answerable sequestration, and so, too, a good beginning has sometimes made a very bad ending; but in either instance failure to forecast the future does not imply inability to recognize pregnant symptoms. The existence of the lesion may be as legibly stamped upon the histories of such cases as upon those which have run a more conventional course.

There is a peculiar irritability or sensitiveness to external impressions which is sometimes observed as a result of cortical injury. It is an exaggerated response to trivial irritations and disturbances, which seems due, less to a hyperæsthesia of the cutaneous or other sensitive surfaces, than to an abnormal excitability of the emotional centres. Great vexation and impatience are often manifested from slight irritation, even in the last hours of life, when the patient has remained otherwise motionless and apparently unconscious for a length of time.

These varied manifestations of mental disorder, while occasionally indicative of cerebral contusion, are more characteristic of laceration. Delirium and stupor, like loss of consciousness, are to be referred to the diffused rather than to the limited lesion; but the other conditions of intellectual aberration and decadence as a result of traumatism are almost exceptional, unless there has been

Chapter III.

SYMPTOMATOLOGY—*Continued.*

THE symptoms of contusion or laceration up to this point have been studied without reference to their relation to areas of functional control. The peculiarities of the pulse, temperature, and respiration, the variations of the pupils, the loss of consciousness, the event of stupor, or the access of delirium, have been found to be dependent upon the nature of the lesion apparently uninfluenced by its situation. An examination in detail of the many cases in the appended series, in which laceration has occurred in different regions of the brain, affords some reason to believe that purely intellectual and emotionl disorders can be directly connected with the localization of the injury in a part even more restricted than might be supposed from the results of physiological experiment. The number of cases collated is large, and their histories are sufficiently complete to give value to whatever conclusions may be justifiable from their analysis. No part of the brain has been so frequently involved in these cases of fatal injury as the frontal lobes, the region in which physiologists have located the control of the intellectual faculties. The influence of direct frontal injury upon the integrity of thought and its manifestations confirms the correctness and accuracy of this localization.

The series of two hundred and twenty-five necropsies includes seventy-two instances of laceration of one or both frontal lobes, exclusive of those pistol-shot wounds in

which almost instantaneous death precluded history. In thirty-three of these cases morbid mental conditions had been inappreciable by reason of primary and permanent unconsciousness; and in eleven others an early fatal issue, preceded by only partial consciousness or the existence of delirium from the general cortical lesion, made the recognition of indications of the local injury equally impossible. Twenty-eight cases remain, in which the attendant conditions permit an estimate of the direct results of frontal lesion. These comprise:

Laceration of the left frontal lobe, . .	11
" " " right " " . .	7
" " both frontal lobes, . .	10—28

I. Laceration of the Left Frontal Lobe.

1. Stupor with incoherence preceded delirium on the second day. Lesion confined to cortex of the inferior surface.

2. Patient sent to an asylum for the insane on the eighth day, with delusions and other manifestations of mental aberration. Lesion confined to cortex of the inferior surface.

3. Delusions on the third day. Lesion confined to cortex of the inferior surface.

4. Sensory aphasia and mental aberration on the first day. Laceration of greater part of the inferior surface; also of the first and second left temporal convolutions.

5. Mental decadence with mild delirium till death on the fourteenth day. Extensive laceration of the antero-superior and inferior surfaces.

6. No primary loss of consciousness, but inability of comprehension. Excavation of greater part of the lobe.

7. Mental aberration and delusions till the thirteenth day, and afterward stupor. Excavation of prefrontal region, with an extension of clot to the posterior border of the lobe.

8. Constant mild delirium with an entire lack of comprehension of surrounding conditions. Small central laceration posteriorly.

9. Ability to answer only a limited number of questions correctly, and answers mainly ejaculatory. Subcortical laceration, one and one-half inches by three-fourths of an inch in diameter, in anterior region.

10. Delusions on the fourth day, delirium at night. Laceration of the inferior surface.

11. Stupor, lack of attention and of power of comprehension; delirium at night. Laceration of inferior surface.

II. Laceration of the Right Frontal Lobe.

1. Primary unconsciousness lasting a few hours. Mental condition then normal till sudden recurrence of coma on the seventh day. Laceration of the inferior surface.

2. No symptoms of mental disorder till the occurrence of violent delirium on the second day. Subcortical laceration in middle portion of the lobe, with rupture of the inferior surface.

3. Transient and partial primary loss of consciousness; no other mental disorder till final coma. Deep laceration of superior surface, extending nearly to lateral ventricle.

4. Mental condition normal for first twelve hours;

then convulsions, unconsciousness, and delirium. Excavation of inferior and outer part of the lobe; cavity as large as a pigeon's egg.

5. Mental condition normal for several hours; then a single convulsion, followed by stupor and delirium, which continued till the eleventh day; some questions intelligently answered in an interval before the occurrence of final coma. Excavation of inferior portion of prefrontal region.

6. Mental condition normal till second day; later meningitis. Laceration of inferior surface.

7. Mental condition normal till death at end of thirty-three days. Pistol-shot wound. Previous melancholia continued.

III. Laceration of Both Frontal Lobes.

1. Stupor during first three days; mental condition apparently normal on the fourth day; later, stupor, convulsions, and coma. Laceration of inferior surfaces.

2. Mental condition normal on second day; patient apathetic on sixth and seventh days; final coma on the eighth day. Subcortical disintegration of both lobes.

3. A fixed delusion conceived on the second day continued till death in the fourth week; other delusions which were transient. Laceration of the inferior surface of the left lobe, extending through and below the cortex and across the median line.

4. Delusions and loss of memory for five days; mental condition normal on the sixth day; later progressive mental impairment till death at end of the fourth week. Multiple laceration of the superior left prefrontal region and

limited contusion. Slight laceration of the external surface of the right lobe.

5. Apathy, rambling speech, and delusions in the fourth week, which continued till death, two weeks later. Laceration of inferior surface of each lobe.

6. Mental condition apathetic in an unusual degree, but rational. Death on the thirteenth day. Pistol-shot wound through central frontal region.

7. Patient irrational, but not delirious. Death on the second day. Laceration of inferior surface of each lobe.

8. Mental condition normal for two hours, when final stupor and coma supervened. Disintegration of anterior half of left, and of whole of right, inferior surface.

9. Primary mental aberration, delusions on the second day; later, meningitis. Lacerations of the inferior surface of each lobe; two upon the left lobe extending through the cortex; those of the right side smaller and more superficial.

10. Patient not under observation till two days after injury, and was then semi-conscious; when aroused, mental processes slow; later, progressive stupor and coma. Disintegration of both prefrontal regions from pistol-shot wound.

The cases to which reference is made have been otherwise described in their general histories, which are included in the appended series. The associated lesions have been here disregarded in each instance as not related to the present matter of inquiry. In the eleven cases in which frontal laceration was confined to the left lobe, there was mental aberration or deficiency, apart from mere stupor or delirium, in every one; while in the seven in which laceration was confined to the right lobe, it was

observed in none. In the ten cases in which frontal laceration involved both lobes, and in which specific mental disturbance might be expected from the implication of the left, it was observed in eight; in one of the two in which the mental condition had not thus indicated the seat and nature of the lesion, only two hours had elapsed before the supervention of final coma; in the other, there is no reason apparent in the history for its exemption from the mental disorder common to all the others in which lesion of the left lobe existed. It is possible that more careful study of symptoms might have brought the exceptional case within the control of what seems to be a general law of relationship between a very limited region of the brain and the manifestation of the higher psychical phenomena. In view of the rapid progress made in many instances toward a fatal issue, and of the brief and imperfect opportunities afforded in others for the appreciation of mental peculiarities, the results of analyses of individual cases are remarkably consistent with each other and point to a highly probable if not positive conclusion. The notation of histories was made in the greater part of this group of cases before it was suspected that a direct relation existed between destructive lesions of the left frontal lobe and special intellectual disorders disconnected with general disturbances or default. If observations have been recorded in less detail than might have been expected, had a definite purpose been held in view, they at least escape the imputation of having been even unconsciously colored by preconceived opinion.

The lacerations were not always of the same character, situation, or extent. All but one involved the anterior region of the lobe. Thirteen had led to a more or less com-

plete disintegration, either directly or as an effect of hemorrhage. Thirteen of the cortical injuries were confined to the base, and the two others were wholly or in part upon the antero-superior surface. The lesions were cortical and subcortical in case of either lobe, and when both lobes were implicated the dual injuries were usually of the same character. The symptoms held some relation to the situation and extent of the lesion. In the subcortical excavations and disintegrations, there was abrogation of mental power rather than aberration in its manifestations, the patient's condition being sluggish and apathetic. In the cortical lacerations, in place of apparent default of intelligence, there were perverted memory, lack of attention and control, incoherence, delusions, or the stupor which comes from confusion rather than paucity of ideas; the mind was alert to external impressions, though they were not always rightly comprehended. These distinctions which are general are by no means absolute. The localizing symptoms would be naturally less pronounced or absent in cases in which the frontal lesion was trivial, or in which from the severity of the local injury death occurred at an early period, though this did not always prove to be the fact. If recovery ensued, the longer duration of symptoms should increase the probability of determining with certainty the presence or absence of specific mental disorder. This is exemplified in several of the appended histories, in some of which the exact frontal lesion was well assured or positively ascertained.

The converse proposition, that laceration of the left frontal lobe is the sole traumatic lesion which occasions a direct loss or derangement of intellectual function, is, so far as can be judged from a study of the same series of

cases, only a little less absolutely true. In the two hundred and twenty-five necropsies, death had been preceded by such deficiency or derangement in four instances in which this injury was not disclosed. In one of these, a case of pistol-shot wound of a parietal lobe, some slowness of comprehension was added to a hysterical melancholia which had led to a suicidal attempt; this may be properly excluded, as mental disease existed before the reception of injury. In each of the other three, mental decadence was evident; in two, general hyperæmia and œdema were excessive, and in the third a large localized subarachnoid serous effusion compressed the frontal lobes. These exceptional cases are scarcely more than two per cent. of the whole number of intracranial injuries, verified by necropsy, in which the frontal lobes were not the seat of destructive injury; and in them the frontal lobes, though not wounded, were in one instance the parts solely affected by a limited lesion, and in the other two were included in a general lesion of excessive severity. There were no instances in which a laceration of any other cerebral region was attended by characteristic mental changes.

The differences in symptoms as the right or the left frontal lobe is the seat of laceration are further exemplified in the histories of pistol-shot wounds of the brain. The whole number of cases which have been heretofore reported from English and American sources during the years 1879 to 1895 inclusive is probably not more than one-hundred and fifty, of which it has been possible to collate for the present purpose one hundred and ten. Fifty-eight of this number involved the frontal lobes; twenty-six of these were limited to the right, and twenty-four to the left lobe; eight included both lobes. The cases which ter-

minated in recovery, and on that account probably deemed most worthy of record, were in large proportion; and in them the situation of the lesion was made certain by the use of the probe, by operation for the removal of the ball, or by the appearance of brain matter at the surface. Not one of the twenty-six cases in which the cerebral wound was confined to the right side presented at any time any symptom of mental or emotional disturbance, aside from the stupor or delirium which is characteristic of general contusion. In thirty-two cases the ball traversed the left frontal lobe, in eight of which there are no means of determining the mental condition, the loss of consciousness having been permanent, or the general symptoms entirely unnoted. In thirteen of those remaining, manifestations of mental derangement were distinctly evident. In several of the others the mental condition was not specifically mentioned and the histories were otherwise deficient. There are still a limited number of cases in which with a wound of the left lobe the mind was apparently unimpaired; some of these are stated to have exhibited some form or degree of aphasia, and in nearly or quite all of them the lesion was of the posterior part of the lobe. The series of cases as a whole seems to justify the conclusion that pistol-shot wounds, a class of injuries in which lesion is more strictly localized than in others and consequently well suited to purposes of inductive study, indicate that intellectual and emotional derangements are symptomatic not only of lesion of the left frontal lobe but also of its anterior and central portions. It is also noticeable that in cases of general traumatism the injuries when superficial were usually upon the inferior surface, which has been classed as a latent area.

In summarizing the results of this examination of a series of one hundred and thirty cases of wound of the frontal lobes it appears:

1. That in nearly every instance in which consciousness was retained or regained, and the mental faculties were not perverted by general delirium, laceration involving the left lobe was attended by default of intellectual control, and that the lesion was usually of the anterior region and implicated its inferior surface. Subcortical disintegration was characterized by abrogation of mental power, and superficial laceration by aberration in its manifestations.

2. That in every instance in which laceration was confined to the right lobe the mental faculties remained unaffected, except as they were obscured by stupor or delirium occasioned by coincident general lesion.

3. That compression or contusion of the left lobe only exceptionally produced specific intellectual disturbances. This generalization is based upon an examination of the entire series of one hundred and thirty cases, in which the history was confirmed by necropsy.

There are other symptoms due to cerebral laceration, which, like those connected with the mental condition, indicate with comparative certainty the situation as well as the nature of the lesion. These are mainly though not exclusively disorders of the motor function. It is conceded that a motor zone contiguous to the Rolandic fissure in the human brain, and analogous to a similar area experimentally demonstrated by comparative physiologists, has been verified by many observations of the effects of both idiopathic and traumatic lesions. This is illustrated also in the present series of cases, but in a relatively small proportion of their whole number, since violence, even

when inflicted at the vertex, is so generally transmitted to the base, where its limited destructive effect is exerted, that the motor region is likely to escape injury. The nature of the paralyses which follow the implication of the several centres of control in this area, and their symptomatic significance, are too well understood to require more specific mention.

Not only abrogation or abridgment of muscular power, but muscular incoördination may point to the situation as well as to the fact of cerebral laceration. The occurrence in this way of motor aphasia from lesion of the third left frontal convolution, or of agraphia from lesion of some connected area, are among the unquestioned results of traumatism. It is doubtful if ataxia is ever occasioned by cerebellar laceration. It was observed in no instance in the appended series of cases in which this lesion existed, and it is probable that no injury of this part can occur sufficiently extensive to produce characteristic symptoms, without complicating conditions in which they must necessarily be lost.

The occurrence of clonic contractions or of tetanic spasm, either general or limited, is also symptomatic of cerebral laceration and to some extent indicative of the region involved. The value of these muscular disturbances as a general and localizing indication may be estimated from a statistical view of the cases of the appended series in which they have been observed and the attendant post-mortem conditions noted. There were thirty instances of general or unilateral convulsions, which in twenty-seven resulted from cerebral laceration, and this in twenty was upon the right side of the brain. The temporal lobes were involved in twelve cases, the frontal in nine, the

optic thalami in five, and the cerebellum or corpora striata in the other four. The laceration was not often, though occasionally, confined to a single lobe. In the great majority of cases the essential lesion was in the temporal or frontal region and might be cortical or subcortical, and when cortical was somewhat oftener than otherwise upon the inferior surface. There were twenty-three cases in which minor local or general convulsive movements occurred, fifteen of which attended laceration of the frontal or temporal region. There was no constant relation between the situation of the lesion and the side upon which spasmodic movements were produced, or between its occurrence upon one or both sides of the brain and their unilateral or bilateral character. There were twenty-eight cases in which muscular rigidity was a symptom; it was general in ten, in eight of which there was frontal or temporal laceration, and it was limited in eighteen, with similar laceration in seven, and of a corpus striatum in one. There were thus eighty-one cases, or more than one-third of all those subjected to post-mortem examination, in which some form of disordered muscular function was a symptom; and of these, in fifty-eight there was cerebral laceration, in fifty-one of which it was essentially of the frontal or temporal lobes. It will be further observed that the probability of fronto-temporal laceration increases with the severity of the muscular disturbance. General or unilateral convulsions depended upon laceration in twenty-seven of the thirty cases, and in twenty-one this was of the frontal or temporal lobes, or of both together; simple muscular rigidity was associated with laceration in scarcely more than half the cases in which it occurred. The exceptional dependence of convulsive movements

upon hemorrhage or meningeal effusions may be properly deferred to a later consideration of diagnosis.

The more inaccessible regions of the brain are not exempt from destructive alteration, but distinctive symptoms have not been separable from those of associated lesions. In seven cases of laceration and limited contusion of the corpora striata, varying from a minute extravasation to complete disintegration, the most constant symptom was morbid muscular contraction, which was absent in only one, that of a pistol-shot wound with death before reaction. In each there were complications sufficient to account for the disordered muscular action, as a frontal or parietal laceration, a hemorrhage, or dural wounds. In four the lesion extended to the optic thalamus. Complicating laceration failed but once, and was replaced by a pial hemorrhage. The temperature scarcely exceeded 102°; in a case of complete disintegration of the right and much laceration of the left corpus striatum, it rose in the eight hours which preceded death only to 102.2°. In the one instance in which it attained a considerable elevation, the lesion was insignificant. Paralysis was never observed.

In the seven cases in which an optic thalamus was lacerated without lesion of the corpus striatum, there were general convulsions in four, opposite unilateral convulsions following muscular rigidity in two, and convulsive movements of the arms in the seventh. The temperature was higher, rising to 107°+, 107°, 105°+, 103° and 102°+. The complications in four were extensive; a relatively large extravasation into the pons, a deep laceration of the frontal lobe, and a large cortical hemorrhage, in one; cortical laceration of the frontal and a wide and deep laceration of the temporal lobe in the second; pial hemor-

rhage in the third; and an excessive cerebral œdema in the fourth. In the case last mentioned there were a noticeable weakness of the muscles of the trunk, post-cervical muscular rigidity as well as general convulsions, loss of fæcal and urinary control, and marked mental decadence, though there were no hemorrhages and no lacerations. The fifth case was remarkable, both from the severity of the lesions of the thalami and from the fact of their comparative isolation. The left thalamus was much contused in the anterior portion of its inner surface, and the right thalamus extensively lacerated upon its superior surface. There were contusion of the fornix anteriorly with punctate extravasations, a small clot not larger than a filbert in the centre of the left cerebellum, and a moderate general contusion. The disorders of muscular action were confined to the left side; there were temporary rigidity upon admission, which was relieved by the elevation of a depressed osseous fragment, violent unilateral convulsions on the second day, continuing for three hours, and later permanent rigidity. The temperature in the last twenty-four hours of life ranged from 105°+ to 107°.

There were two instances of laceration of the fornix, one in its anterior and the other in its posterior portion, neither of which was of great extent. In the first, which complicated frontal laceration and general contusion, the prominent symptoms were delirium and mental enfeeblement, with high temperatures. In the second, in which copious subarachnoid, ventricular, and parenchymatous serous effusions were notable complications, the unusual feature in the case was the extraordinary variations in both axillary and rectal temperatures.

Lacerations of the gyrus fornicatus occurred in three

cases, in one of which it was trivial; in a second, implicating its anterior portion and incidental to severe laceration of the left frontal lobe, there was temporary anæsthesia of the right upper extremity; and in the third, which was independent and situated in the middle third of the convolution, general sensation was markedly diminished on the fourth and last day of life.

There were five cases in which laceration with extravasation occurred in the substance of the pons. The lesion in each was limited, the largest clot not exceeding the size of a pea. There were no disturbances of muscular action, except in one previously mentioned as complicating thalamic laceration, and death was occasioned by cortical or meningeal hemorrhage.

This series of limited lesions of the deeper portions of the brain is too restricted in number, and the complications are too serious, to justify any inferences as to the existence of distinctive topical symptoms. The injuries of the corpora striata and optic thalami seemed to be attended in almost every instance by some muscular disorder and an elevation of temperature, which in case of the optic thalami was pronounced; and lacerations of the fornix by a diminution of ordinary sensibility; but these indications even if invariable still fail of a definite localizing value.

There is still a pathic condition to be considered, which is at once indicative of the existence of laceration and of its situation. Sensory aphasia has been satisfactorily determined by neurologists to depend, in idiopathic disease, upon lesion of the lower parietal and upper temporal regions, or, more definitely, of the first temporal and supramarginal convolutions and angular gyrus. The traumatic destruction of the same parts must necessarily lead to the

same results. It is somewhat remarkable that, while the disturbances of speech have not been infrequent in the recovering cases, the appended series has afforded but a single example among those which were fatal. In this one instance, which was characteristic, the first left temporal convolution was lacerated through the whole thickness of the cortex, for a length of one and a half inches, which included the second and part of its third fifths, estimated from its anterior extremity, and in its middle portion the laceration involved the second convolution. This injury was limited to the exact width of the two convolutions, and was covered by the unruptured arachnoid membrane. Smaller lacerations existed at the tip and upon the inferior surface of this lobe, and at the tip of the right lobe. In the remaining cases, seventy-five or more in number, in which the temporal lobes were lacerated, there were twenty-five in which the external surface, which includes centres of speech, was affected; in fourteen of these, primary and permanent unconsciousness precluded the recognition of possible impairments of this faculty in any of its elements; in ten in which the retention or the return of consciousness permitted the exercise of speech, the position and extent of the lesion in each was thus determined:

1. External border—small—left.
2. External surface—small—left.
3. Middle of first convolution—right.
4. Middle of second convolution—left.
5. Anterior one-fourth of second convolution—left.
6. Posterior part of third convolution—small—left.
7. Posterior one-third of first and second convolution—right.

8. Anterior extremity of first and second and middle of first convolutions—left.

9. Nearly the whole of second and third, and a little of first convolutions—atrophy and induration of the whole lobe—right.

10. Complete subcortical excavation—left.

There were in addition two cases of limited contusion.

1. Posterior part of first, second, and third convolutions, covering an area of one square inch—yellowish in color and studded with hard punctate extravasations—right.

2. Middle portion of first convolution and adjacent parietal region—dark cortical discoloration and punctate extravasations—left.

There were no aphasic conditions in any of these lacerations or contusions, which in view of exceptional cases include those of the right as well as of the left side. It would seem from these instances that absolute destruction of tissue within the whole of an exactly limited area is essential to specific impairments of speech; and that subcortical disintegration, however complete in extent or degree, or alteration of cortical structure by limited contusion, however exact in its conformation to the limits of the centre of control, is insufficient. The comparative frequency of some form of aphasia in recovering cases is a probable result of general rather than of local lesion. An examination of the history of such cases will usually point to the existence of general contusion, and the often early as well as perfect restoration of function indicates circulatory disturbance rather than structural alteration.

There was no appreciable default or disorder of the special senses in any of the temporal lacerations, though the supposed auditory, olfactory, and gustatory centres

were sometimes involved. In certain recovering cases there seemed reason to believe that occasional defects of hearing, smell, or taste were due to central lesion. The occipital visual area was rarely the seat of limited injury.

The conjugate deviation of the head and eyes, or of the eyes alone, when observed in traumatic cases is not indicative of a lesion such as might naturally be expected from the result of experimentation; nor has it been associated with the conditions which have been recognized in idiopathic disease. The experimental destruction of the posterior portion of a frontal lobe occasions temporary deviation to the corresponding side, and its irritation a deviation in the opposite direction. In cases of acccidental injury in which this symptom has occurred the lesions have been varied, but in no instance have included posterior frontal laceration. Idiopathically it occurs in connection with epileptic seizures; and, when paralytic, with more general paralysis caused by hemorrhage. In the comparatively few instances in which it was noted in the appended series, no other considerable paralysis existed, and when death resulted, as it usually did, the lesion was found to be indifferently a general contusion with œdema, laceration, meningitis, or some form or degree of hemorrhage; and almost invariably different lesions were so complicated with each other as to render impossible the identification of either one as the direct cause of the symptom. The exact manner of implication of the nerve nucleus is not evident. The prominent associated condition was a profound unconsciousness, and the essential lesion was oftener general than limited. In a minor number of cases recovery ensued, and in them consciousness was not lost.

The enumeration of symptoms may be ended with one

of the most important of the general indications, the loss of control over the action of the bladder and rectum. It is impossible to estimate its numerical frequency, for, if these receptacles are empty at the time the brain injury is inflicted, and if, as often happens in recorded cases, life is afterward measured by hours or perhaps by minutes, this diagnostic point is necessarily lost. If such explicable cases are excluded, it may be said to be very generally observed as a symptom of laceration. It has been as often noted in the absence of any form of paralysis as otherwise, and when consciousness has been retained; and though some form of mental impairment may have always coexisted, the same loss or aberration of mental power when due to other lesions has not been characterized by this particular functional incapacity. The lacerations have been both cortical and subcortical, and have involved all the lobes and all regions of the brain, so that the direct cause of this lack of control would seem to be any wound of the cerebral parenchyma, whether or not it may be ultimately traced to some special centre.

* * * * *

The direct symptoms of intracranial traumatism have been described as they occur in fatal cases, and as they have been verified by necropsic examination; they have been in the main disregarded as they are manifest in recovering cases, in which positive evidence of the pathogenic conditions upon which they depend is usually wanting. It is probable that no esential differences in symptomatology exist, except in degree, and in many instances the early progress of the case is not at all indicative of the final result. There is no symptom which occurs in fatal cases which may not be noted in those destined to a more

favorable termination, unless it may be the infrequency of respiration which follows compression of the medulla, and none less characteristically present, except an extreme elevation of temperature. Even in temperature the distinction is not absolute; not only in the beginning but for many days it may be higher in a recovering case than in one which is to end in death, but in general its range is less, and it has rarely attained and never exceeded a limit of 105°, as it has been observed in the series of five hundred cases upon which these conclusions have been based. The direct results of lesion in all cases, whatever the final issue, are shock, circulatory disturbance, and possible sepsis; and their manifestations will present no more radical differences than obtain in other types of disease.

In illustration of those cases in which the significance of symptoms has not been demonstrated by a later inspection of pathogenic lesions, the histories of a certain number have been condensed and added to the appended series of those in which death was followed by necropsy. These instances have been selected with the intent of showing with recovery all the symptoms and pathic conditions which in another class have been connected with the causative structural alterations.

Secondary Inflammations.

1. *Arachnitis.*

The inflammatory sequela of meningeal contusion is usually known as meningitis or leptomeningitis. The exception suggested in the previous study of pathology to the ordinary classification of intracranial hemorrhages, that the terms are not sufficiently distinctive, is to be taken to these designations. The occasional implication of the

dura mater in a suppurative process extending from a neglected external wound through a cranial fracture, or its farther extension to the deeper structures, constituting a general meningitis, is distinct from this other and not always infective process which originates in the parts to which it is confined; nor is this a dual affection of the pial and arachnoid membranes, to be called, for some fantastic reason, leptoid, but a simple arachnoid inflammation or arachnitis. Its phenomena, as previously explained, are manifested in the substance of the pia mater, and not upon the arachnoid surface, as in other serous inflammations, by reason of an exceptional looseness of the subserous attachment. The exudations in pleurisy or peritonitis occur within the pleural or peritoneal cavity, rather than upon the visceral or the parietal surface, because it is in the direction of least resistance.

It is difficult to estimate the frequency of the occurrence of traumatic arachnitis. There are many instances in which some localized point of contusion becomes the seat of an equally limited inflammation which can have no appreciable influence either on the course of symptoms or on the termination of the case; and there are many others in which it is of somewhat larger extent, but in which the influence it has exerted is at least doubtful. There are others still in which, though the serous effusion is abundant and the membrane even more or less opaque, the fact that death came before the establishment of reaction negatives the possibility of an inflammatory origin. If cases be disregarded in which the existence of meningeal inflammation is questionable or apparently unimportant, there are but eighteen in the appended general series in which the lesion was positive and at the same time suffi-

ciently extensive to be influential in compassing the final result. There are nine in which the effusion was purulent or sero-purulent, and nine in which it was sero-fibrinous. In several there was neither external wound nor cranial fracture. They are too few in number for wide generalization in symptomatology, but the results obtained from their analysis are so generally confirmed by comparison with such facts as may be gleaned from the general field of traumatic arachnitis that they may be considered typical.

The invasion is uncertain as to time and character, and the subsequent course of symptoms is irregular. The antecedent and coexistent lesions, with the exception of the meningeal contusion upon which it directly depends, have no obvious relation to the development of the inflammatory process. It is probable that infection when it occurs will be early, but not of necessity primary; and that non-infective cases will be oftener late, and in the usual course of idiopathic secondary serous inflammations in prolonged disease, with the added predisposition derived from the antecedent contusion. The invasion of a traumatic arachnitis is often immediate and is sometimes deferred till the third or fourth week, but is more frequent from the second to the fourteenth days. The initial symptoms, when the inflammation is of low grade, are occasionally so insidious as to fail of recognition, but in general are sharply defined. In the larger number of cases, those which may be considered typical, the course of symptoms referable to antecedent and complicating lesions is interrupted by a distinct and somewhat sudden rise in temperature, accompanied by an evident change in the general condition of the patient, who becomes irritable, restless, delirious, or somnolent. Active delirium, when not al-

ready existent as the result of cerebral contusion, is usually the first general manifestation of the access of meningeal inflammation. The occurrence of an invasive chill is exceptional, and when it occurs it is not necessarily indicative of an effusion of purulent character. The subsequent course of temperature is erratic. It is often marked by irregular variations from day to day and from hour to hour, not usual in case of other intracranial lesions. The irregularity and extent of the thermal changes, which may exceed 4° within each twenty-four hours, are characteristic. The dependence of these fluctuations upon a secondary implication of thermotaxic centres situated in the cerebral cortex, as has been suggested, may be worthy of consideration when the existence of such centres has been better established. In rapidly progressive cases of marked intensity, the recessions do not occur. The rise in temperature which indicates the supervention of an arachnitis in a case of intracranial injury is usually distinct and sometimes abrupt, it may be to the extent of 4° or 5° or even 6° in a few hours. The average temperature, notwithstanding its recessions, is afterward high, attaining elevations of 103° to 107°+ and *in articulo mortis* ranging from 105°+ to 109°. The association of other grave structural alterations is so constant that it is difficult to demonstrate the exact relations of temperature, but the sudden primary rise is unmistakable, and the observation of both fatal and recovering cases in which minimum complications existed has made the subsequent range and the often characteristic irregular variations sufficiently well assured. The occasional excessive final temperature is probably always to be ascribed, at least in part, to concomitant laceration.

After the invasion, and aside from peculiarities of tem-

perature, the progress of the disease is especially characterized by continued manifestations of cortical irritation. Some grade of delirium persists in almost every case, and restlessness, irritability, or extreme sensitiveness to external impressions is often marked long after consciousness has been finally lost. General or post-cervical muscular rigidity, muscular twitching, limited or slight general convulsive movements, are further indications of nervous excitation. The occurrence of chill, which is an unusual invasive symptom, is not frequent at a later period. Headache is always in evidence, when the mental condition of the patient will permit its recognition. Additional symptoms have little value. The pupils are oftener normal than otherwise, and the pulse and respiration fail to reflect in the larger proportion of cases the existing inflammatory process. In many instances the want of correspondence between the pulse or respiration and the temperature may be ascribed to the influence of complicating lesions, but it is equally observed in others in which only a moderate cerebral contusion and no laceration exist, and in which the inflammation is of the highest grade. It cannot be said that in a majority of cases there is any sharp contrast in symptoms which indicates the character of the effusion. A copious purulent formation may be indicated by high pulse and temperature and active delirium without an invasive chill, or may be preceded by a chill and accompanied by asthenic symptoms; it may be insidious in its progress, as an essentially serous effusion may be distinctly evident and of easy recognition. In a minor number of cases the symptoms are commensurate with the character of the inflammation. The duration of the disease, like its period of invasion, is uncertain, and may be for days or weeks. Its

termination, when fatal, is in asthenia rather than in coma as the result of pressure.

It is unfortunate that the greater number of the cases of traumatic arachnitis which have been reported fail in the detail essential to useful generalization. It has been possible, however, to supplement the eighteen cases included in the appended series of intracranial lesions by another collection of eight heretofore unpublished cases, all of purulent and infective character, though not all of traumatic origin. These exhibit the same irregular fluctuations of temperature and varied manifestations of cortical irritation which have been described. The results which have been obtained from the aggregation of the two series afford sufficient evidence to warrant the conclusion that these peculiarities, together with a more or less decided change in symptomatology at its inception, indicate the intercurrence of arachnoid inflammation in a case of intracranial injuy.

2. *Abscess.*

Intracranial or cerebral abscess has been described as of two varieties, as it occurs upon the surface or deep in the substance of the brain. The first, which follows neglected compound fracture, may be properly excluded from consideration. It affords no question of diagnosis, since the pyogenic process involves alike the cerebral surface, the membranes, and the cutaneous wound; and if not open to direct visual inspection, or manifest through the existence of a fistulous canal, it will be necessarily disclosed in the exploration of the infected external parts. It is an almost impossible condition when the wound has received sufficiently early and intelligent aseptic care.

In the great majority of cases in which abscess is encountered by the surgeon it has received no previous attention by reason of the stupidity of the patient and his friends, who in the absence of primary general symptoms have regarded the injury as trivial. The concurrent evidence of local and systemic infection clearly indicates the nature of the complication.

The history of traumatic suppurative inflammation of the deeper portions of the cerebral parenchyma is not only relatively but absolutely difficult to trace. There are no positive external indications, and no pathognomonic symptoms. The initial symptoms are lost in those of the primary lesions, which it complicates as well as follows, and those of later development may be equally impossible of segregation and correct interpretation. Such abscesses, which have existed for months and have attained large size, have often escaped recognition, even by diagnosticians skilled in the knowledge of intracranial disease. The idiopathic cases, which have been made typical, present fewer difficulties, since they ordinarily originate in a single well-defined form of extracranial disorder, and pursue their course uncomplicated by other intracranial affections. They occur from traumatic cause with scarcely greater frequency than do the unavoidable suppurations involving the cortical surface, and are, except in pistol-shot cases, seldom attributable to neglect. The infrequency of traumatic central abscess of the brain is exemplified in the appended series of five hundred cases, in which it occcurs but four times: twice in the frontal, once in the fronto-parietal, and

an ultraconservative treatment has been adopted. In one hundred and twelve cases reported in English, Colonial, and American journals, from 1879 to 1895, mainly treated without effort to remove the bullet or fragments of bone which penetrated the brain, and often even without their removal from the external wound, central abscess resulted in eleven cases, or nearly ten per cent., in addition to many purulent infections of the cerebral surface. The histories of abscesses formed in this way should be of great value in the study of symptomatology from the uniformity of the antecedent lesion and from the absence of other complication, but inaccuracy of observation and carelessness of record have very generally minimized their importance.

The moment at which the inflammatory process begins in the contused cerebral tissue is impossible even approximately to determine. As purulent infection of the normal parenchyma from pneumonia and other distant infective diseases may remain unsuspected until long after the pus accumulation has become large, it is not to be supposed that its very beginning will be always or even usually manifest when the part is already damaged and the lesion indicated by perhaps multifarious and to some extent similar symptoms. In the most frequent form of cerebral abscess, that from otitis media, in which the extension of inflammation is perhaps abrupt and the previous symptoms have been local and not of a nature to obscure those which supervene, it is possible to have a recognizable initiatory stage. Pain of an altered character, rigors, vomiting, and a distinct elevation of temperature may unquestionably mark the access of a secondary process within the cranium. In traumatic cases the sudden acces-

sion of new symptoms may be followed by death and the post-mortem discovery of cerebral abscess; but they will probably indicate some crisis in its progress, some incidental cerebral or meningeal change, some increase in its size which has made it no longer tolerable, and not the inception of the pyogenic process. The existence of exceptional instances must be admitted. Thus, in one of the four appended cases, the pus formation was attended by distinctive symptoms in its incipience, which were recognized, and the abscess was evacuated at a very early stage. There are doubtless invasive symptoms in every case, though impossible of recognition—an elevation of temperature included in that of the antecedent contusion; pain, which is masked by the continued stupor or delirium of the patient; or circulatory and respiratory derangements which are equally inappreciable in the existent general disorder of the system. It may be assumed that retrogressive changes begin in the contused or wounded cerebral tissue immediately after the occurrence of injury, and that with or without the invasion of an infective organism, at a variable period, at once or soon afterward, they are followed by those of a pyogenic character. If the pyogenetic action is intense and the cumulation of pus is rapid, its symptoms are at once evident, despite the continuance of those of the primitive lesions; if the inflammation is of low grade and the pus formation slow, the presence of abscess may be indicated only at a much later period, possibly long after the disappearance of the primary symptoms.

At some period, early or late, the continued growth of the abscess, and its interference with the nutrition or function of surrounding parts, will usually occasion recogniz-

able symptoms, which may be characterized as general, and as localizing or dependent upon disturbance of special centres of control. They are neither numerous nor individually distinctive.

The occurrence of **chill** or **rigors**, which is regarded by Macewen as one of the most constant of early symptoms in the idiopathic cases which he describes, is less frequent in the traumatic form. The fact that the arachnoid membrane is not implicated, the usually lower grade of inflammation, and the different constitutional and nervous condition of the patient, may serve to explain this distinction.

The temperature, as is usual in cerebral lesions, is of importance. In general, it is elevated during the primary period in which the symptoms of the antecedent condition predominate, normal during a subsequent interval of quiescence, and normal or subnormal after the development of the abscess has been sufficient to occasion direct manifestations of its existence. This generalization is by no means absolute. In those cases in which progress is rapid, and the pyogenic process begins before the subsidence of the disturbance occasioned by the primitive cerebral lesion, the temperature will remain continuously high till the end; the sudden onset of late symptoms may be attended by an elevation from normal to 102° or 103°; and even in the more insidious cases a temperature of 100°+ is not an extraordinary occurrence. After operative evacuation of the abscess cavity, an immediate and signal advance occurs, which is soon followed by a recession to a point but little above the normal standard.

Some degree of pain in the head is an almost constant symptom. If it occurs early in the case, it is indistinguishable from that which attends contusion; at a later period,

especially when, after an interval comparatively devoid of morbid indications, it is an incident in the inception of new symptoms, it becomes characteristic. It may then recur suddenly and with great intensity, or, in the more insidious cases, with less severity, it may be of remarkable persistency. It is oftener in the frontal region than elsewhere, even in the case of cerebellar abscess; and, when the mental condition of the patient permits, it may be aggravated or even detected, though otherwise inappreciable, by percussion; but only if made upon the corresponding side (Macewen).

The pulse is characteristically slow, as it is in other lesions of the cerebral substance—not much above or below 60 in the greater number of cases, occasionally even slower, and in a minority of cases moderately accelerated. After evacuation of the abscess it increases in frequency with the rise in temperature, and also near a fatal termination.

The respiration, like the pulse, is diminished in frequency and like the pulse condition represents a usual effect of uncomplicated cerebral lesion. It is also at times irregular, with intervals of retardation and acceleration, or late in the progress of the disease may have the Cheyne-Stokes peculiarities. Thus neither the pulse nor the respiration reflects the special character of the structural alteration.

The mental condition, again, is characteristic but not peculiar. It is indistinguishable from that which often results from cerebral laceration, and sometimes from contusion, in which the activity of cerebral function is lessened. There are apathy, slowness and dulness of the mental faculties, insensibility to pain, somnolence, and increasing stupor. In the cases in which the pus formation

immediately succeeds the primary contusion and its advance is rapid, these evidences of decadence may be replaced or preceded by restlessness, irritability, and delirium, which terminate as before in stupor and coma.

Prostration and **emaciation** are disproportionate to the amount of febrile action as indicated by the pulse and temperature, and are excessive in relation to other attendant symptoms.

Vomiting or **vertigo** may be, either one, a prominent incident in individual cases, and, though they are not specific symptoms in abscess formation generally, are undoubtedly very significant in the particular instances in which they occur.

Convulsions and **muscular rigidity** are of more frequent occurrence, and the suppurative process is then so generally located in the temporal or frontal lobe that they may be regarded as in some degree localizing symptoms.

Constipation is in no sense an indication of suppuration, but is common to many morbid cerebral conditions; and retention of urine when it exists is to be in no greater degree attributed to the special character of the lesion. The loss of fæcal and urinary control in the terminal stage signifies only the destructive character of the lesion.

An **enlargement of the posterior cervical glands** after the cicatrization of an external wound in one of the appended cases, and before the occurrence of symptoms of an abscess beneath the angular gyrus, attracted attention. It is possible that further observation may show this condition to have some symptomatic importance.

The second class of symptoms depends upon the direct or indirect implication of cerebral centres of control. In eleven of an accessible series of twenty traumatic abscesses,

motor paralysis, anæsthesia, aphasia, disturbed reflexes, optic neuritis, hemianopsia, or abnormal conditions of the pupils, singly or in combination, were observed. The fact that nutritive disturbances extend for a considerable distance from the abscess formation lessens the significance of these functional or other disorders in localizing its situation; but they still have an approximate value. In connection with other and more general symptoms, they have great corroborative diagnostic importance. The paralyses are of most frequent occurrence, since the abscess is in the larger proportion of cases situated in the frontal or temporal lobe in the vicinity of the motor areas, and for the same reason the reflexes are often exaggerated or diminished. These functional disorders, together with aphasia and anæsthesia as results of local pressure or of adjacent structural alterations, invite no special comment. The existence of a lateral hemianopsia in like manner may result from the implication of a visual area in the event of an abscess occurring in the parieto-occipital region.

Pupillary phenomena are not infrequently manifest when abscess is seated in the temporo-sphenoidal or frontal lobe. The pupil on the corresponding side is then either myotic or mydriatic, with some degree of fixation, as the abscess is small and causes iritation, or as it is large and exercises pressure. Myosis may give place to mydriasis as a small abscess increases in bulk. Occasionally the only pupillary change is the sluggishness of one pupil to both light and accommodation. If the abscess is large, the pressure upon the third nerve, which occasions mydriasis, may at the same time cause ptosis and external strabismus (Macewen).

The occurrence of an optic neuritis after an abscess has attained moderate size is not infrequent, and while it is a local manifestation, so far as it is a consecutive disease of a special part, it is not a localizing indication, and might perhaps have been more properly included in the enumeration of general symptoms. It is due to an increase of intracranial pressure without reference to the site of the abscess, and is the most characteristic of all the abscess symptoms, in the sense that it is occasioned by a smaller number of lesions than any other. It may exist upon one side or both; when double it will not always be of greatest extent upon the corresponding side, and when single may be of the opposite nerve. The atrophic stage is seldom reached before the culmination of the primary disease.

Analytical examination and enumeration of these varied possible symptoms are easier than their synthetical rearrangement to form a typical case. It may be said that while in the greater number of instances the pyogenic process may be continuous with the degenerative changes which immediately follow the primary cerebral contusion, there will be an interval in which the progress of symptoms is unnoted. This is neither a period of incubation nor of intermission, but of remission, during which it is not unusual for the patient to follow his ordinary vocations, and if unobservant of himself to be unaware that he is really ill. This interval may extend over many months, but in time, suddenly or insidiously, more urgent symptoms will be developed; either an intense pain in the head, vomiting, and vertigo, or a convulsion, or muscular rigidity, with great prostration, followed by stupor and coma, may precede an early fatal termination; or pain persistent rather

than severe, gradual prostration and comparatively rapid emaciation, with slow pulse and respiration and possibly a slightly subnormal temperature, slowly failing sight, mental and physical lethargy, increasing somnolence and stupor lapsing into final coma, may extend over many days or even weeks. Intercurrent muscular weakness or paralysis, anæsthesia, aphasia, or pupillary changes may emphasize its progress. It often happens that many of these symptoms are wanting, and that others are indefinite or but faintly suggestive of the nature of the cerebral lesion. The usual end of all cases, whether their indications have been decisive or obscure, is death from coma in a previously existent asthenic condition. In the comparatively few instances in which abscess is acute, suppuration is diffuse and pyæmic infection follows; in the vast majority of chronic abscesses, capsulation is an efficient protection from rupture and a consequent diffuse infective inflammation. It is possible that the capsule may give way, and the pus reach the cerebral surface, or that it may break through into the ventricles, but these terminations, if they occur at all, must be of great infrequency. There is more probability that an extension of the inflammatory area about the abscess will involve the arachnoid membrane. If an arachnitis supervenes, either from rupture of the abscess and an access of pus to the cerebral surface, or from simple extension of the peripheral inflammation, there will be sudden increase in the severity and urgency of symptoms, there will be an abrupt rise in temperature

The face becomes livid, the pupils are widely dilated, the respiration is insufficient and perhaps stertorous, the pulse frequent and oppressed, and the temperature greatly exalted; the muscles are convulsed, coma is immediate, and death soon ensues.

DIRECT LESIONS.

THE differential diagnosis of intracranial lesions is usually practicable if symptoms are accurately noted and are subjected to careful analysis. They are first to be distinguished from all other morbid conditions, especially from those involving loss of consciousness or delirium, and, secondly, they are to be discriminated from each other. The existence of an encephalic injury is often patent from numerous and manifest indications, and from a knowledge of the immediate history of a case; but its recognition when symptoms are obscure or perhaps mainly negative, and no historical data are attainable, may require the exercise of great circumspection and exact discrimination. The frequent instances in which, after a survival of the patient for many days, extensive cerebral wounds are unsuspected till disclosed upon necropsic examination, evince the necessity of care, if not the difficulty in diagnosis which may be encountered. The case of an unknown man found unconscious in the street, taken to a hospital, retained in a medical ward, and first discovered in the dead-house to have been the victim of accident or violence, is not exceptional.

The primary symptom which undoubtedly overshadows all others, in all forms of intracranial injury, is coma or some degree of unconsciousness, which at the same time is

the most striking symptom in various other morbid conditions. It is natural that this identity should be, as it is, the most fruitful source of error in diagnosis. The number of idiopathic diseases in which coma is characteristic is large, possibly twenty and more. In case of the greater part of these, as in malignant fever, facial erysipelas, or diabetes, the danger of confusion with the effects of traumatism is too remote to necessitate any reference to their distinctive signs; in others, as in epilepsy or sunstroke, the distinction is so readily made that their consideration may be omitted with equal propriety; but in apoplexy, uræmia, alcoholism, and opium narcosis diagnostic difficulties are sometimes so great and erroneous conclusions so often reached as to demand some comparison of their symptoms with those which follow intracranial traumatism. The occurrence of delirium, which sometimes replaces or accompanies the coma of alcoholism or of uræmia, may be a special source of embarrassment when these diseases are brought in question.

In the coma of opium poisoning the pupils are strongly, immovably, and symmetrically contracted; the face, at first pale, becomes swollen, flushed, and livid; the breath may have the odor of opium; the skin is warm and moist or perspiring; the patient can be aroused, and the mental condition is then found to be normal and the articulation unaffected; the repsiration is markedly and progressively diminished in frequency, and is slow, it may be with stertor, and with a pause between inspiration and expiration; the pulse is at first slow and full, and later is feeble and rapid; the temperature is slightly subnormal; and the reflexes are absent without the occurrence of other disorders of muscular function.

In uræmic coma the pupils are dilated, and sluggish or irresponsive to light; the face is white, and the surface œdematous; the breath has a sweetish odor; the patient can rarely be aroused; the respiration is frequent and irregular, the inspiration hissing and the expiration sometimes noisy; the pulse is irregular, incompressible, and usually rapid; the temperature is normal, the muscular function and reflexes are unaffected, and the urine is albuminous.

In apoplexy the pupils are dilated, except in hemorrhage into the pons, and are immovable; the eyes are glassy and there may be strabismus; the face is pale or darkly flushed, the surface is cold and moist, the odor of the breath is natural, the patient cannot be aroused; the respiration is slow, irregular, and stertorous, and the lips are covered with frothy saliva; the pulse is variable, at first small and infrequent, and later full, hard, and frequent; the superficial arteries are often rigid; the temperature, at first subnormal, becomes and remains normal in cases destined to recovery, but in those which are fatal it continues to rise and attains a high degree; there may be unilateral paralysis of the face or extremities with exaggerated reflexes on the paralyzed side, and the urine is often retained.

In acoholic coma the pupils are not characteristically changed, and are usually normal; the face is likely to be flushed, and the surface is cold; the breath is alcoholic; the patient can be aroused unless coma is profound, and he is then irritable and incoherent, and the articulation is indistinct; the respiration is regular and without stertor, may be slow or hurried, and expiration is quickened; the pulse is frequent and weak, but becomes slow as coma in-

creases; the temperature is normal in some instances, but when the comatose condition is profound is markedly subnormal; and the urine may contain alcohol.

The symptoms detailed as occurring in these several forms of coma are variously modified, and many of them perhaps absent altogether, in individual cases; but the picture as presented is representative and substantially correct.

The symptoms occasioned by intracranial lesions have been sufficiently described; it remains to indicate their diagnostic relations. The fact of some intracranial injury having been received will be at once suggested by the existence of wound or contusion of the scalp or of demonstrable fracture of the cranium. It will of itself establish the diagnosis in a large majority of cases in which the origin of coma is in doubt, since the instances are exceptional in which the extracranial lesion and the intracranial disorder are independent of each other, and are scarcely more numerous in which a traumatic intracranial lesion is not attended by some superficial or cranial injury. It is possible that a drunken man, or an epileptic, or one falling in an apoplectic attack, should wound or contuse his scalp or fracture his skull, either with or without receiving further cerebral hurt, and that subsequent coma or delirium, which might be fairly attributable either to the traumatism or to the antecedent morbid condition, would be difficult of interpretation. The immediate history of a case, if attainable, is of first importance in establishing a *prima facie* probability of the presence or absence of encephalic lesion; but, as often happens when patients have been found unconscious in the street, the positive or negative evidence derived from external examination must take

its place. This must be thorough to be of absolute value; the head may have to be shaved to discover contusions or hæmatomata, or incision made to permit tactile or visual detection of linear fracture; and the occurrence of pathognomonic external hemorrhages of internal origin must be recognized and appreciated. Such an inspection might be sufficient to determine the probable traumatic or idiopathic nature of an initial lesion, but, even with the aid of an exact history, would be a manifestly unsafe reliance without the confirmation afforded by general symptoms. The critical study of the various features of a case will ordinarily serve to determine not only the etiological character of its lesions but also the occasional coexistence of traumatism and antecedent disease. In this scrutiny the symptomatic peculiarities of the several forms of coma must be considered and contrasted, or reconciled with the actual conditions presented, and the diagnosis perhaps finally established by the predominant importance of a single symptom.

The disease or morbid condition with which intracranial injury is most frequently confounded is alcoholic coma. It is scarcely possible to overestimate the importance of the correct differentiation of these two forms of coma, of such diverse origin and significance. Error in diagnosis not only inflicts great unnecessary suffering, additional danger, and possible disgrace upon the patient, but places corresponding responsibility, both moral and professional, upon the surgeon. The number of instances in which the indications of most serious intracranial injury have been mistaken for the results of simple alcoholic excess is inexcusably great, and justifies more than casual reference. This misconception of the significance of

symptoms is even oftener the result of negligence than of incompetence. It is often apparently forgotten that while there may be a fair presumption that a man found unconscious in the street, or delirious in a police station, is simply drunk, it is no warrant for the neglect of ordinary physical examination or disregard of obvious indications. The appended series of cases includes many in which fractured skull or lacerated brain, plainly evident when suspected and sought, has been unnoted in a hastily formed theory of alcoholic coma; others, in which the patient has been left by the ambulance surgeon to die in the police cells, or sent from the police court to a term of imprisonment; and very many in which he has been detained in the alcoholic wards of a hospital or even transferred to an asylum for the insane. These flagrant scandals still occur, and with increased discredit to hospital administration, since increased experience has shown the necessity of special provisions to avert the possibility of their occurrence. It is primarily essential, in approaching the diagnosis of a case of apparent aloholic coma, to divest the mind of all preconceptions and to realize that an unconscious man with a scalp wound is not necessarily drunk, and that even a drunken man may be so seriously injured as to require hospital treatment. Unconsciousness and the existence of superficial injury of the head should in any case arrest attention, and awaken suspicion of brain lesion. Coma ought not to be ascribed to alcohol, except by the strictest process of exclusion. Symptoms which are most likely to characterize different forms of head injury should be sought *seriatim*, and their absence, not less than their presence, noted. It should be remembered, finally, that even if the patient be intoxicated, this circumstance should

strengthen rather than allay suspicion of traumatism. It follows that the flushed face and sodden features, the alcoholic breath, which mark habitual inebriety, the incoherence and thickened articulation when the patient can be aroused, are nothing to the purpose till the fact of cerebral traumatism has been excluded.

The observance of temperature will afford an almost absolute means of diagnosis. In alcoholic coma, when profound, the temperature is subnormal, often not above 96°; and when less complete, not above the normal standard; its depression is likely to be proportionate to the depth of unconsciousness. These generalizations are founded upon a sufficient number of observations to justify the assumption that they are essentially correct. The rule that in cases of intracranial injury the temperature is elevated is equally positive, and when the lesion is substantially cerebral, the one in which the general condition most closely resembles that of alcoholism, the contrast in temperature is most decided. In a majority of instances in which cerebral lesion exists, the temperature is characteristic from the first, but in a certain number it is primarily depressed, either from general shock or from the fact of a concomitant alcoholic condition; and in this event, if other symptoms are not conclusive, some delay must occur in arriving at a positive opinion. If the comatose condition has resulted purely from alcoholic excess, the temperature will in a few hours become normal with the restoration of consciousness; if some intracranial injury has coexisted, the temperature, after the same interval, whether or not consciousness is regained, will rise above its normal degree to an extent dependent upon the nature of the

pressed by general shock, that condition will be recognized by its usual symptoms, and after reaction has been established the elevation of temperature will be no less characteristic. Even if intracranial hemorrhage has been the essential lesion, and the subsequent range of temperature is less than in cerebral trauma, it is still distinctive.

In the comparatively exceptional instances of primary subnormal temperature, in connection with traumatic intracranial lesions, the immediate recognition of structural injury is ordinarily practicable from an examination of the other symptoms presented. The indications of alcoholic insensibility, aside from those of inebriety, are mainly negative; neither the pupils, pulse, nor respiration, are characteristic; there is no paralysis, and the patient, except in extreme cases, can be aroused. If intracranial lesion exists, it can hardly fail that some one or more of its distinctive symptoms can be detected—unequal or dilated pupils, muscular paralysis or rigidity, unsymmetrical radial pulsations at the two wrists, abnormal relation of pulse, respiration, and temperature, or some other positive indication of organic change, which will be manifest while temperature is yet depressed.

The active delirium which may occur in the period immediately succeeding the reception of a brain injury is sometimes very difficult to distinguish from that which results from alcoholic excess. The difficulty may be further increased by the fact that the subject is of known intemperate habits, and was very likely intoxicated when first brought under observation. In those cases in which delirium is the first symptom noted, and probably replaces unconsciousness, the condition is made very deceptive. In this instance we are not aided by the temperature, which

is usually elevated in alcoholic delirium, and the elevation may be, and often is, very great. There may be no positive means by which such a case, if alcoholic, can be diagnosticated from one of cerebral contusion; but few cases of laceration will be encountered in which at least one or two characteristic symptoms cannot be detected, and there are differences even in the character of the delirium which may be recognized, though not easily formulated.

In the differentiation of the coma of apoplexy from that of encephalic injury the temperature is again of paramount importance. The observations of Bourneville, confirmed by others of more recent date, show that in apoplexy the primary temperature is subnormal, and that it subsequently rises scarcely above the normal standard except when death ensues. In an accessible series of twenty-three cases, with a mortality of seven, the highest temperature in twenty-one was 100°+; in two, which were fatal, it reached 102°–104°. This is in marked contrast to what happens in cases in which the lesion is traumatic, and in which from a possible depression the rise is immediate, whether recovery or death impends, and is practically continuous while the result remains in abeyance. The distinctive peculiarities of temperature in alcoholism, cerebral traumatism, and apoplexy are thus well marked. There are no other individual symptoms in apoplexy which are in any degree pathognomonic, or which may not be reproduced from a traumatic lesion; in their *ensemble* they may acquire a more positive diagnostic value.

It may happen that a patient, seized with an attack of cerebral hemorrhage, falls and suffers a consecutive intracranial injury. Two such instances occur in the appended series of cases, in each of which a cerebellar lac-

eration was produced. In the absence of history, such a concurrence of lesions would probably be impossible of detection.

The diagnosis of traumatic from opium or uræmic coma presents fewer difficulties. In the second, the strongly contracted pupils and excessively slow respiration, the fact that when unconsciousness is not absolute the patient can be aroused and that his mental condition is then clear, the often swollen and livid face, and perhaps the odor of the drug upon his breath, with a practically normal temperature and the absence of all traumatic indications, make the pathic condition clear. In the third, the facies, general symptoms of renal disease, and albuminous urine, even without the contrast of the special expressions of different cerebral lesions, are equally convincing. The only probable danger of confounding either one of these two forms of coma with that which results from intracranial injury will arise from inattention rather than from any essential difficulty in their discrimination.

These questions of diagnosis, as it concerns different forms of coma, have been considered upon the supposition that no previous history of a case is attainable, and that the fact of traumatism, even, is unknown, except as it may be indicated by some discoverable superficial or cranial lesion. It is fortunate that the immediate antecedent circumstances can usually be learned; and, with symptoms which can then have no equivocal meaning, no doubt need remain that some sort of intracranial injury has been sustained.

The fact that an intracranial injury has been received having been determined, the designation of the special form it has assumed is fraught with difficulties, which

sometimes prove insuperable. The lesions are likely to be multiple, and many of the symptoms to be equally referable to either one of their number; the manifestations of a circumscribed lesion are often lost in those of one of a diffuse character; and similar results constantly ensue from different causes; but a diagnosis of sufficient if not absolute exactitude is ordinarily possible. It is essential to determine not only the character but the location of a lesion, with a view both to prognosis and to possible operative interference. In cases which are obscure, diagnosis must rest primarily upon the recognition of individual symptoms, and secondarily upon a study of their relations of time and circumstance and upon a knowledge of what has been established as to the dependence of each upon definite structural alterations. Every existent symptom must be appreciated and estimated in a quest for one which is either pathognomonic or characteristic, and this, when detected, must be reconciled with others apparently inconsistent, though it may necessitate the assumption of multiple rather than of single lesion. The method of development, not less than the existence of symptoms, the period of their occurrence, and the changes which they suffer, must be accurately noted, and a provisional diagnosis often left to time to confirm or disprove.

The differentiation of the several primary lesions has been already indicated, either directly or by implication, in the enumeration and delineation of individual symptoms; but the more extended study of comparative symptomatology, in which the modified significance of the external manifestations of these internal injuries is to be estimated in view of their period of development, length of continuance, and mutual relations, is usually requisite to either

certainty or exactitude of diagnosis. It is practicable to make the consideration of specific diagnostic methods scarcely more than suggestive; the possible variations in the nature and relation of coexisting or consecutive symptoms are too multitudinous to admit of systematic or detailed description and analysis.

The examination which may be instituted to determine the character of an intracranial injury naturally begins with the condition of unconsciousness, at once the most notable and the most constant of all primary symptoms. If by chance consciousness has been retained, inquiry will then be at first directed to the proper interpretation in the light of attendant conditions of whatever other symptom may be most prominent. The loss of consciousness which immediately succeeds a cephalic injury is always the result of diffuse cerebral contusion; if unconsciousness is preceded by a conscious interval, however brief, or if after restoration of consciousness its privation recurs, it is occasioned by some form of intracranial hemorrhage. These distinctions are theoretically simple, and in practice readily made. If, however, primary unconsciousness is permanent or greatly prolonged, its continuance may be due either to the severity of cerebral lesion or to a complicating hemorrhage; and whether the one has persisted from the beginning or has been at any time replaced by the other, or whether both exist together, can be determined, if at all, only by a study of all the symptoms presented. The pulse, temperature, and respiration must be systematically recorded in every case from the first opportunity afforded for observation until its end, and the accuracy of this record, not only from day to day, but sometimes from hour to hour, may be of the utmost diagnostic importance; of

these, the temperature in its course and variations will afford in the greater number of cases the most distinctive indication of the nature of the lesion.

The primary temperature is above the normal standard in all forms of intracranial lesion, when it has not been depressed by general shock or the effect of alcoholic excess. In cases of comparatively uncomplicated hemorrhage, it will range from 98.5° to 99.5°, and will not subsequently exceed 100°, unless general cerebral contusion is well pronounced, when it may reach 101° or even 101°+. If the essential lesion is a cerebral contusion, the primary temperature is but slightly higher, but will rise progressively, and in a certain proportion of cases will be marked by recessions which do not attend hemorrhages. Cerebral lacerations are characterized by a still higher initial temperature, and when severe by an early and rapidly progressive increase with only brief and unimportant recessions, and if fatal by an often excessive final elevation. These generalizations result from an analytical study of the appended series of cases. If then, after the lapse of hours, consciousness still remains in abeyance, a stationary temperature but one or two degrees above the normal standard will indicate a hemorrhage of some profusion without serious cerebral injury; but a higher elevation which constantly increases, with possible recessions, will point to a visceral lesion. If this increasing temperature does not exceed moderate limits and its advance is slow, it will suggest contusion alone, or with laceration of small extent; a still higher early temperature, advancing rapidly and uninterruptedly or without important recessions, is an almost pathognomonic indication of laceration; and a resultant cortical or a coincident other form of hemo

rhage can be recognized only by the coexistence of some characteristic symptom of a different nature. In occasional instances of cerebral contusion the temperature may as rapidly attain a high degree as with laceration, and diagnosis must again depend upon the other symptoms. The cases in which consciousness after a brief restoration is again lost, permanently or for a lengthened period, have the same relations to temperature as those in which unconsciousness has been uninterrupted. It will be recalled that the recurrence of unconsciousness after an early interval of sensibility is indicative of an increase or supervention of hemorrhage, and that at a later period more or less conscious intervals in a generally unconscious condition result from a temporary lessening from time to time of the hyperemia or œdema of a diffuse cerebral contusion. The question of hemorrhage could scarcely be mooted in the last instance, but the temperature still conforms to established rule.

The diagnostic characters of the pulse and respiration can be less definitely formulated. In uncomplicated hemorrhages the pulse is oftener frequent than otherwise, and in cases which are to some extent complicated it is usually normal; but the exceptions to the rule are so numerous in either case that it has little practical importance. The conditions of the pulse are more uniform in epidural hemorrhages than in others, and slowness and fulness are so generally noted that they may be considered fairly characteristic. The respiration when hemorrhage is profuse and practically uncomplicated is only exceptionally of normal character; but its disturbances are without recognizable relation to the form of the extravasation or, in ral, to its situation. Increased or diminished fre-

quency, with or without stertor, occur alike whether the effusion is epidural, pial, or cortical, or whether it is at the base or vertex; but infrequency and stertor, like slowness and fulness of the pulse, are more nearly characteristic of epidural than of other forms of hemorrhage. If the extravasated blood compresses the medulla, the fact of hemorrhage, its position and its source in the pial or cortical vessels, are all absolutely demonstrated by extreme respiratory infrequency; this certainty, with the probability of an epidural form of hemorrhage, when the respiration is stertorous and moderately infrequent, summarize the information to be derived from a study of this function in connection with intracranial vascular lesions.

In diffuse cerebral contusion it is impossible to discover any variations from the normal pulse and respiration which occur with sufficient uniformity to afford assistance in diagnosis in individual cases. Neither the proportion of cases in which they are not sensibly affected, nor of those in which they are increased or are diminished in frequency, is sufficiently large to justify positive inference, though both incline to acceleration.

In case of the cerebral lesions in which laceration is an essential part, a more uniform condition of pulse and respiration can be predicated. After recovery from shock and unless meningeal inflammation supervenes, the frequency of the pulse upon early examination does not often exceed 90, nor the respiration 26. In the majority of cases the pulse is full and slow and not more frequent than from 60 to 70, and is sometimes but 40 in the minute. If the respiration departs from its normal standard, it is more likely to be slightly accelerated than retarded. These conditions are maintained till recovery, or, if the case is

destined to a fatal termination, until the patient becomes asthenic. The contrast so often presented by a nearly normal and unaccelerated pulse and respiration, with a high temperature and general symptoms of perhaps great severity, is not only striking, but is of great value in diagnosis. There is also a frequent want of correspondence in their changes, which is characteristic when they suffer more notable disturbance, the pulse becoming slower as the respiration is accelerated. The irregular rhythm of respiration which sometimes occurs with severe cerebral lesion is not observed in the case of hemorrhages, except as a symptom of coincident contusion. The asymmetrical radial pulsations upon opposite sides of the body, which are so conclusive of the existence of some form of intracranial injury, afford no clew to the nature of the lesion.

Dyspnœa and resulting cyanosis are not referable to compression of the medulla, but of the intracranial portion of the pneumogastric nerve.

An importance has been attributed to indications afforded by the pupils which is not warranted by an analysis of cases. They are so often normal, and when abnormal present so many variations in dilatation and contraction, that their observation cannot as a rule materially aid in diagnosis. The paralysis or spastic contraction of muscular fibres, upon which their changes depend, results from cerebral injury, and, as they occur in a much larger percentage of hemorrhages than of the essentially visceral lesions, it would appear that the cortex, which is coincidently involved, is specially connected with their control. This muscular derangement occurs, however, with lesion of every part of the brain, whether limited or diffuse, and with or without the concurrence of hemorrhage; but the

organic conditions which determine its presence or absence or the nature of its manifestation are unknown. There is a single exception to be made to this statement of the pathology and of the diagnostic value of pupillary change. The dilatation of the corresponding pupil with an epidural hemorrhage is due not to cerebral injury, but to direct pressure of the extravasated blood upon the third cranial nerve, and, having a definite origin, it is a distinctive symptom. Still it is neither constant nor pathognomonic; there are many epidural hemorrhages, even those occasioned by rupture of the middle meningeal artery, in which no pressure is exerted upon the nerve and no change in the pupil exists; and there are many instances of epidural hemorrhage with dilatation of the opposite pupil from some coincident cerebral lesion.

The mental disturbances which may replace or immediately succeed unconsciousness, or in some form occur at a later period, are all indicative of visceral lesion. Delirium is always the result of circulatory disturbance, and as an early symptom must be distinguished from the effect of alcoholism, and later from the same condition as produced by sepsis or by meningeal inflammation. If prominent and convincing evidence of hemorrhage or of laceration exists, it is to be attributed not to those lesions but to a complicating cortical contusion. Irritability, restlessness, or other sensory disturbances are to be ascribed to the same cause. There is no mental disorder, aside from loss of consciousness, which results from hemorrhage. The derangements of the intellectual faculties which are not incidental to delirium, as delusions, loss of memory, defective judgment, and mental decadence, indicate in the great majority of cases laceration, and this has been de-

monstrated by conjoined clinical and necropsic observation to involve the left frontal lobe. The dependence of such symptoms upon general contusion is possible but it is exceptional.

Loss or disorder of muscular action may occur with each of the traumatic intracranial lesions, but either is an infrequent result of uncomplicated contusion. Paralysis is especially characteristic of hemorrhages, and irregular muscular action of laceration. The paralyses, which may be either complete or incomplete, local or general, are due in the case of hemorrhage to compression, and in laceration to disruption of recognized motor tracts or areas. General or local convulsions, muscular twitchings, and muscular rigidity are occasioned by compression and irritation of the cortex in hemorrhage, or by irritation of the contiguous cerebral substance in laceration. The cause of these several motor disturbances, as they occur in individual cases, may be to some extent assumed from their known relative frequency from different lesions. This is notably true of convulsions which are so generally the result of laceration. The indication of hemorrhage or laceration afforded by a study of symptoms collectively is however, more directly diagnostic, and the relation of the pathic motor condition to special associated symptoms has great significance. The temperature which precedes the convulsive paroxysms is distinctly higher if the causative lesion is a laceration than if it is a hemorrhage; the immediate subsequent temperature has no corresponding value. The convulsions which result from hemorrhage, which is usually pial, are likely to be preceded or accompanied by paralysis, which is improbable if they are due to laceration. The precedence or coincidence of certain

mental derangements known to be usually connected with frontal lesion will greatly add to the probability which so generally exists that any convulsion is due to laceration of the temporo-frontal region.

The loss of fæcal and urinary control is a nearly pathognomonic symptom of laceration. It is fairly constant when life is prolonged for a number of hours, and it is of rare occurrence when cerebral injury is confined to hemorrhage or contusion. It is unaffected by the region of brain involved, and is independent of paralysis or the loss of consciousness. The retention of urine which sometimes occurs in cases of hemorrhage, on the contrary, is not indicative of the nature of the lesion, but is merely a result of the unconscious state, however produced.

The several pathic conditions which have been enumerated possess different diagnostic values. Some of them, like secondary unconsciousness or loss of fæcal and urinary control, indicate merely the nature of the lesion; others, like special forms of paralysis, indicate its situation; and others still, like certain mental disorders or an extreme infrequency of respiration, indicate both its nature and its exact or approximate situation. There are certain other symptoms which might be possibly encountered and interpreted in the light of physiological investigation as applied to cerebral localization. It might be supposed that traumatic lesion of the occipital visual centre, or of the temporo-sphenoidal auditory or gustatory centres, if such exist, would be attended by default or aberration of the corresponding special senses. If these effects have been recognized, they have been unrecorded—at least so far as taste or hearing are concerned.

The lesions of the speech centres in the frontal and

temporal lobes are not infrequently indicated in recovering cases by the existence of motor or sensory aphasia. The very general coincidence of an unconscious or delirious condition renders it exceptional as a recognizable symptom in those which are fatal. It has been assumed that compression from hemorrhage, as well as destructive injury of its centres of control, is an effective cause of the loss or disturbance of the faculty of speech. This assumption is opposed to the results of observation and not less to general anatomical and pathological considerations. The compression, if exerted by a small amount of blood, must be direct and accurately applied; if it be by a hemorrhage large enough to include these small spaces in the wide expanse of cerebral surface through which we are brought in contact with the world without, the individual fault is lost in the general obscuration of all the faculties which attends the grosser injury. A pial hemorrhage from meningeal contusion in this region is likely to be scant and diffused; a cortical hemorrhage, if small and confined to either area in which the control of speech resides, is derived from laceration of the part itself, to which as the primary and more potent lesion the result must be attributed; an epidural hemorrhage while yet in moderate amount acts directly and inadequately upon the temporal or lower frontal region through the dura, which serves as an efficient shield. In the case of wounds of the middle meningeal artery, in which the effusion of blood may in time become excessive, the loss of consciousness which then ensues abrogates speech with all the other manifestations of intellectual life. In the large number of hemorrhages included in the appended series of cases, none of pial or cortical origin have suggested an interference

with the integrity of speech, and in none in which consciousness has been retained or restored has blood descended from the vertex in sufficient quantity to produce such a result by compression of the frontal or temporal lobe. They include instances of large epidural hemorrhage in which consciousness was gradually lost before death or relief by operation, but none in which aphasic symptoms were recognized at any time during their progress. There is a case reported in which motor aphasia is attributed to hemorrage. The effusion was small; the patient was trephined, and some power of speech regained as well as some improvement made in an impaired mental condition. It has been demonstrated from extensive observations that intellectual and emotional impairment is not occasioned by traumatic hemorrhage. There were evidences of both in this case which the amount of blood discovered and removed was certainly insufficient to explain. It is necessary to assume laceration in order to account for their existence, and it seems more probable that the same lesion was the cause of the aphasia, which might readily have escaped notice in the comparatively small opening of operation, especially if it were entirely subcortical within the visual area. The patient after the lapse of some years was still aphasic. It may be added that it by no means followed that hemorrhage was the cause of symptoms because immediate improvement succeeded operation. The removal of a small portion of bone by the trephine not infrequently relieves morbid cerebral conditions, though the lesion remains undiscovered. Examples of successful results from operative failure in cranial surgery are as varied as the conditions which demand interference; one such may be cited from the appended series

of cases, in which traumatic convulsions of several days' continuance were immediately and permanently controlled by trephining both in the region of direct injury and at the supposed point of *contrecoup*, though nothing abnormal was discovered and nothing more was done.

It is evident from this rehearsal and alignment of indications that the primary factors in the diagnosis of traumatic intracranial lesions are the absolute and relative characters of the pulse, temperature, and respiration, and the varied phases of unconsciousness. The other pathic conditions presented are accidental in the sense of inconstancy, but the existence of one or more of them may be probably assumed in the majority of cases. The consideration which has been given to the history and progression of symptoms demonstrates their constantly varying individual significance in either class, and the necessity for their accurate observation and careful comparison in each particular instance. It may happen in the end that it is still impossible to arrive at certainty, and a conclusion must be based upon a just estimate of probabilities, in forming which the experience and sagacity of the surgeon may become conspicuous.

SECONDARY INFLAMMATIONS.

1. Arachnitis.

The diagnosis of acute arachnitis is probably impossible at the outset, if its invasion immediately succeeds the primary injury. Its indications then are not only illy defined, but are hidden by those of the original contusion and possibly by those of coincident lesions. If its invasion is also insidious, diagnosis may be no more than conject-

ural even at a later period. If again the inflammatory process is acute as well as immediate, its onset will be apparent by the occurrence of a sthenic constitutional reaction, of which the symptoms will be consistent with each other. The chill will probably be absent, and the temperature be no higher than is common with simple lacerations; but the respiration will be hurried and frequent, and the pulse full and strong as well as rapid, in contrast with the nearly normal or retarded pulse and respiration which characterize cerebral lesions with a high temperature. The delirium too will be more active, the heat of surface greater, and vomiting more likely to occur. In the more frequent instances in which an arachnitis of greater or less intensity is developd some days after the reception of meningeal injury, its invasion is marked by an abrupt change in the condition of the patient which is characteristic. The course of symptoms referable to the primary lesion is interrupted by a somewhat sudden rise in temperature, and by the manifestation of mental and sensory disturbances. The temperature, whatever may be its course in idiopathic cases, is subject to irregular and sometimes very marked daily recessions. The irritability, restlessness, delirium, or somnolence, which are persistent as well as invasive symptoms, are often in distinct contrast to the conditions which had previously existed. The sudden rise and often notable subsequent fluctuations of temperature, and the varied manifestations of cortical irritation, are in general the only direct means of recognizing the meningeal inflammatory process, whether it results from infection or from a continuance of the original structural changes. The occurrence of post-cervical or general mus-

volve the spinal membranes, as disordered function from implication of the cranial nerves exists only when the disease extends to the basilar region. In the cases in which the inflammation is wholly or mainly limited to the vertex, and which perhaps constitute the majority, such localizing symptoms are almost impossible. Paralyses involving the extremities are not to be expected, since the disease usually terminates in fatal asthenia before the effusion is sufficiently large to interfere by pressure with either consciousness or muscular action. In the larger number of cases, whatever the period of their development and whatever the grade of inflammation, the pulse and respiration are not affected to a degree which challenges attention. There are no symptoms which, in themselves and apart from attendant circumstances, are either pathognomonic or even characteristic.

The character of the effusion cannot be inferred with any certainty from a study of symptoms. The occurrence of chill, with a pulse, temperature, and respiration denoting a sthenic constitutional reaction, and with active delirium, may properly be taken to indicate the formation of pus; but the chill may be absent when suppuration is profuse, or present when the effusion is wholly serous or sero-fibrinous, and it is probably rather the measure of the susceptibility of the patient's nervous system to irritation than of the height of the inflammatory process. In like manner the invasion and progress of the inflammation may be extremely insidious though the event is suppurative, or the constitutional reaction may be severe when the exudation is simply serous. If the inflammation is known to be infective, the purulent character of the effusion can hardly be in doubt, though the symptoms may be ambiguous. A

traumatic arachnitis in young subjects sometimes assumes a tuberculous character; this may be suspected from the successive implication of cranial and spinal nerves, which indicates its basal situation, and from the sluggish progress and great prolongation of the disease.

2. Abscess.

Parenchymatous, like meningeal inflammation, when traumatic, is probably always a continuance of structural changes which begin in an original contusion, and, with or without the intervention of an infective organism, terminate in the leucocytal migration. It differs from meningeal inflammation in the fact of invariable defeat of the leucocytes and formation of pus. If this process is vigorous and rapid, its diagnosis may come in question before the disappearance of the symptoms of the primary lesion, and while the liability to the development of an arachnoid inflammation still exists. It oftener happens that the indications of abscess begin to be evident only after the lapse of weeks or months, and perhaps not till the occurrence of an original injury has been forgotten. If in the interval the patient has been unobservant of himself and has not deviated from his usual habits of life, the symptoms which finally compel attention may seem very obscure.

The exceptional instance of what may be termed a primary cerebral abscess must be diagnosticated from its still existent source, cerebral contusion or laceration, and from arachnoid inflammation. It is doubtful if the earliest constitutional reaction from the local inflammation can be distinguished from that which attends an arachnitis. Such differences as exist are not greater than those which may occur in individual instances of either disease. It is

only as they progress further that their symptoms diverge; greater cortical irritation, fluctuating and increasing temperature, and possibly an implication of the cranial nerves, in arachnitis; decreasing temperature, more rapid and extensive nutritive changes, and more notable disturbances of functional control from pressure, in abscess. The differentiation from the antecedent and concurrent visceral lesion, if practicable, is made, as in arachnitis, by the predominance of the constitutional evidences of an inflammatory process over those of a simply destructive local change. After the initial symptoms have given place to those of an existent body of pus, the conditions do not differ from those of the more usual chronic abscess, except that there is available a continuous history and consequently the means for a more facile interpretation of the phenomena presented. The abscess of more lengthened and insidious development may manifest itself after weeks or months of apparent quiescence, either abruptly or by the gradually increasing gravity of symptoms which have finally come to challenge attention. In the first case, diagnosis is to be made from sudden vascular lesion, and in the second, from the results of an older vascular lesion and from tumor. It may also happen that one condition may be engrafted upon the other; persistent symptoms of more or less urgency then terminate in some distinct crisis, but without raising new issues in diagnosis. In a large proportion of late abscesses of traumatic origin it is possible to discover or to surmise the antecedent cranial injury; this in otherwise obscure cases may be an essential factor in determining the nature of the lesion. The fact that an injury of the head has been sustained, even without a history of cerebral implication, is entitled to great weight in

the final summary of indications, as in other cases of abscess is the presence of an otitis media or other evident source of possible infection. If the occurrence of the primary cerebral contusion or laceration is undoubted, there will be little difficulty in interpreting the symptoms of its inflammatory sequel. It would be improbable, at least, that cerebral softening from thrombosis or embolism, or that a morbid growth should occur at this time. There are certain broad distinctions, however, independent of a history of traumatism or of a discoverable source of purulent infection, in the symptomatology of cerebral softening, abscess, and tumor, which will ordinarily serve for their differentiation.

Structural change in the brain tissue from vascular obstruction is so much more frequent than the formation of abscess or tumor that it is naturally first suspected in cases in which paralyses occur with progressive mental decadence. These conditions, with some impairment of the general health, are common to all organic diseases of the brain, and together with anæsthesia, aphasia, and hemianopsia are also localizing symptoms, but not diagnostic of the nature of the lesion; they simply serve to narrow the field of inquiry. If the radial arteries are rigid, if the cardiac valves are thickened, or if the patient is advanced in life, or if, younger, he has been contaminated by syphilis, the probability of a simple cerebral softening is increased. The absence of symptoms which are directly characteristic of abscess or tumor renders this probability as near an approach to certainty as can be attained.

There are certain additional symptoms which are indicative of both abscess and tumor, but not of softening; these are the result of increased intracranial pressure, and

are: headache, vertigo, slow pulse and respiration, convulsions, optic neuritis, dilatation of the pupil, and a subnormal temperature. There is a still further indication noted by Dr. J. F. Eskridge. He has been led to conclude from a number of observations that in irritative lesions a sustained temperature from ½° to 1° higher on the paralyzed side, several weeks after paralysis has become manifest, is characteristic. A bilateral variation of axillary temperatures may be occasionally observed in cases of cerebral softening, but it is not sustained and not uniform. Extreme variations have been noted also in some of the appended histories of intracranial injuries, but they were ephemeral, and inconstant in their relation to the site of the lesion. This point in diagnosis seems worthy of more extended observation.

The final analytic process by which abscess is to be differentiated from tumor requires not only the recognition of its positively distinctive symptoms, if such exist, but an estimation of the comparative value of those common to both diseases as they occur in either one, and a continuous regard for suggestive facts in the history of the patient. It is questionable if any symptom is pathognomonic, unless it be the occasional escape of pus through a cerebral sinus, though the continued rigidity of more or less paralyzed muscles for days at a time has been regarded by Eskridge as positive evidence in cases of abscess in which tumor is the alternative. In general, the emaciation and prostration of the patient are more marked and more rapidly progressive than occur in connection with the growth of tumors, and the temperature is more frequently, persistently, and distinctly subnormal. The changes in the optic discs, on the contrary, are less fre-

quent and less pronounced in the formation of abscess. These differences, while not absolutely determinate of the nature of the lesion, are sufficiently characteristic to become important factors in diagnosis. It is still to be remembered that a subnormal temperature, choked discs, or marked failure of the general nutrition, may exceptionally attend even vascular occlusion. Variations in the size or stability of the pupils, and headaches of different degrees of severity and persistency, are equally observed in tumor and in abscess, and under similar conditions. The absence of such coincidents as syphilitic or tuberculous infection, or of the cancerous cachexia and their local manifestations in other parts of the body, and following the exclusion of predispositions to embolism or thrombosis, will of course add to the probability which exists that symptoms common to both are due to abscess in a given case rather than to tumor.

In every case of manifest disease of the brain substance, the distinctive character of the lesion is to be sought in the study of its etiology; this quest if successful will furnish the key to the correct interpretation of symptoms otherwise obscure.

PROGNOSIS.

A.—DIRECT LESIONS.

THE chances of recovery from intracranial injury may be estimated in part from the results which have been observed in large numbers of cases. Conclusions formed upon a purely statistical basis are generally to be distrusted, but the cases which have served for the present study of these lesions have been so many, and the methods employed for their diagnosis have been so uniform and so fully detailed, that their tabulation will have some special value. The method of treatment adopted may determine the issue in individual instances, but will exert no sensible influence upon general results when the aggregate number of observations is large, and may be assumed to be immaterial.

The five hundred cases, upon the observation of which this consideration of intracranial injuries has been based, may be classified primarily in reference to their general mortality.

I. *Fractures Involving the Base of the Cranium.*

Recovered,	110
Died,	176—286
Number of necropsies,	146

II. *Fractures Confined to the Vertex of the Cranium.*

Recovered,	75
Died,	41—116
Number of necropsies,	34

III. *Encephalic Injuries not Accompanied by Fracture of the Cranium.*

Recovered,	41
Died	57—98
Number of necropsies,	45

Summary.

Total number of recoveries,	226
Total number of deaths,	274
Total number of necropsies,	225

This classification, which is not directly one of intracranial injuries, is essentially such, since fractures of the cranium necessarily involve at least a cerebral contusion, and are usually more seriously complicated.

The percentage of recoveries is much greater than might have been expected in view of the fact that encephalic lesions, and especially those which complicate fractures of the cranial base, have been long regarded as of exceptionally fatal character. The proportion of recoveries from intracranial injury is indeed even larger than is indicated by the numerical percentage in the present series of cases. These were of more than average severity, and the least urgent were sufficiently important to demand hospital relief. They also include a considerable number of pistol-shot wounds, in which the fatality markedly exceeds that of the general class of intracranial traumatisms. It is to be further noted that in many instances death was almost immediate, and that these largely outnumber those

which proved to be relatively unimportant. If, therefore, regard were had only to those cases in which the evidence of lesion is distinct but in which time suffices for prognosis and treatment, and pistol-shot wounds were excluded, the average of recovery would be, not somewhat less, but considerably more than fifty per cent. of their whole number.

The very different percentages of recovery, as the cranial base or vertex may be fractured, only indicate the greater liability of the one to dangerous intracranial complication as compared with the other. The proportion of deaths to recoveries, when intracranial injury is unaccompanied by cranial wound, is only of statistical interest. The value of these deductions when made is entirely apart from the question of prognosis in individual cases. In general it may be said that the danger from encephalic lesion, when force is solely exerted through the bone at and about its point of impact upon the cranial vertex, is scarcely more than one-half that which attends when it is also transmitted through the cranial base; and that when force is entirely expended upon the intracranial contents, as it was in nearly twenty per cent of the series of five hundred cases, danger is somewhat less than when the cranial base is implicated. This difference is probably due to the exclusion of epidural hemorrhages, which occur in serious amount only as a complication of fracture.

It is difficult to estimate the comparative danger of the several lesions, from the fact that they are so generally multiple, and all together conspire to bring about a fatal result. It is also true that the severity rather than the form of lesion is to be made the basis of prognosis. It may be impossible therefore to infer their relative danger

from the mere frequency with which different lesions have been found to exist in fatal cases; but an opinion may be approximated by the tabulation of those which have occurred, separately or in conjunction, and in degree apparently sufficient to occasion distinct symptoms, omitting reference to those which are obviously trivial and probably void of effect. This course has been pursued in an examination of the two hundred and twenty-five appended cases which were subjected to necropsy. The resulting tables which follow are as nearly accurate as the complexity of the subject will allow. General contusion is unmentioned in connection with lacerations, though it always exists in greater or less degree, and is often the essential cause of death.

I. *Fractures of the Cranial Base.*

Laceration and more or less consequent cortical hemorrhage,	. . .	74
Laceration and meningeal contusion,	.	13
Laceration and epidural hemorrhage,	.	10
Meningeal contusion,	. . .	11
General cerebral contusion,	. .	9
Meningeal and general cerebral contusion,	. . . . .	5
Epidural hemorrhage,	. . .	12
Epidural hemorrhage and general cerebral contusion,	. . .	10
Abscess,	. . . . .	2—146

II. *Fractures of the Cranial Vertex.*

Laceration and more or less consequent cortical hemorrhage,	. . .	25
Laceration and epidural hemorrhage.		

Meningeal contusion, ... 2
Meningeal and general cerebral contusion, ... 1
Epidural hemorrhage, . . . 2— 34

III. *Encephalic Injuries without Cranial Fractures.*

Laceration and more or less consequent cortical hemorrhage, . . . 10
Laceration and meningeal contusion, . 10
Meningeal contusion, ... 3
General cerebral contusion, . . 5
Meningeal and general cerebral contusion, ... 14
Epidural hemorrhage, . . . 1
Epidural hemorrhage and general contusion, ... 2— 45

Summary.

Laceration and cortical hemorrhage, . 112
Laceration and meningeal contusion, . 23
Laceration and epidural hemorrhage, . 11
Meningeal contusion, ... 16
General contusion, ... 14
Meningeal and general contusion, . 20
Epidural hemorrhage, . . . 15
Epidural hemorrhage and general contusion, ... 12
Abscess, ... 2—225

Arachnitis resulted from meningeal contusion in fifteen
es; eight of these were in conjunction with fractured
n with fractured vertex, and five were independent
. In each case of abscess it chanced that
ctured.

The relative importance of the cerebral wound, its resultant hemorrhage, and its attendant general contusion, are too often impossible to estimate with precision to permit a further subdivision of the cases in which laceration is a prominent lesion. It sometimes happens that a cerebral wound comparatively trivial in extent occasions an enormous hemorrhage, or that with great destruction of cerebral tissue but little blood is lost, or that the concomitant general contusion is obviously serious or is insignificant; it then becomes easy to apportion or to limit the responsibility for the fatal result. In the majority of cases, if the primary shock of general contusion is surmounted, it is probable that when laceration is of much extent it is to be accounted the essential cause of death; cortical hemorrhage is but an incident of the cerebral wound. If another form of hemorrhage, or an inflammatory sequel coexist, the laceration may perhaps be held a less influential factor in compassing the final issue.

An analysis of recovering cases, with a view to the determination in each, of the existing lesions, as the complement of the similar examination of those which are fatal, affords results which are less definite because incapable of verification. Errors in diagnosis are to some extent inevitable; and yet in a very large proportion of cases the nature of the dominant lesion can be established with a fair approach to certainty. The diagnosis in each of the two hundred and twenty-six cases of recovery in the present series of intracranial injuries was made after careful study, and, conceding its correctness, justifies the appended summary of the lesions which were paramount. In twenty of these, a fracture of the base or vertex was so nearly uncomplicated that the trivial cerebral contusion, which may

be assumed to have existed, has been disregarded and the case omitted from the tabulation.

I. *Fracture of the Cranial Base.*

General contusion,	. . . .	57
Laceration,	. . . . .	24
General contusion and hemorrhage,	.	9
Epidural hemorrhage,	. . .	3— 93

II. *Fracture of Cranial Vertex.*

General contusion,	. . . .	57
Laceration,	. . . . .	12
Meningeal contusion,	. . . .	2
Epidural hemorrhage,	. . .	5
Superficial abscess,	. . . .	1
Central abscess,	. . . . .	1— 78

III. *Encephalic Injuries without Fracture.*

General contusion,	. . . .	14
Laceration,	. . . . .	17
Epidural hemorrhage,	. . .	3
Epidural hemorrhage and general contusion,	. . . . .	1— 35

Summary.

General contusion,	. . . .	128
Laceration,	. . . . .	53
Epidural hemorrhage,	. . .	11
Meningeal contusion,	. . .	2
General contusion and epidural hemorrhage,	. . . . .	10
Superficial abscess,	. . . .	1
Central abscess,	. . . . .	1—206

The preponderance assigned to general contusion as the direct cause of death is perhaps not entirely warranted.

In many instances in which doubt might fairly exist whether the brain lesion included laceration, it was rated as simple contusion in the absence of positive evidence of the further injury. It is not improbable that in this way laceration of moderate extent has been sometimes unnoted and its frequency in recovering cases somewhat underrated. In other instances contusion has been inferred from the simple character or brief duration of the symptoms; this is proper ground for diagnosis, but it occasionally happens that lacerations are discovered after death which have been unsuspected from a history of which all the details were well known. If full allowance be made for such errors in classification, there will still remain sufficient clinical evidence that general contusion is the essential, if not the sole lesion in as large a majority of recovering cases as is laceration in those which are fatal. Meningeal contusion is but twice mentioned as a recognized lesion when recovery ensued, and in each instance was manifest by the direct exposure of the œdematous subarachnoid tissue. It can hardly be doubted from its frequent occurrence in fatal injuries that this change must constitute a part of many of the general contusions which have a favorable issue. It is also possible that symptoms ascribed to a general contusion with epidural hemorrhage may be often due to a pial hemorrhage from meningeal implication, but in the absence of direct knowledge the more conservative course has been taken of assuming the general condition. The diagnosis in many instances was more precise than would appear from the tabulations which have been made, but the less specific statements are safer and sufficient for the present purpose.

The comparison of summaries in the fatal and recovering

cases seems to indicate that laceration, with its incidental hemorrhage, is at once the most frequent and the most dangerous of all lesions in cases of severity, and that general contusion is by far the most frequent in those cases which are of milder type. It affords no means of estimating the absolute danger of epidural hemorrhage or of meningeal contusion, which must depend in either one upon the amount and situation of the extravasation, and in case of meningeal contusion upon the possible occurrence of a subsequent inflammatory process.

The probability of the existence of particular lesions in cases of indeterminate character, based upon their known frequency and the estimation of their relative danger from previous observations, will have a certain prognostic value. The result to be expected in individual instances will directly depend upon the symptoms presented, as indicating the extent rather than the nature of the injury which has been sustained. The uncertainty which attends the issue of an intracranial traumatism is great, not only at the beginning, but at a later period when recovery is apparently assured. The immediate danger is to be measured by the profundity of shock, the depression of temperature, and the enfeeblement of pulse, and in some instances by the extent of visible injury; but reaction is still possible under conditions which seem to be hopeless. The question of prognosis which more seriously involves the judgment of the surgeon arises with the passing of this initiatory stage. It will suffice to indicate some of the more characteristic symptomatic phenomena which presage the impending course and termination of these cases of encephalic injury.

Neither depth nor prolongation of primary unconsciousness is in itself a measure of danger. It is not unusual for

complete loss of consciousness to continue for some days without concomitant or subsequent symptoms of special severity. If, however, during this time pulse, temperature, or other symptoms maintain or assume an unfavorable character, the mental default with which they are associated may then be regarded as further increasing the gravity of prognosis. The loss of consciousness which occurs at a later stage of the case is always of grave import; it is then a manifestation of an increase of cerebral œdema, a meningeal inflammatory effusion, septic infection, or of the asthenic condition of the patient.

The temperature from first to last in prognosis, as in diagnosis, transcends in importance all the other symptomatic indications. It gauges by its depression and by its persistence the danger from primary shock, and, a little later, the amount of a hemorrhage which may be otherwise known to exist. At a somewhat later period its rapid and progressive rise will denote the magnitude or severity of a meningeal or cerebral lesion. It has never exceeded 105° in any one of the appended series of five hundred cases which terminated in recovery, and it has only exceptionally attained to that degree. This may be regarded as the practical if not the absolute limit of temperature, in this class of injuries, consistent with the recovery of the patient. A sudden rise in temperature late in the progress of a case, or a continued subnormal temperature at any time after reaction from primary shock, is always reason for apprehension.

The pulse and respiration have less significance as regards the result. A failure of cardiac force when it occurs is neither more nor less threatening in this than in other forms of disease or traumatism. In general, the normal,

or full and moderately infrequent pulse, is equally characteristic in fatal as in recovering cases, and the want of symmetry in opposite radial pulsations has no evident bearing upon prognosis. The respiration does not usually reflect the degree of danger, except in primary shock and toward the close of the case, when it corresponds with the acceleration of the pulse. An irregularity of respiratory rhythm indicates a dangerous intracranial pressure, and an extreme infrequency of the respiratory act makes probable a fatal compression of the medulla.

Aside from pulse and temperature, symptoms become prognostic only as they determine the nature and extent of the lesions from which they result. In this way they are indirectly indicative of the degree of danger which impends. A high temperature or a rapid and feeble pulse is in itself alarming, whatever its specific intracranial cause, but the occurrence of convulsions or the loss of fæcal or urinary control is of grave import only so far as it can be connected with a lesion of dangerous extent or situation. The prognosis, like the diagnosis, thus becomes largely dependent upon the massing of symptoms and the study of their mutual relations; and this again, as was said of diagnosis, is rather a matter of surgical sagacity and experience than of formal rule. There is no class of injuries in which the issue is at all times so uncertain, and often so surprising. The cases which in their earlier days present the mildest symptoms, and seem most surely destined to unobstructed recovery, may at some later period assume a threatening or alarming character and perhaps prove fatal in the end; as others, in which the combination of symptoms long justifies the gravest apprehension, may eventually terminate not only with the preservation of life

but with perfect restoration of long disordered or suspended function. There are evident lesions so extensive, or it may be symptoms so clearly decisive, that a fatal event is unquestionable; but no conditions can be so favorable as to assure recovery. The prognosis must be in general not only guarded, but subject to revision from day to day, until all direct symptoms have disappeared, and temperature has been for a length of time practically normal.

SECONDARY INFLAMMATIONS.

1. Arachnitis.

The tabulation of recovering cases includes no instance of arachnitis. It is not meant to assume that none existed, but that none could be diagnosticated with that degree of certainty which is essential for statistical inference. There were cases in which some degree of meningeal inflammation was more than suspected, and in which the possibility of its confirmation was fortunately avoided. It may be be held as a correct generalization that in arachnitis the certainty of an unfavorable result is proportionate to the certainty of diagnosis. The acute or pyogenic arachnoid inflammations, whether simple or infectious, have probably an always fatal issue; the subacute inflammations, in which the effusion is serous or sero-fibrinous, may as probably be sometimes arrested in their course, but usually at an early period, while the indications are still of doubtful significance. Under such circumstances the comparative danger of the disease as it affects the base or vertex is scarcely of importance.

2. Abscess.

The termination of central abscess of the brain in death, unless avoided by operative interference, which is a recognized necessity of idiopathic cases, is no less inevitable in those which follow violence. The meagre chances of recovery after the absess has been discovered and evacuated are certainly not increased by the fact of a traumatic origin. The limited superficial suppuration which results from the neglect and infection of an external wound, and from the extension of the suppurative process to the cerebral surface, is amenable to control unless relief has been too long delayed. The three cases of central and one of superficial suppuration included in the appended general series of cases suggest no modification of these axiomatic statements.

Chapter VI.

PRINCIPLES OF TREATMENT.

DIRECT LESIONS.

THE manner of treatment is of importance in only a minority of cases, since many subjects of intracranial injury are fated to die whatever measures may be adopted for their relief, and a still greater number are destined to recover though left entirely to the resources of nature. In those which remain the result will often directly depend upon the assiduity or discretion of the surgeon. It is probable that in by far the larger proportion of cases in which the issue is determined by treatment it is met in the initial stage, and by insuring restoration from primary shock. For the accomplishment of this purpose the exercise of assiduous care is especially demanded; the methods and agents of procedure are not peculiar, and are too authoritatively prescribed to permit the use of any extraordinary discretion. At a later period, the question of operation may require for its determination the exercise not only of the highest surgical discretion but also of the nicest diagnostic discrimination.

The collapse from general shock may be nearly complete, but such a condition is never to be regarded as so far hopeless as to justify the neglect of restorative measures, unless the visible evidences of a fatal crushing injury are so positive as to afford no possible room for doubt.

The rapid ambulance system which has been so generally established, and the hypodermic use not only of alcohol but also of the concentrated cardiac stimulants, have made possible such immediate and efficient general stimulation in cases of urgent necessity as materially to reduce the early mortality in this as well as in all other forms of dangerous traumatism. In doing this these agencies have bettered the apparent numerical prognosis of intracranial injuries, since concurrent general shock has so often proved fatal when the essential lesion was far from irremediable. It is scarcely necessary in a work of this character to refer in detail to the means employed to establish reaction. They include the usual medicinal agents for cardiac stimulation, as digitalis, glonoin, and strychnine, and when the lesion is largely destructive or much blood has been lost their use may be necessitated for an indefinite time after nervous force has been restored. The resort to these reactive measures, when indicated, will take precedence of others for the direct relief of the intracranial injury. There are instances, however, in which the persistence of external, or even of intracranial hemorrhage, or of some other accessible pathic conditions, prolongs or intensifies existing shock, and may require concurrent treatment.

General reaction and the re-establishment of a comparatively normal pulse and temperature should be followed by the earliest possible attention to cranial and intracranial lesions. The first step to be taken, in all but the obviously trivial cases, is the shaving of the head, as a measure at once diagnostic and therapeutic. Its importance in diagnosis as a means of ascertaining the presence or absence of fracture, or the existence of otherwise inappreciable contusions, has been previously noted; its value in the

treatment of intracranial injuries will be considered later. The propriety of incision, if further necessary to the absolute determination of the question of fracture, has also been made evident; and the principles which govern the management of the cranial wound, and the details of their application to particular cases, have been formulated in a previous chapter. It is in cases of intracranial lesion without implication of the cranial wall that new problems of treatment arise, and that the advisability of operative interference must be reconsidered in the presence of new conditions.

An operation then ceases to be confined to the possible removal of already detached or depressed cranial fragments, or to be made only in fulfilment of an obvious indication in treatment. It is always an invasion of a heretofore unbroken osseous barrier, in pursuance of the dictates of a judgment which can never be infallible, and is therefore to be less lightly undertaken. It is not like the incision of the scalp, justifiable as a purely explorative procedure, which at the worst is nugatory if the result proves it to have been unnecessary. If in some degree explorative, it must still have sufficient logical basis to justify the risk attendant upon any operative interference at the time and under the circumstances which will exist when it is most likely to be brought in question. The one intracranial lesion for the relief of which, when clearly diagnosticated, it is fully conceded that operation may be justified or demanded, is epidural hemorrhage. The time of election for interference will be after the establishment of full or of partial reaction, as the extravasation is believed to have ceased, or to be still in progress after an interval limited in duration by the judgment of the sur-

geon. The judicious resort to operation in the treatment of this form of hemorrhage is vindicated both by results and by the observation of cases and necropsies in which it has been neglected. Success will be commensurate with accuracy of diagnosis and with justness of appreciation of the time and conditions when interference is demanded. It is fortunate that the diagnostic indications are often most distinct in this one of the intracranial lesions best fitted for operative relief. It is the form of hemorrhage in which, with or without primary unconsciousness, an interval of consciousness most frequently precedes its later loss. It is also the one in which the dilatation of the corresponding pupil is most characteristic, especially in the absence of the temperature and other conditions of general contusion; and the one in which gradually and perceptibly increasing paralysis of the extremities, and more or less rapidly progressive stupor ending in coma, are most often observed. The moderately increased or diminished temperature, the contusion or hæmatoma, or the cranial fissure in the vicinage of the larger middle meningeal branches, and other symptoms which in themselves or in connection with others mentioned may be considered diagnostic, it is needless to recapitulate. The diagnosis ought to be usually practicable in cases sufficiently uncomplicated to warrant the contemplation of a possible operation.

The decision as to the necessity or futility of operative interference, which may be one of the most difficult questions in intracranial surgery to decide, will often require the exercise of great discretion, inspired by much knowledge derived from experience and directed by the soundest judgment. Three considerations will present themselves: the contraindications which may exist in the influence of

allied lesions; the probable necessity for intervention; and the exact time at which operation should be done.

If other intracranial injuries have been sustained which are obviously or presumably of immediately fatal character, operation will probably hasten rather than retard the catastrophe, though it may confirm the diagnosis. The indications of severe diffuse contusion or of extensive laceration of the brain, added to the evidence of hemorrhage in sufficient amount to suggest an exploration of the cranial cavity, constitute a general condition which, if not absolutely hopeless, is ill calculated to withstand the infliction of further injury. The slender chances of recovery will be better conserved by inaction. It is only when symptoms point clearly to hemorrhage as the essential if not the exclusive lesion that operation for its relief will afford legitimate hope of success.

If the existence of a comparatively uncomplicated epidural hemorrhage of considerable extent seems to have been established by the study of symptoms, the necessity or propriety of attempting its removal by operative means will consecutively demand consideration. The questions involved are theoretically simple: whether the constitutional condition of the patient will permit interference; and whether the amount of extravasation and its inhibitory effect upon cerebral function are so far limited as to render its eventual disappearance by absorption possible or even probable. The solution of these problems is often easily reached; reaction may never occur, or, after it has become complete, the persistence or increasing gravity of pressure symptoms may positively indicate the danger of a continued expectancy in treatment. There are still other cases, in which reaction is in some degree unsatisfactory,

or in which the value of symptoms is indeterminate; a decision must then in each instance rest solely upon the discretion of the sugeon; no formal rules can be prescribed which should control his judgment or guide his action.

If operation is to be done, the time which is chosen for its performance may practically determine its result. Hasty and ill-considered action, or a lack of promptitude at the opportune moment, may end in equal disaster. The cases in which reaction entirely fails, or in which pulse, temperature, and external warmth are perfectly restored, while with the lapse of time pressure symptoms deepen or remain profound, can hardly occasion doubt as to the direction in which duty lies; but when with imperfect reaction these symptoms are still progressive, opportunity must be seized when the tide is at its full, when reaction has reached its limit, and before recession of strength begins, in order to profit by whatever slender chance there may be for a favorable issue. Success may be doubtful at the best, but any waste of vital force invites certain failure. It will not often happen that the fundamental rule in surgery, that operation should always be deferred till after reaction has been fully established, should be violated; never in this instance by reason of the gravity of pathic indications, or when reaction fails almost at its beginning; but only when, after a time, with some fair degree of strength, coma deepens and the pulse grows weaker, as hemorrhage still goes on. In the exceptional case, operation must always be early, as it always will be by choice, if done when hemorrhage has ceased and reaction has become complete; but the patient sometimes escapes observation till some days have passed and operative conditions may yet remain propitious.

The resort to operation in other forms of direct intracranial lesion is of very limited utility. Definite indications which can be met by operative measures are usually wanting, and in their absence an invasion of the cranial cavity must be empirical and without justification. The conditions which when recognized might be supposed to encourage this procedure are usually complicated by others which render it futile. The occurrence of subdural hemorrhage or of serous effusion from meningeal contusion occasions dangerous cerebral compression, and operation might be considered practicable and efficacious, as it is in epidural extravasation; and a pial, mistaken for an epidural, hemorrhage has in some instances been successfully treated in this manner. Such an operation, however, when premeditated, is without adequate reason and can afford no just expectation of success. The epidural clot is usually of limited area, and can be wholly removed, or in sufficient degree to avert danger until the remainder has suffered absorption. The pial or cortical hemorrhage, if in recognizable amount, will be widely diffused, and so entangled in the meshes of the pia that little can escape or be withdrawn through the cranial opening. The dropsical effusion which follows the meningeal lesion, if its existence could be positively known or reasonably inferred, might doubtless be drained through this perforation. The further and fundamental fact which contraindicates and makes fruitless the attempt to afford relief by the removal of these subdural accumulations is that the essential lesion remains unaffected. The pial hemorrhage or serous effusion which results from a meningeal contusion will probably be associated with a like condition of the entire brain substance, and the cortical hemorrhage will be no more

than an incident of the laceration from which it is derived. The added traumatism of the operation will thus be uncompensated by any possible betterment of conditions which depend upon the more important structural alterations produced by the original injury. The shock which attends any operative procedure, and which under favorable conditions may be unimportant when the cranial wall is alone involved, is always of more serious concern when the dura mater is incised and the cerebral surface exposed. If, as in the cases considered, nutritive changes in the intracranial tissues already exist, this danger is still further exaggerated, and must be taken clearly into account whenever under such circumstances so radical a measure may be contemplated.

In the history of one of the appended cases there is a record of a result obtained by trephination, suggesting a possible indication for operation, which may be stated with some reserve. In this instance, in which an apoplectic effusion was followed by a traumatic cerebellar laceration, the patient was paralyzed, anæsthetic, and profoundly unconscious. He was trephined and a large amount of serous fluid drained from the surface of the brain. His temperature fell in six hours from 103.4° to 98.6°. He became conscious, could articulate, spoke rationally and intelligently, gave his name and address, again lapsed into unconsciousness, and fourteen hours later died. The transient return to consciousness was in this case wholly unimportant, but it involves possibilities of startling medico-legal interest. It is not unusual for the victim of a homicidal assault to remain unconscious till his death, and that the criminal escapes in the absence of any witness of his crime. If such a coma can be reasonably ascribed to a

fluid compressing the brain, even though complicated by fatal lesion of its parenchyma, trephination, it is evident, may at least by a possibility temporarily restore consciousness, intelligence, and speech, to the furtherance of the ends of justice. The prospect of realizing this success would certainly be not altogether chimerical, for in the instance cited just such a hypothetical result was absolutely attained. The question of operation is not to be decided upon any ground foreign to the welfare of the patient; but when death seems inevitable and doubt exists as to the propriety of interference, medico-legal considerations are recognized as having a certain degree of weight. It has sometimes happened, when homicidal injury has proved fatal, that the attempt has been made to transfer responsibility from the murderer to the surgeon, who in his discretion has resorted to operation, or perhaps even found occasion for the administration of narcotics. This hazard, and the necessity of self-protection which it involves, are very properly held in view when professional duty permits; the acceptance of the same principle may equally justify, if occasion arises, a due regard for the interests of justice, within the limits established by conscience and sound judgment. The contingency is remote, but it is still possible.

There can be no advantage from operation when the urgent symptoms are the result of a general cerebral contusion. As an underlying condition of minor importance contusion may not contraindicate an operation otherwise made necessary; but in itself, or as it approximates a paramount lesion, it is obviously beyond the scope of any measure of mechanical relief. It is scarcely necessary to point out its impossible application to cases of this char-

acter, in which existent pressure is intracerebral and diffuse, and incapable of mitigation by any practicable removal of the cranial wall; and in which, moreover, the morbid state is essentially one of nutritive change in which interstitial pressure is merely incidental.

The operative treatment of brain lacerations, as they occur at points remote from the seat of fracture of the cranial vertex, might have the pathological warrant which in the general lesion is lacking, if its employment were practicable. Superficial lacerations of the vertex in connection with fracture are accessible, and, when drained and maintained in an aseptic condition, are usually cicatrized without serious danger to the patient. There is no evident reason why cerebral wounds which occur without cranial injury should not be as amenable to local treatment, if they could be reached; but they are often central, and, if superficial, very likely to be situated in some inaccessible region of the base. The impossibility of accurate localization of the lesion, in the vast majority of cases, by any known diagnostic methods is additionally a bar to any justifiable attempt at topical treatment by operative means. It is still a question, beyond that of feasibility, how far operation if made possible might increase the chances of recovery. In general, laceration as disclosed in post-mortem examination, except when enormous excavation has been produced by the attendant hemorrhage, is complicated by diffuse cerebral contusion which is largely responsible for the fatal result. In a minority of cases the cerebral wounds may be found to be in a septic condition, and it is in these, if their exact position could have been determined and exposed, that a possible danger might have been averted. Altogether there seems little to be

hoped for in these cases, now or prospectively, from any operative interference.

It has been proposed to treat arachnitis by perforation of the cranial wall, and withdrawal of the inflammatory effusion; and this method of treatment, it has been claimed, has been followed by good results. It is difficult to understand what permanent advantage can be derived from the removal of an effect while the cause remains operative. The elevation of depressed bone is a radical measure of relief, because with the removal of the source of symptoms, the possibility of their continuance or recurrence is removed; and the extraction of an epidural clot is made effective by the ligation, if necessary, of the ruptured vessel; but the mere drainage of an inflammatory arachnoid effusion will by no means prevent its return. There is no reason to believe that a diminution of the pressure exerted by a serous exudation will lead to the cessation of the pathic processes upon which it depends; it is not consonant with what is observed elsewhere when no obstacle exists to the escape of inflammatory exudations. In traumatic cases, at least, it is not the increase of intracranial pressure which proves fatal, but the direct irritant and depressing effect of the tissue changes which characterize the inflammatory process. So far as the effusion is plastic or purulent, drainage will be impossible or very imperfect, whether it be attempted from the Sylvian or posterior cervical region, or elsewhere, and no semblance of advantage can be expected to accrue. The views of Gross, which have been held to favor trephination and drainage in cases of traumatic arachnitis, are evidently founded upon the observance of limited purulent accumulations in the arachnoid cavity, and resulting from a now infrequent form of

pachymeningitis; they have no reference to a true arachnitis in which the effusions are subarachnoid and diffuse, and which is meant to be understood when the term meningitis is employed. Macewen's instances of recovery from purulent basilar meningitis after operation were secondary to inflammation of the middle ear, and were apparently recognized by him as limited. The advocacy by Ruth of this method of treatment is not supported by a record of answerable cases. It is doubtful if any properly authenticated instance can be adduced in which a diffuse inflammatory subarachnoid exudation has been drained with substantial benefit to the patient. It seems probable that in some cases subarachnoid œdema has been mistaken for a product of inflammation. A case reported by McCosh was undoubtedly one of arachnitis, possibly diffuse, and though recovery was regarded as nearly complete in the third month, the patient was then the subject of a forming cerebral abscess, from which he died some time subsequent to an operation for its relief. The record of necropsy does not make clear the relation which existed between the superficial and deep inflammatory lesions, but it is probable, from the conditions observed when the abscess was evacuated, that they were connected. This case was brilliant in diagnosis and operation in both its early and later stages, but it is at least not conclusive as to the extent of cure of the arachnitis.

The justifiable use of operation in head injuries is thus seen to be very limited. It may be summarized as properly general in depressed cranial fractures, frequent in comparatively uncomplicated epidural hemorrhages, and exceptional in subdural lesions whether of the brain or of the pio-arachnoid membrane. The resort to operative

measures, which is essential under favorable constitutional conditions in abscess of the brain and in intracranial gunshot wounds, will be given consideration in the later study of those conditions. If in the general class of intracranial injuries operation is to be but infrequently done, the question of operation will be often raised and decision as to the course to be pursued will then entail grave responsibility, since error in judgment may deprive the patient of a chance for life by increasing the danger of an already critical condition. Action or inaction at the wrong moment has invited disaster on either hand; but instances of too early or unwarranted operative interference by inexperienced surgeons outnumber those in which the ultra-conservatism of their elders has led to a perhaps fatal neglect.

The acceptance or rejection of operation as a method of treatment, when encephalic lesions are independent of accessible cranial fracture, is to be decided in each instance upon specific and tenable grounds. Operation is not to be done as a so-called last resource, and because the patient is likely or sure to die without it, as he is with it unless some blind chance interposes where reason affords no room for hope. Intracranial exploration will be defensible or indefensible as it is made with or without sufficient cause, and not as it may conform to an opinion deducible from a wide generalization of results that it is a good or a bad procedure. Unless general rules can be made absolute, the obligation to determine in each instance the treatment to be pursued in accordance with the indications which it presents remains unimpaired, and the contention that more lives are lost by operative interference which is unnecessary than by its neglect when it is required has no relation to the exigencies of particular cases. The failure to recog-

nize the truth of these apparently simple propositions accounts for the widely divergent practice which has obtained in different countries at corresponding or at different times. The record of ten years in which only four trephinations were reported in France, while during the same period one hundred and fifty-seven were reported in England (Dennis), is scarcely explicable except upon the supposition that treatment was ordered in accordance with conventional general rules, and not with a regard to special indications. The character of the discussion which is still maintained as to the merits of trephination necessitates the placing of some emphasis upon this phase of the subject.

There are late results of intracranial traumatism in which the indications for treatment are to be considered as those of a separate class of cases, distinct from recent injuries. These include paralyses and convulsions which are often due to the imperfect absorption of surface hemorrhages, or to superficial or ventricular effusion from an original contusion. The case of drainage of a lateral ventricle with subsequent recovery of the patient, reported by McCosh, was probably of this nature; the historical details and the absence of superficial effusion seem to disprove the inflammatory character of the disease, in which the subarachnoid and interstitial œdema of a general meningeal and cerebral contusion might have readily disappeared, while the ventricular serous accummulation remained and increased. One of the cases reported by Ruth seems as probably to have been an instance of superficial serous transudation from meningeal contusion. A purely explorative examination of the cranial contents is not only justified but demanded when such permanent functional

derangements succeed the primary effects of intracranial injury. The hazard of operation is minimized at this time, and if the hope of success is not realized even though an evident lesion is discovered, the patient's condition is not likely to be made worse.

The possibility of danger in the procedure may or may not be a factor to be considered in deciding upon the advisability of operation. No such question can arise in connection with the elevation of depressed bone; and in the removal of foreign bodies from the brain, or of an epidural clot from the cranial cavity less danger is incurred than is involved in the continuance of the morbid condition which it is sought to remedy. It is in the treatment of the subdural lesions, in which advantage is most problematical, that the operation is in itself the source of new and serious peril. It is usually a question of secondary interference, when conditions are always unfavorable, and the brain, which is necessarily exposed and in which morbid structural changes are in progress, is especially prone to resent disturbance. The prospect of success in meeting the indication is in general remote; and the danger to be incurred is so considerable and so imminent that ordinarily it may well suffice to negative any measure of this character. If at the outset, with urgent symptoms of hemorrhage, the cranial cavity is opened and the extravasation is found to be pial, and perhaps involving the arachnoid cavity, the conditions will approximate those of epidural hemorrhage, for which it has been possibly mistaken, and the prognosis will not be materially worse than with the more superficial lesion. The cases in which operation may be indicated for the relief of s toms existing at the end of weeks or months are

ogous to others which have been considered, and have been already placed in a distinct category. These are not more properly secondary than they are primary operations, as those terms are employed, but in this sense are entirely disconnected with the original injury; and, even though the brain substance is invaded, the danger of interference is less to be dreaded than when it is more closely related in time to the application of violence. If, however, attention be confined to the traumatisms of the subarachnoid structures, in which after the lapse of hours or days the increase in the severity of symptoms and the growing hopelessness of non-operative means of relief incite the surgeon to attempt an operation, the danger it entails as contrasted with the meagre promise it offers, cannot well be ignored.

The field of operation is restricted, but the indications for interference when they exist are positive, and whatever degree of danger must be encountered is to be minimized by the most scrupulous care exercised in the choice of time and circumstance and of technical detail. The necessity of awaiting complete reaction in primary operations has been stated fully, but its reiteration cannot be made too frequent. The single exception, when imperfect reaction is followed by indications of continued epidural hemorrhage, need not obscure the vital importance of the general rule. The neglect of this fundamental law in the management of all traumatisms, whatever may be its explanation, is probably at once the most frequent and the most fatal error of the inexperienced surgeon. If reaction

rence of considerable hemorrhage some external cerebral compression. There results an obstruction to cerebral capillary circulation which renders the administration of anæsthetics especially hazardous. It is better, therefore, in case of marked intracranial lesion to avoid their use when practicable, and, if indispensable, to restrict it as far as possible. When the immediate issue is fatal, the anæsthetic is often largely responsible for the result.

The general conduct of operation, and the management of its details are adequately described in the more recent text-books of general surgery. The maintenance of aseptic conditions is not less an absolute necessity than in abdominal section, and presents no unusual difficulties unless the exigencies of a case compel immediate interference under circumstances in which ordinary appliances are unattainable. The loss of blood, which, from the conditions of cerebral circulation is badly borne, must be restricted to the smallest possible amount by the exercise of unremitting care.

The immediate purpose of operation in cases without cranial fracture is to obtain access to the cranial cavity; and the use of the trephine affords in general the most convenient means to that end. The further employment of the rongeur, chisel, or saw, will be in like manner a matter of convenience, and with the situation and size of one or more openings, the reimplantation of bone, and other practical details, concerns a phase of the subject, as before stated, sufficiently considered in the general text-books. The extent to which exploration should be carried may be predetermined by the object for which operation has been instituted, or it may require decision at the moment in view of conditions disclosed in its progress.

In recent cases it will not often be designed to expose the subdural structures; but if, with or without epidural lesion, there are discoloration, distention, or absence of pulsation of the dura mater, that membrane should be incised. If the removal of foreign bodies be excepted, it is only in the treatment of the later results of cerebral lesions that the brain itself may be invaded, as it becomes necessary for the relief of ventricular distention or for the evacuation of abscess.

The general management of primary intracranial injuries is limited to the fulfilment of such indications as are directly afforded by symptoms. The necessity for the continuance of general and specific cardiac stimulants for a length of time after the establishment of reaction has been mentioned in correlation with the treatment of primary shock. The character of the pulse is the sole guide in determining the period of their administration, to which active delirium, heat of surface, or muscular strength, is no more a contraindication than in morbid processes of a different nature. Even in recovering cases these remedies may be requisite for days or weeks during the employment of more directly curative measures, to which they afford essential support, or through a prolonged convalescence.

The shaving of the head, which has been advised as a means of facilitating diagnosis, is at the same time a measure of treatment. The weight and thickness of the hair, with which the patient is often favored, increases the degree of local heat as it also prevents its dissipation, and its removal in some degree aids in the reduction of temperature. The essential advantage, however, to be derived from this procedure is that it permits the effective application of the ice-cap, which next to trephination, under

indicated conditions, is most nearly a directly curative resource. The topical use of cold in this manner is serviceable in those cases in which cerebral hyperæmia or meningeal inflammation is manifested by pain, high temperature, and active delirium. It is contraindicated in hemorrhages and cerebral lacerations when uncomplicated by serious contusion; but, as those lesions are constantly thus complicated, it may be held a proper resort when such symptoms are manifest, without regard to exact diagnosis. The constringence of congested internal vessels by the influence of cold exerted through the tegumentary coverings of the cavities of the body is fully recognized. It is evident in this class of cases from the usual subsidence of the symptoms for the relief of which it has been employed; and in many instances the nutritive changes inaugurated by the diffuse lesion seem to have been arrested, and the integrity of the parts restored. There is the history of a case, among those appended, which ended in recovery, in which the mind was clear and the temperature approximately normal whenever the ice-cap was applied, and in which the temperature rose markedly and delirium recurred whenever it was removed. These interchangeable conditions were made the subject of frequent observation for several days.

The use of a mild form of mechanical restraint is often required for keeping the patient in bed. It has an incidental value in quieting nervous excitement and husbanding physical strength, which is of even greater importance than the fulfilment of what is usually regarded as its primary indication. It is oftener applied in consequence of extreme restlessness or persistent efforts to rise from the bed than of violent delirium. The patient rarely objects

to the confinement, and his struggles cease almost at once, not from terror, but because his mental condition is such that he is easily diverted from efforts which he finds to be ineffectual. The waste of both nervous and physical force is thus better prevented than it could be by the administration of medicinal sedatives and stimulants. Leather bracelets and a strap to control the wrists and an arrangement of sheets will suffice for the purpose.

The control of nervous irritation and the maintenance of strength are the paramount indications in general treatment. If the ice-cap and mechanical restraint are insufficient to afford rest and necessary sleep, or are unsuited to the conditions of the case, the hypodermic administration of morphine is likely to be the most efficient of sedative medicinal remedies, and, judiciously employed, is apparently without subsequent ill effect. The bromides, which are administered to this end and for their supposed action in diminishing cerebral congestion, seem to be void of effect even when carried to their physiological limit.

The nutrition of the patient in every serious case, whatever its nature, whether of accident or disease, requires careful attention. In severe brain lesions which are not immediately fatal the restorative processes, if they occur at all, are usually slow, and the issue to some extent may depend upon the support which is given to the natural powers of endurance. Alimentation is not often attended with much difficulty in the earlier stages of treatment, or while recovery may still seem hopeful or possible. It is of essential importance that it should be systematic and not too long deferred. The injunction to be mindful of the action of the bowels and of the evacuation of the bladder, which is so generally coupled with that of careful nutrition, may

have special significance in relation to these injuries of the brain. In a considerable proportion of cases, the lack of urinary and fæcal control may render it superfluous; but when unconsciousness is profound retention of urine occasionally occurs, and in all pathic cerebral conditions the importance of the revulsive effect of free intestinal action is well understood. These several admonitions to caution, though trite, are not to be regarded as purely perfunctory; their observance is of absolute importance, and their neglect invites disaster.

There are certain other measures of treatment, sometimes adopted, which are of at least doubtful expediency. There may exist conditions which seem to indicate depletion, and the application of a leech behind the ear has been followed by mitigation of urgent symptoms; but it is doubtful if the gain is ever permanent, and, failing this, it is certain that the collapse of the patient will be accelerated. The alcohol bath will cause a temporary reduction of several degrees in high temperatures, and, though it sometimes may be more than once repeated, the temperature each time regains its former height. This is apparently an invariable rule when the danger limit of heat has been exceeded; and, if so, there can be no sufficient reason for this resort, since moderate elevations will not require so radical a measure. The iodide of potassium is still much in use in the treatment of brain injuries, without regard to their special nature. The results of extended observation fail to show that it is efficacious, either in relieving circulatory obstruction or in the absorption of pial effusions or of cerebral œdema.

SECONDARY INFLAMMATIONS.

1. Arachnitis.

The treatment of traumatic arachnitis is not essentially different from that of the idiopathic form of the disease; it will demand therefore but brief consideration. If serious complication of hemorrhage or cerebral lesion exist, and the mixed nature of the lesions is recognizable, very little can be added to the means which have been adopted to meet the earlier indications. Cold to the head, if not previously applied, is the one depressant which may be tolerated; blistering is not only useless, but harmful, as it increases existing general irritation. If the exudation is distinctly purulent, or the result of pyogenic infection, whether or not there may be complicating injuries of the brain, it is recognized as distinctly fatal, unless there may be hope in operative interference by which effective drainage can be established. That resort has already been given consideration. The cases in which recovery seems possible are those in which arachnoid inflammation is the direct result of contusion, without serous intracranial complication and without subsequent infection, and in which the exudation is mainly of a serous character. It is not always possible during life to determine whether the inflammatory product is either in part or wholly purulent, or whether it has resulted from infection; but in view of treatment it should be assumed, *pendente lite*, to be serous or sero-fibrinous. The treatment of idiopathic arachnitis suggested by the late Dr. Alonzo Clark, is not less applicable to the traumatic form of the disease; it is rational, it has been at least quite as successful as any other, and still retains favor. It consists essentially in the use of counter-

irritation to resolve inflammation and of diuretics to effect the removal of its serous product by absorption. The agencies he employed were blisters and the iodide of potassium. If the symptoms are acute, the blistering may be preceded by the application of ice or ice water to the head; or, if the condition of the patient is asthenic, both blisters and the cold appliances may be discarded. Local depletion may be indicated in individual instances, but with great infrequency. The strength of the patient must be carefully maintained and the use of stimulants may be required from the beginning.

2. Abscess.

The superficial abscess, which is nearly always of epidural origin, may come to involve the cerebral surface. It is no longer of common occurrence, and, if it exists at all, is an incident of neglected cranial fracture. Its treatment has been already intimated in a former reference to its symptomatology. In the examination of such a case, which will be suggested by the general indications of septic infection, or of localized cerebral disturbance, the cranial fracture will be necessarily exposed and the cranial cavity opened. If the pyogenic process has extended from without inward, the abscess will be at once disclosed. In the possible contingency that the pus formation is limited to the arachnoid cavity and subarachnoid space, the appearance of the dural surface will unquestionably indicate the necessity for its incision. The foundation of treatment and its operative measures are thus included in the methods of exact diagnosis. If the pus is thoroughly removed, the wound disinfected, drainage provided, and absolute aseptic conditions are maintained, it only remains to give such at-

tention to the nutrition, stimulation, and general constitutional management as may be required for primary lesions. It is scarcely conceivable that, with the exercise of care in the earlier treatment of the fracture and external wound, such a complication should result.

The formation of a superficial intracranial abscess, without cranial fracture or external wound, once frequently encountered, has almost if not entirely disappeared from modern hospital practice. The bone was contused, became inflamed, and was subsequently necrosed, with concurrent periostitis and pachymeningitis. Pus formed between the bone and pericranium, and between the bone and the dura mater, and might later extend to, or involve the cerebral surface. Its external manifestation was a swelling known as Pott's puffy tumor of the scalp. The history of local injury, the existence of tumor, and the coincidence of symptoms of septic infection and cerebral disturbance, confirmed the diagnosis. The local and the general treatment were thereafter the same as when the original injury had involved a compound fracture, rather than a simple contusion, of the bone.

The *hernia cerebri*, which is allied to superficial cerebral abscess, is another accident of cranial injury with dural implication which is no longer frequent. It is a tumor of variable size, in some part composed of brain elements, but in larger proportion of inflammatory products, which protrudes through a perforation of the cranial wall. It presupposes a cranial opening, whether from accident or operation, a wound of the dura mater and an inflammation of the cerebral surface with or without a pyogenic process which softens its structure and permits its extrusion by the force derived from the pulsation of the cerebral vessels.

It is of impossible occurrence unless the road has been opened and the brain substance has been at the same time sufficiently altered by inflammatory changes. Aseptic methods have so prevented or limited such degenerations of cerebral tissue that this complication has not only ceased to be a menace, but is no longer a source of great danger in the exceptional instances in which it occurs. If, with considerable loss of cranial and dural support, corresponding injury of the cerebral surface has been inflicted, some protrusion of the brain substance may be inevitable; but if the wound has been aseptically treated the tumor will contain but a small proportion of inflammatory products, and will usually be amenable to a continuance of aseptic treatment, in conjunction with moderate pressure equably sustained. It is still possible that the tumor, from neglect of early treatment, will eventually require excision, but this procedure will no longer entail the danger with which it was formerly attended. The septic conditions which already exist will by present methods be diminished rather than increased by operation.

Deep Abscess.

The traumatic central abscess of the brain, unlike the superficial inflammations just described, is often determined by unknown circumstances in which neglect has had no obvious part. The fact of its only exceptional occurrence, even before the necessity of surgical cleanliness was recognized, the possibility that external wound may be wanting, and the usual tenor of such histories as can be obtained, do not seem to indicate either its uniform or its habitual origin in superficial injury. There is therefore less stress to be laid upon the efficacy of a preventive treat-

ment, though from this, as from every point of view, the observance of rigid aseptic precautions is to be enjoined in the management of all injuries of the head. There can be no special treatment in the formative stage of the abscess; as there are no recognizable symptoms, there can be no direct indications. Treatment can begin only when the abscess has attained such size that it can be recognized, or at least reasonably suspected; and then if deemed justifiable must be purely operative. There is no diversity of opinion, and hence can be no discussion as to the almost certain fatality of even encapsulated purulent accumulations in the brain substance when undisturbed; nor as to the possibility of their successful evacuation by operation under favorable, and sometimes under unfavorable, circumstances. If the progress of a case has led to a well-founded conviction that abscess exists, and the general condition of the patient promises safety in case of operative failure, exploration should be made; or if action has been delayed till diagnosis is practically certain, or till a sudden irruption of symptoms unexpectedly discloses the nature of the lesion, and it is accessible, operation should be essayed, though only a forlorn hope of a successful issue remains. The situation of the cyst will be determined, so far as its determination is practicable, by the general consideration of symptoms upon which the fact of its existence was predicated, aided incidentally perhaps by a knowledge of the external seat of original injury. The spontaneous discharge of pus through a cranial wound, if such was originally inflicted, or through natural passages, is too improbable to be made the basis of speculation or of reliance. It is possible, especially in case of gunshot wounds, but even then indicates operative interference. These formu-

lated statements are believed to be in accordance with the views of surgeons generally and of writers upon the subject.

The choice of site for operation, the details of procedure, the disinfection of the abscess cavity, and the question of drainage have been thoroughly discussed by Macewen and others.

The appended series of fatal and recovering cases includes but five, or one per cent. of the whole number, which involved a pyogenic process of the parenchyma. One of these was a diffuse inflammation resulting from the use of an infected drainage tube; three of the four abscesses followed early neglect and a late admission to the hospital, and were probably preventible. There were two recoveries, both after operation; one in case of a cortical, and the other of a central suppuration. In one of the two fatalities a small abscess was evacuated, and in the other an operation was not deemed practicable in the condition of the patient.

These cases are included in the series appended.

PART II.

PISTOL-SHOT WOUNDS OF THE HEAD.

Chapter VII.

MEDICO-LEGAL RELATIONS.

THE increasing frequency of pistol-shot wounds, whether accidental, suicidal, or homicidal, has added to their recognized importance as a distinctive class of general injuries. The pistol is essentially the weapon of modern life; honest men carry it for defence, other men use it for defence or offence as occasion serves; it is accessible as well as congenial to the temperament of the time, and so suits the suicidal purpose; the results of ordinary carelessness render it additionally the fruitful source of accident. The countless wounds which it occasions are inflicted upon the head with disproportionate frequency as compared with other regions of the body, and have then peculiarities which demand special consideration in a comprehensive view of intracranial lesions.

Pistol-shot wounds of the head are of importance in two distinct relations: as they concern medico-legal inquiries, and in their purely surgical aspect as a subdivision of the class of encephalic injuries.

Gunshot wounds have been carefully studied at different epochs, and the effects of different arms and projectiles

at long range have been determined with some accuracy both by observation and by direct experimentation. The close of each great conflict of arms in modern times has been followed by such additions to the literature of the subject as have been necessitated by the attainment of successive increments of destructive power. The observations of John Hunter were made from 1760 through various Continental wars, and were terminated only with his death toward the end of the century. From that time till the conclusion of the Franco-Prussian war, a period crowded with historic military operations of great extent, not only in Europe but in the East and in this country, progressive improvements in arms and projectiles have been constantly paralleled by equal advances in the knowledge of the injuries which they inflict, and facts established by experience in the field have been supplemented by the later experimental observations of Bruns, Chaumel, and Nimier, and of many others, and very recently by those of La Garde under the direction of the Ordnance and Surgeon-General's departments of the United States Army. The results thus obtained may be held to be limited to wounds inflicted at long range. The pistol plays so small a part in actual warfare that it would be as useless as it is impossible to discriminate the occasional wounds it has produced from the incomparably greater number due to other small arms in habitual military use. The experiments on the cadaver, furthermore, which have been conducted by military surgeons have never included studies of the special characteristics of pistol-shot wound. Their history must be sought in civil life, to which their ravages have been largely confined and in which their interest mainly centres.

The Medico-Legal Relations of Pistol-Shot Wounds of the Head.

The medico-legal significance of pistol-shot wounds of the head is in great part dependent upon the character of the injuries suffered by the soft parts and by the cranium. The question of homicide or suicide may depend exclusively for its solution upon the possibility of thus determining the distance at which a fatal shot was fired, its direction, or its calibre. The intracranial wound may afford corroboration of the inferences derived from an examination of the external appearances, but in this regard its value is relatively slight. The surgical importance of head injuries of this class, on the contrary, will rest in great part upon the damage sustained by the intracranial contents.

Generalizations founded upon clinical observation have a basis too narrow to make them of use in the interpretation of facts pertinent to medico-legal investigation. The number of instances for comparison, made necessary by the diversity of attendant circumstances, is too great to be compassed within the limit of individual experience, even when favored by exceptional opportunity. In other varieties of gunshot injury examples may be at times indefinitely aggregated, as will happen in the course of military operations. There is the further difficulty encountered that the conditions under which the wound has been inflicted can rarely be determined with precision. The calibre of the ball, the distance from which it has been projected, its direction, and even the nature of the explosive, may be positively known, if at all, only from the statement of the homicidal or suicidal victim, who is not often

in a mental or physical state to afford definite information. In gunshot wounds inflicted upon the field of battle, distances are estimated at hundreds of yards, and with other essential conditions are predetermined and definitely formulated. In pistol-shot wounds, distances are usually calculated upon a scale of feet or inches, and distinctions must necessarily be more minutely drawn. There are no established data from which deductions can be made, and perhaps no other witness with knowledge of explanatory facts than the suicide or murderer, whose lips, as already said, are sealed by mental or physical disability, or by the instinct of self-preservation. Another source of inexactitude or failure in generalization exists in the alteration or destruction of evidences impressed upon the external surface of the body. The wound may have been enlarged or distorted, unburned grains of powder may have been removed, or smoke stains may have been washed away.

As a result of these several causes of uncertainty, the limitation of individual experience, the lack of positive knowledge of all the circumstances under which the injury has been received, and the changes to which the external wound and the adjacent cutaneous surface have been possibly subjected, there are but few opportunities afforded for satisfactory clinical observation of the results of pistol shots under exactly specified conditions of weapon, missile, distance, and direction. It would be difficult to find even an exceptional instance in which one or more elements necessary to comparison were not wanting.

In order to determine the effects produced by balls of different calibres, fired at different distances and under varied conditions, it is necessary to resort to experimentation upon the cadaver. Results obtained in this manner,

when confined to lesions and disfigurements of the scalp and cranium, if not identical with those observed in the case of similar injuries inflicted upon the living subject, are sufficiently approximate to have weight in the formation of medico-legal conclusions. The allowances which are to be made for the physical changes which have occurred in those parts in the quite recent post-mortem condition are scarcely greater than those required for the variations in individual clinical cases. Such experiments have been undertaken from time to time, but they have been heretofore desultory in character, limited in scope, impotent in conclusion, and infrequently or inexactly recorded.

A very great number of observations systematically made is essential to the formulation of rules which govern the infliction and reception of this type of gunshot wound. The calibre of the ball, its angle of incidence, and the distance which it traverses must not only be considered, but, additionally, the length of the weapon, the character of the explosive, the density and thickness of the individual cranium, and the special cranial region which is involved. It is of course impossible experimentally to fix the exact value of each one of these elements through all its conceivable permutations. If experiments be confined to the effects of balls of the four sizes in most frequent use, fired from a single variety of pistol, and at distances varying from contact to the limit at which penetration of bone is possible for each calibre, the number demanded will even then be very large. If each observation be repeated sufficiently often to discriminate occasional or uncertain effects from those which are invariable, their total number will be enormously increased.

In a series of experiments made upon the cadaver dur-

ing the past three years, the author has proceeded in the manner which seems essential to the formation of definite conclusions. The calibres selected were 0.22, 0.32, 0.38, and 0.44. The cartridges, like the pistols primarily used, were of a single manufacture, and the distances were the same for each calibre, varying from absolute contact of the weapon's muzzle with the skin to the limit of practicable observation, which was fixed at one hundred feet. For further comparison a limited number of additional observations was made with pistols and cartridges from other makers, and also with the smokeless in place of the black powder. The trials were made upon entire subjects recently dead, in which cadaveric rigidity did not exist and in which decomposition was not appreciably advanced. In such heads the physical properties of the cranium may be considered as unaltered, and changes in the superficial soft parts as insufficient materially to affect results. The influence of regional variations, and of differences in the thickness or density of individual crania, upon the amount and character of injury wrought by the missile was incidentally apparent in the course of observations of a more general character.

The effects of pistol shots upon the head which were especially studied were lesions of the tegumentary coverings and of the cranium; intracranial injuries were regarded as of less certain value on account of possible modifications from changes incident to the post-mortem condition in so soft a tissue as the brain substance.

The specific effects noted and subjected to comparison were, for the external soft parts, the characteristics of the external wound of entrance, the burning of the skin or hair, the staining of the skin by smoke, and the deposit of

unburned grains of powder upon the surface or in the substance of the skin or subjacent wounded tissues; and for the cranium, the peculiarities of the osseous wounds of entrance and of exit, and the resulting fractures of the vault or base. To these were added an examination of the brain track for the detection of powder traces or of bony fragments.

Extracranial Lesions.

0.38 calibre.

Length of barrel, 3¼″.

Diameter of ball, 0.430″.

Weight of lead, 146–150 grs.

Weight of powder, 15–19 grs.

Number of observations made upon the head, 108.

Number of observations made upon the body, 132.

The effects of balls of this calibre were given earliest consideration and in some sort made standards of comparison for those occasioned by others of larger or smaller size, since they are not only more commonly encountered but also present greater uniformity of character.

The wound of entrance is at all ranges smaller than the ball, circular except for an occasional minute tear, and from $\frac{1}{16}$″ to $\frac{3}{16}$″ in diameter. The margin is sometimes slightly inverted, or may be finely serrated, and when the range is greater than 3″ is often stained with lead.

Exceptions.—(*a*) If the ball strikes upon a cranial curve, the cutaneous wound may be lacerated and its size increased to a moderate extent. (*b*) At contact of the weapon, and occasionally even when the range is ½″, the

wound is much larger than the ball, and the subcutaneous tissues are disclosed, torn, and burned, or blackened by powder and smoke. The wound is then usually linear, from 1′ to 2″ in length, and often made secondarily triangular by the rupture of one of the cutaneous edges. It may possibly be quadrilateral, or even circular, but is always comparatively large, though in that event smaller than the ball.

Disintegrated brain matter may be forced through the wound of entrance at all ranges, and this will occur in the larger proportion of cases. It may simply bulge from the wound, lie upon the adjacent surface, be entangled in the hair, or be ejected to a considerable distance, as far even as fifteen or twenty feet. The amount varies from a bit not larger than a robin shot to as much as one or two drachms. As the extrusion of brain matter occurs at all ranges, and its quantity and force of ejection depend in part upon other circumstances, it has no value in determining the distance through which the ball has been projected.

Smoke stain upon the skin does not occur at firm contact, but when contact is imperfect, and at a range less than 6″ it is nearly constant. The exceptions are in certain cases in which the wound is made in a portion of the head covered with thick hair, and in the rarer cases in which at a range of ½″ the wound is lacerated and the subcutaneous tissues are widely disclosed. At a range from 6″ to one foot it is again nearly constant; from one foot to two feet it is of more uncertain occurrence. At a range of more than two feet it is always absent as a distinct area, though it may be perhaps detected with a damp cloth. The smoke-stained area is usually circular and dark, with an extension of lighter hue, which may be either symmetrical, irregular, or

FIG. 1.—0.38 Cal. At Contact. Burning of Eyebrow and Subjacent Skin in its Outer Third.

prolonged upon one aspect of the wound, and possibly with smudges upon neighboring prominences or depressions, as upon the ear or nose or in the orbital fossæ. These areas are, approximately: at ranges of less than 1″, from 1¼″ to 2¼″ diam.; at ranges of 1″ to 3″, from 3″ to 5″ diam.; at ranges of 6″, from 2½″ to 4″ diam.; and at ranges from one foot to two feet either very small, not more than 1″ in diam., or, as usually happens, very largely and faintly diffused over an irregular space of from 5″ to 6″. At a range of ½″ to 3″ there is ordinarily a deeply blackened circular area from ¼″ to ¾″ in diameter, surrounding the wound, which is the combined result of smoke, burn, and infiltration of the skin with finely divided grains of powder. With imperfect contact of the weapon a double smoke ring may be formed with a clear interval between the two, having an entire diameter of two inches. The density of the smoke deposit, the probability of its occurrence at the uncertain ranges, and its extension to more distant surfaces will be influenced by atmospheric conditions. Each will be notably as well as naturally favored by an excess of dampness, but the accuracy of the conclusions stated will not be further affected.

Burning or scorching of the skin occurs only at a range of less than one foot. At contact or at a range of ¼″ it is confined to the edge of the cutaneous wound, as it is when with a range of ½″ or less the soft parts are lacerated. At a range from ½″ to 6″ inclusive there is usually a circular blackened area ⅛″ to ¾″ in diameter, due in part to burn, as previously described. In a single instance it exceeded this limit; it is invariable if not prevented by the thickness of the hair at the point of injury. At a range from 1″ to 6″ inclusive the skin may be additionally

FIG. 2.—0.38 Cal. Range, 1". Burning of Hair, Black Area, Scorching of Skin within Larger Smoke Area.

scorched, either over a circular area of 1″ to 1¼″ altogether, or upon one aspect of the wound. At any of these ranges, the hair, if interposed, will be burned or singed over an area from 1″ to 2½″ in extent, and may or may not prevent burning or other characteristic lesions of the skin. At a range of 7″ to 10″ the blackened area is not formed, and burning is again limited to the edge of the cutaneous wound, or to a slight singeing of the hair, or it may be entirely absent. Burning is not constant at any range.

Unburned grains of powder may lie upon the surface of the skin or be more or less completely embedded in its substance. At contact or at a range of ¼″ no such indication exists, but in its place there is a powder infiltration of the exposed subcutaneous tissues, and a distribution of unburned grains upon the detached surface of the temporal fascia or of the fronto-occipital aponeurosis. The skin is ingrained with powder at ranges from ½″ to four feet inclusive, but at three feet the ingraining ceases to be invariable. At ½″ or 1″ it is confined to the blackened area of ⅛″ to ¾″ diam. At 3″ it is extended to an area of 1½″ to 2½″; at 6″, to an area of 2½″ to 4″, which is not much increased up to a range of one foot, though the average becomes constantly greater. At ranges of one foot and two feet it includes an area of 4″ to 6″, and in the case of wound involving the anterior temporal region covers the whole side of the face, neck, and ear. At three and one half and four feet, in half the observations made, no grains, and in the others not more than two or three, were embedded. These areas represent extreme measurements, but the greater part of the implantations were made within somewhat narrower limits, and as the range increased they were more widely

FIG. 3.—0.38 Cal. Range, 3'. Embedded Powder Grains, Scorching of Skin in same Area and Burning of Hair at its Margin, Smudge of Smoke Below the Eye.

separated from each other. The number is difficult to estimate; at a range from 3″ to two feet it is probably from 200 to 400 or even more; at three feet they may be counted, and the total number will probably not exceed 25 to 50, and may be not more than 3 or 4, and at four feet there will be 2 or 3 or none at all. At six feet they no longer exist.

Unburned grains which are free upon the cutaneous surface are not distinguishable when the range is less than 6″, though they may be seen upon the underlying cloth. There are more grains free at a range of 10″, and still more at one foot, but those which are fixed in the skin still preponderate. At a range of two feet the proportion is variable; at three feet the greater part are free; and at four feet only an occasional grain is embedded; at ranges of six feet and upward whatever grains escape combustion are free upon the surface of the adjacent parts or elsewhere. The grains are many at six feet, but at eight or nine feet and up to a range of not much short of thirty feet there are rarely more than six or eight, oftener one or two, and in many instances none at all. At and beyond a range of thirty feet not even a single grain has been found in any of the observations made. Within the limit in which fixed and free grains exist together their area is commensurate. At a range of from one foot to six feet the whole side of the face and neck and the ear is likely to be included. At the longer ranges in which there is but a grain or two, or at most but five or six, they are found ordinarily at a distance from the wound, even as far as the hip, though if it be but a single grain it may have made its lodgement almost upon the margin of entrance. In general the number of free grains increases relatively as that of the

FIG. 4.—0.38 Cal. Range, 6". Brain Matter in Wound, Scorching of Skin Anteriorly, Trace of Smoke, Free and Embedded Powder Grains.

fixed grains diminishes, and as the range is increased both are more sparsely scattered. If a white cloth be placed under the head and shoulders of the subject, unburned grains will often be detected when they fail to appear upon the surface of the head or face, but none when the range exceeds the already determined distance of thirty feet.

Lesions of the subcutaneous tissues occur from a discharge of the weapon at contact to a range of one foot inclusive. At contact these tissues are lacerated, burned, smoked, and infiltrated with powder, and the blackened surface is disclosed through the cutaneous wound. In exceptional cases these conditions may be produced in a wound inflicted at a range of ½″. At a range of ¼″ to 3″ the superficial tissues are usually separated from the temporal fascia or occipito-frontal aponeurosis, which is powder stained over an area of ¼″ to 2″. At a range of 6″ or more, if any stain exists it is not likely to extend beyond the track of the ball, though grains of powder may be exceptionally discovered at one foot. At a distance of 3″ or less in range the contiguous surfaces of the cranium and dura mater may be powder stained over an area of ½″ to 2″, or the margin of the osseous wound upon its outer surface may be similarly stained for a variable distance. The occurrence of fragments or particles of lead in the tissues, especially in the muscle, or of a lead stain of the bone or pericranium, is frequent when the range is 3″ or more, and almost invariable at the longer distances.

Unburned powder is carried through the whole length of the brain track when the ball is discharged at contact or when the range is not greater than ½″. At a range of 1″ it may not be detected beyond the median fissure; at 3″ it ceases to be invariable, and the quantity is much dimin-

FIG. 5.—0.38 Cal. Range, 1 ft. Trace of Smoke, Free and Embedded Powder Grains.

ished; at 6″ it apparently no longer penetrates the cranial opening. At greater distances the brain substance is occasionally stained with lead.

Fragments of bone more or less finely comminuted may be driven into or through the brain at whatever range the ball has been projected. Their number and size, and the depth to which they are carried, will depend rather upon the physical properties of particular crania and upon the point or angle of incidence, than upon the distance which the ball has traversed. They have therefore no significance in the determination of ranges.

These results have been corroborated in certain particulars by observations made upon other parts of the body. The characters of the wound of entrance or of the subcutaneous lesions might conceivably differ, by reason of different relations of bone and superincumbent tissues, as the wound is inflicted upon the head or upon the trunk or extremities; but the results of imperfect combustion of powder and the effects of flame, the area of smoke stain, the distribution of unburned grains, the burning of the skin, ought to be approximately the same in the two classes of cases. In one hundred and thirty-two corroborative observations of this kind comparison has been restricted to those incidents.

At absolute contact, not only upon the thigh and thorax, but over the skin or sternum where the relation of skin to subjacent bone is more exactly comparable to that which exists in the head, the deposit of smoke is not limited to the subcutaneous tissues but also occurs upon the surface

at 3″, 6″, and one foot it is very nearly the same, and at all these ranges it is constant. From one foot to two feet it is uncertain, and subject to similar variations, and at two feet it is no longer visible even in exceptional cases. Hence the only point of difference noted is in the extent of the smoke stain at a range of 1″ or less.

As upon the head, burning or scorching of the skin at contact is limited to the cutaneous edge. At ranges of less than one foot it has about the same extent and characters as was found to exist at corresponding distances in head cases, and as in them it never occurs when the range reaches or exceeds one foot.

The correspondence in results obtained in the two classes of cases is extended to the distribution of powder grains which escape combustion. At contact under the exceptional condition which permits the staining of the skin with smoke, some grains may be embedded in its area. The narrow blackened margin, due to burn, smoke, and infiltration of finely divided grains of powder, which at ranges of ½″ and 1″ or more was found to environ the wound as it occurs in the head, is reproduced in those of the body, and to it is equally confined the deposit of unburned grains. At ranges extending from 3″ to four feet the areas of embedded grain do not materially differ from those previously established; and at greater distances, though no longer embedded, they may as before be detected lying free upon the cutaneous surface, or upon the white cloth which underlies the body. At ranges greater than four feet, as before, the number of free grains is at once greatly diminished; their presence very soon becomes uncertain, and at some point just short of thirty feet they disappear altogether.

FIG. 7.—0.38 Cal. Range, 3 ft. Free Powder Grains, None Embedded.

0.32 cal.

Length of barrel, 3¼″.

Diameter of ball, 0.319″.

Weight of ball, 88 grs.

Weight of powder, 10 grs.

Number of observations made, 82.

The results of observation do not differ widely from those obtained when the ball is of 0.38 cal.

The wound of entrance is still found to be smaller than the ball, with the same exceptions, that is, at contact, or in the occasional instances in which it is lacerated by impact of the ball upon a cranial curve. Its diameter will vary between the same limit of $\frac{1}{16}$″ and $\frac{3}{16}$″, and the average is not perceptibly less. At contact, however, the wound, which is still usually linear, is shorter, not often exceeding 1″ in length, and is more likely to show its original circular outline with the tear on either side which has made it linear. It is less likely to be further complicated by a secondary tear upon one of its linear edges, which in the use of the ball of 0.38 cal. so often makes it triangular. In a single instance the circular outline was preserved without modification and the diameter remained smaller than that of the ball.

Disintegrated brain matter is extruded from the wound of entrance in two cases out of three in the aggregate number taken at all ranges. At contact, it is of exceptional occurrence. In these particulars, as in variations of amount and of force of projection, the facts observed are the same as in the use of the ball of larger calibre.

The smoke stain upon the skin is constant at a range of [illegible] in a minority of cases when it is from

FIG. 8.—0.32 Cal. At Contact. Trace of Smoke.

one foot to two feet, and is never formed when it exceeds that distance. The limit of range is therefore the same as in case of the ball of 0.38 cal. At contact there is usually a trivial staining of the surface which was exceptional in the former instance. At a range of 1″ or less there is a distinctly defined smoke area from 1¼″ to 2½″ in diameter with possible prolongations or more distant smudges; at 3″ the area is from 1½″ to 2½″ in diameter with sometimes an additional trace to an equal extent; at 6″ to 8″ the area, which is from 2″ to 2½″ in diameter, is sharply limited; at one foot, the area is reduced to 1½″ in diameter; and at two feet there is no longer an area and only exceptionally an indefinite trace. In general, at the lesser distances the traces of smoke upon the surface may be further extended, while at the longer ranges the area is more contracted and more sharply defined than with the larger ball.

Burns of the hair or skin occur within a range of 6″. At contact the burning of the cutaneous edge is limited to the central portion of the wound which is directly traversed by the ball. In the one case observed in which the wound maintained its circular outline there was a scorched as well as a smoked area of ½″ as there would have been in a similar wound inflicted at a perceptible range. The hair when exposed may be slightly singed immediately at the point of entrance either at its ends or at its roots. At a range from ½″ to 3″ the black area is from ⅛″ to ¾″ with a possible additional scorched area from ⅛″ to 1″. At 3″ or 6″ burning is not invariable, and at 6″ it is limited to the cutaneous edge or to the hair; at 7″ it ceases altogether.

The presence of unburned grains, either fixed in the skin or free upon its surface, is noted from contact to a range of

FIG. 9.—0.32 Cal. Range, 1". Black Smoke Area Concealing Smaller Area of Scorching of the Skin, Hair Burned, Powder Grains in Large Part Embedded.

three and one-half feet inclusive. The deposit of free grains may be detected upon the surface of the skin or upon the underlying white cloth at any range less than thirty feet. These limits seem to be absolute. At contact the ingraining of the skin is exceptional, and is then limited to the margin of the wound. At a range of 1″ and less it is confined to the black area of less than ¾″ in diameter, with possibly a very few isolated grains just beyond its border; at 3″ and 6″ it is limited to the extreme smoke area of 1¾″ to 6″, at one foot it is mainly within a space of 2½″, but is extended to a distance of 4″ and even 6″; at two feet there is less ingraining in the immediate vicinity of the wound, but the whole area is not smaller. At three and at three and one-half feet the number of grains embedded is very small, perhaps not more than two or three, and these at a distance from the wound. At ranges from 3″ to two feet, the number is very great, and probably not less than when the ball is of 0.38 cal. The unburned grains which remain free at ranges less than 3″ can usually be detected only upon the underlying cloth; at ranges of 3″ and 6″ they can be noted in the smoke area with those which are embedded but in much smaller number. At ranges from one foot to three feet they are numerous, and beyond that limit they are few and at a distance from the wound. The range at which unburned powder may be embedded in the skin is thus somewhat less than with ball of 0.38 cal., as is the area of smoke stain or of burning, but the number of grains and the area which they cover are not essentially different, nor is either the range, number, or area of those grains which are left free upon the surface.

FIG. 10.—0.32 Cal. Range, 3". Smoke Area and Scorching of Skin; Powder Grains Apparently all Embedded.

extent from those produced by the ball of 0.38 cal. At 3″ there are less staining and separation of the scalp layers, and at 6″ traces of powder are no longer evident. Fragments or particles of lead and lead stains, as with the larger calibre, occur at all ranges and with equal certainty at the longer distances.

Powder grains within the cranial cavity can be detected at ranges of less than 1″, and at contact—often upon the contiguous surfaces of the calvarium and dura mater, invariably in the brain track, and sometimes in the cutaneous wound of exit. At 3″ they can be usually recognized, but at 6″ it is probably never possible to discover them by simple visual inspection. A lead stain can be occasionally distinguished in the brain substance, either with or without the presence of grains of powder. There is nothing in the extent of intracranial staining which indicates the calibre of ball.

Fragments of bone more or less finely comminuted may be carried into the brain to all distances at all ranges, and this result of pistol-shot fracture of the cranium has no special characteristics with balls of this calibre

0.44 cal.

(*a*) Length of barrel, 6½″.

(*b*) Length of barrel, 2¼″.

Same cartridge.

Diameter of ball, 0.429.

Weight of ball, 256 grs.

Weight of powder, 23 grs.

Total number of observations, 90.

The difference in penetrative power and consequent

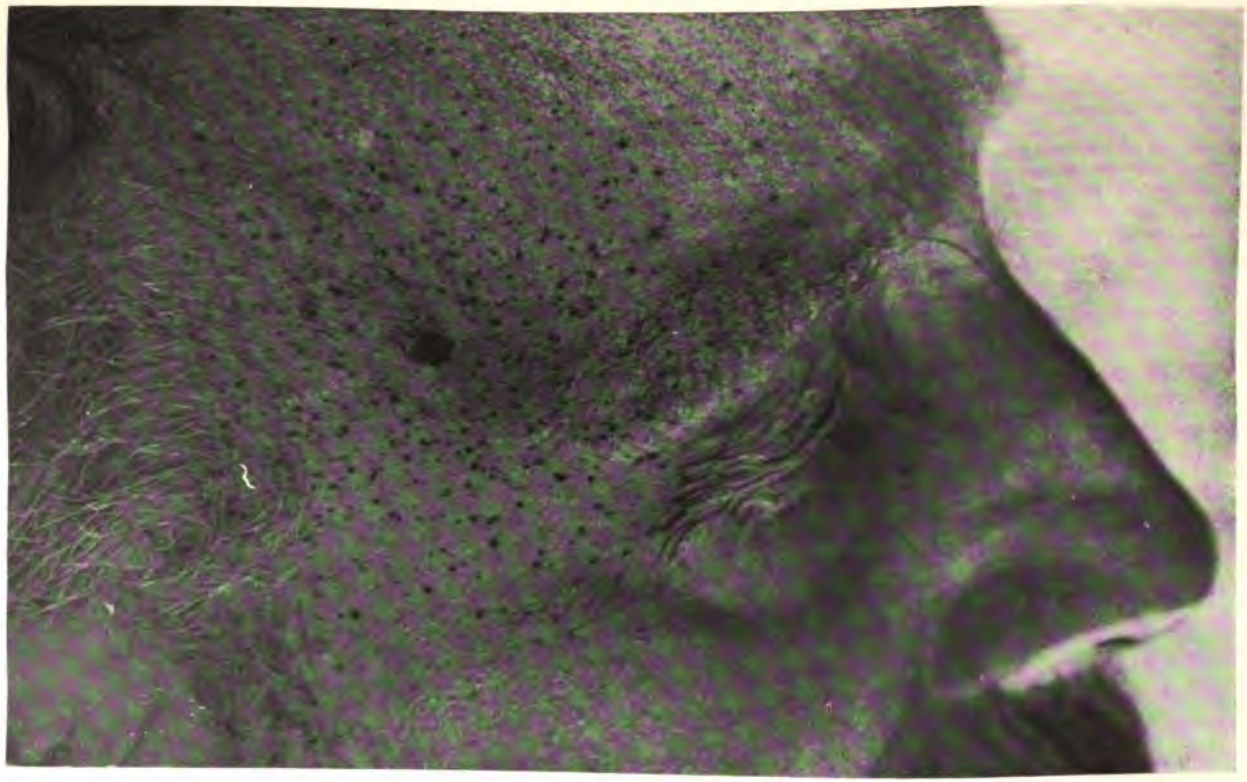

FIG. 11.—0.32 Cal. Range, 6". Slight Scorching of Skin and Eyebrow, Powder Grains all Embedded, Trace of Smoke.

effectiveness of different weapons of this calibre is so great that two were selected as types, and observations made independently for each. The results proved that corresponding or appreciable differences did not exist in the lesions of soft parts nor in other superficial conditions, and conclusions have been formulated from the consolidation of the two series.

The wound of entrance, while exceptionally as minute ($\frac{1}{16}''$) as any observed from balls of the smallest calibre, is ordinarily from $\frac{1}{8}''$ to $\frac{3}{16}''$, and occasionally $\frac{1}{4}''$ in diameter. At contact, the wound, though it may be as large as $\frac{1}{4}''$ when circular and symmetrical, does not exceed in length when linear those inflicted with a ball of 0.38 cal. In the use of the inferior type of weapon, in which penetration of bone often fails, the size of the wound is not usually increased. A lead stain of the cutaneous edge is of frequent occurrence, as it is with the use of balls of other calibres.

The extrusion of disintegrated brain matter through the external wound with more or less force occurs in somewhat more than half of the whole number of cases, and is observed at contact or at one hundred feet as well as at the intermediate ranges.

A smoke stain upon the skin, of variable extent, is perceptible in a minority of cases at contact, but it is always faint. At 3″ and less it is dense, and invariable, with an extent of 2″ to $2\frac{1}{2}''$, and a possible increase to 4″. At 6″ it has the same density and area, but ceases to be invariable. At one foot it is again faint and of still more uncertain occurrence. At two feet it has disappeared.

The hair or skin is burned at contact or at a range of 15″ or less. At contact, only the hair, or the margin of the wound to an extent not exceeding $\frac{1}{8}''$, will be involved.

FIG. 12.—0.32 Cal. Range, 1 ft. Brain Matter in the Wound, Embedded Powder Grains.

At a range from ½″ to 3″ inclusive, a black area of ½″ may be formed, or the skin scorched upon one aspect of the wound or concentrically ⅝″ to 1¼″, or the hair burned over an area of 2″ or less. At a range of 6″ the skin is scorched in a majority of cases, unless protected by the hair, and at 7″ it is possible, but was not positive in any of the observations made. At one foot the hair may be slightly singed, and at 15″ it is of only exceptional occurrence.

Powder is ingrained or remains free upon the surface in an area which varies to some extent in the use of the two types of pistol of this calibre. The differences are not great and might disappear if the observations were sufficiently extended. At contact with the inferior weapon, some free grains were found upon the underlying cloth in each instance, and in one a black area was formed about the wound of entrance; while with the better weapon no unburned grains, superficial or embedded, were perceptible in either of the observations made. At a range of ½″ there was a black area of ½″ or less with the first weapon, and there were only a few free grains upon the cloth with the second. At a range of 1″ many grains were embedded in an area of 1″ to 1½″ with the first weapon; and only a black area of ½″, or an area of larger embedded grains of 1″, was formed with the second. At a range of 3″ the area of embedded grains was the same, 1½″ to 1⅞″ in both. At a range of 6″ the area of embedded grains was again the same in both weapons, but was from 2″ to 2½″ in diameter. At a range of one foot, while the area of embedded grains might extend to 4″+, it was mainly limited to 3″×2″. The free grains were the more numerous when the inferior weapon was employed. At a range of two feet, with the better weapon, the grains were still embedded in the larger

FIG. 13.—0.32 Cal. Range, 2 ft. Free Powder Grains, Twelve Embedded.

proportion, and the area was extended to five inches. At a range of three feet the grains, which were about one-half embedded and somewhat less numerous, covered the whole side of the face. At a range of five feet few appreciable grains were unconsumed, of which not more than ten or twelve were likely to be embedded. At six feet no grains were embedded and few remained free upon the surface. At ten feet, and longer ranges, a few scattered grains upon the face or underlying cloth were of uncertain occurrence, and at twenty-five feet they had disappeared altogether.

The subcutaneous lesions produced at contact with the more efficient pistol of 0.44 cal. are more extensive than with weapons of smaller size in proportion to the more extensive cutaneous wound which it inflicts. The pistol of this calibre of inferior type has no greater destructive effect than has those of the lesser calibres. At ranges of from one to three inches no more extended staining of the tissues or separation of the layers of the scalp is observed than has been found to exist with the use of 0.38 cal., nor is the range longer in which they occur.

Powder grains are carried into the intracranial cavity and are appreciable at the same ranges and in the same proportion of cases as with 0.32 or 0.38 cal.

The comminuted bone is driven into the brain at all ranges as with other calibres, and in somewhat greater amount

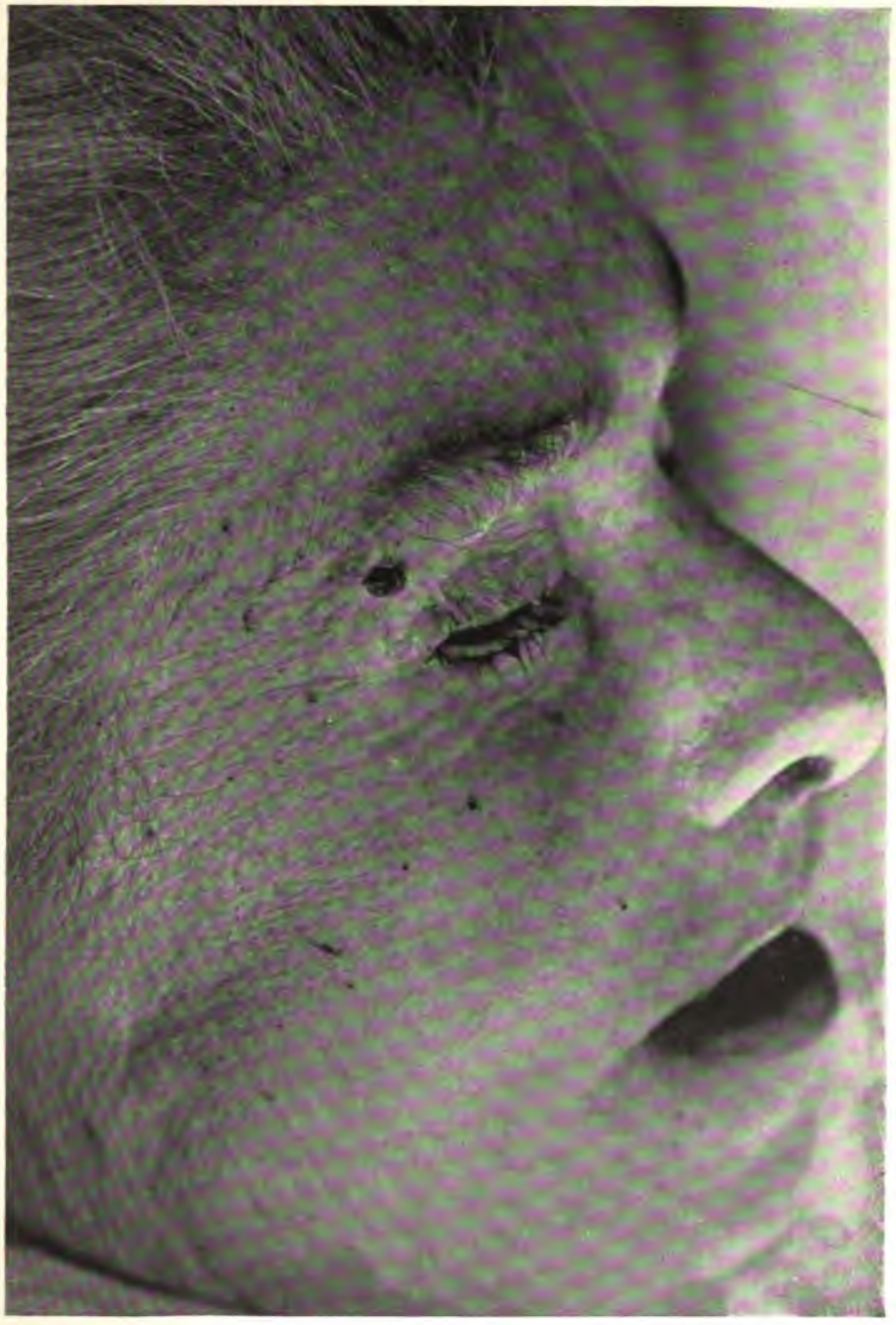

FIG. 14.—0.32 Cal. Range, 3 ft. Free Powder Grains.

The superficial conditions presented in wounds inflicted by this smaller missile are much more variable than when the ball has been of either of the larger calibres previously considered; but the variations are within definite and comparatively narrow limits.

The wound of entrance, while still circular and smaller than the ball, save in the exceptional instances noted for the larger calibres, is of relatively and often of absolutely greater diameter than the average ascertained for balls of 0.32 or even 0.38 cal. The diameter, which is within the same limits of $\frac{1}{16}''$ to $\frac{3}{16}''$, is perhaps oftener as large as $\frac{1}{8}''$ than in them. At contact the wound ceases to have characteristics which when the ball was larger habitually distinguished it from those inflicted at perceptible ranges. In fifteen out of eighteen cases the wound was small and circular, and from $\frac{1}{16}''$ to $\frac{1}{8}''$ in diameter; in the three remaining it was linear and patulous, 1″ in length in two of them, and $\frac{1}{2}'' \times \frac{3}{8}''$ with lacerated and everted edge in the other. Subcutaneous laceration occurred in but a single one, though blackening of some plane of tissue was invariable.

Disintegrated brain matter is extruded from the wound of entrance with much less frequency than in the use of balls of larger calibre, and never with the same violence which with them has been sometimes noted at moderate ranges.

The smoke stain upon the skin, which was rarely observed at ordinarily firm contact in the use of balls of 0.32 or 0.38 cal., is present in three cases out of four when the ball is of 0.22 cal. In three-fourths of these again it covers an area $\frac{1}{2}''$ in diameter, and in the remainder its extent varies from $\frac{1}{8}''$ to $\frac{3}{4}''$. At imperfect contact it

FIG. 15.—0.44 Cal. At Contact. Brain Matter upon the Surface.

often happens that a dense smoke area of ½" and a clear interval of the same or somewhat greater extent are included in a more or less distinct or complete outer ring of smoke, with an aggregate diameter of ½" to ¾". At a range of 1' the smoke area extends from ½" to the longest diameter, but is usually from ½" to ¾". At 2' and at 3' its average remains the same, but its density is less, with perhaps no definite area. At a range of one foot, as in case of a .32 cal., there is but a faint trace of smoke or none at all, and beyond that limit it is absent altogether.

Burning or scorching of the skin and hair occurs at contact and is limited to a range of 3". At contact in fifteen out of sixteen cases the margin of the wound was burned or the skin was scorched over a circular area of ⅛" to ¼", or in some instances upon one side only. At 1" the skin was scorched over an area of ⅛" to ½", or the hair was burned. At 2' the skin was occasionally scorched for similar distances, or, as more frequently happened, the hair was singed, and in many instances no burn of any kind or degree existed. At greater distances not even the edge of the wound was burned, though it was often lead stained.

The existence of **unburned grains of powder,** whether embedded in the skin or lying free upon its surface, is not absolutely constant at any range; and in any case the grains are comparatively few in number. At contact, as occurs with the larger calibres, they are practically absent, and this even though the wound of entrance is usually contracted. In a single instance one or two grains were found far away upon the surface. At 1" in a majority of cases a moderate number of grains are embedded

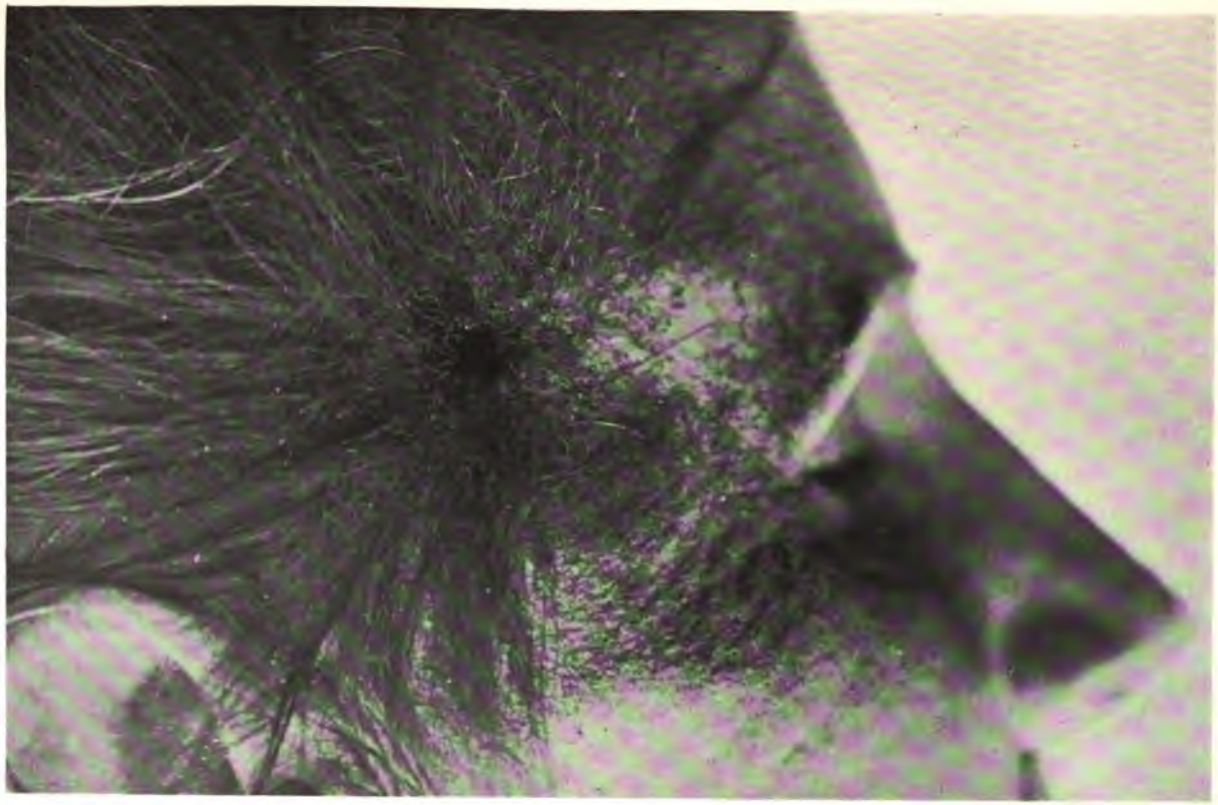

FIG. 16.—0.44 Cal. Range, 1". Smoke Stain over Supra-orbital Ridge, Scorching of Skin Anteriorly and Burning of Hair, Area of Embedded Grains Moderately Blackened.

in an area of ¼″ to 1″; in other cases from six to ten grains or even fewer may be sparsely scattered somewhat farther away from the wound; and in others still there are no grains embedded and none upon the surface. At 3″ the unburned grains are all embedded in an area of ¾″ to 1¼″, and in one case no grains remained unconsumed. At 6″ the area of implantation is extended to 1″ or 2″ in half the cases, and in the other half there may be not more than five or six grains altogether at uncertain distances from the wound. At these ranges, from contact to six inches, appreciable unburned grains free upon the surface are exceptional; such as have escaped combustion, if not fixed in the skin, are too few and too distant to be distinguishable. At one foot and two feet there were a very limited number of embedded grains in half the cases examined, but in all save one there were free unburned grains within an area of 3″ or less. At three feet and more no grains are embedded, and the few lying upon the surface are widely scattered, often over the whole side of the face and forehead. At twenty-five feet or more, unburned grains are no longer discoverable either upon the surface of the head or face or upon the underlying cloth.

The subcutaneous lesions are practically confined to a range of 1″ and less. At contact the blackened area may be either upon or beneath the temporal fascia, and measure from ¾″ to 2″ in diameter. The muscular tissue is often additionally powder stained and smoked through its substance, and the osseous surface similarly discolored, but laceration is infrequent. At 1″ the muscle is stained in three-fourths of the cases examined, but the more superficial layers are unaffected. At 3″ there is ordinarily

FIG. 17.—0.44 Cal. Range, 3". Smoke Area, Scorching of Skin and Singeing of the Hair, Free and Embedded Powder Grains.

nothing more than a discoloration of the ball track, though grains of powder may be sometimes detected in its course or upon the osseous margin, and a lead stain upon the temporal fascia is possible. At 6″ and more there are no evidences of the passage of the ball through the external parts outside its track, except for the not infrequent presence of particles or fragments of lead.

Grains of powder in the intracranial cavity are demonstrable at a range of 1″ or less, and may be exceptionally noted even at 6″. The amount of powder carried into the brain substance is small, and it penetrates the contiguous cerebral lobe only to a moderate distance. In one case at a range of 6″ only three grains were distinguishable. At contact the contiguous surfaces of calvarium and dura may be dotted with grains of powder over an area of 1″ or more, as in observations made with larger calibres of ball.

The detection of more or less finely comminuted fragments of bone in the course of the ball through the brain is possible at all ranges, but as the osseous wound is smaller the number is necessarily less than when the calibre is greater. It can probably not be recognized beyond the median cerebral fissure.

In formulating so great a number of experimental re sults, it has been thought unadvisable to present ea observation in detail, since a procedure so laborious and record so voluminous would be attended by no

FIG. 18.—0.44 Cal. Range, 6'. Burning of Hair, Trace of Smoke, Powder Grains Mainly Embedded.

trunk and extremities was discontinued beyond those made with balls of 0.38 cal., as peculiarities in effect, though slight, still existed, and conclusions as to the head might be open to just criticism if based upon them.

The results obtained from these observations of pistol-shot wounds of the head, made at corresponding ranges with balls of different calibres, have been so far condensed that no necessity exists for further generalization; but for convenience of comparison they may be somewhat abbreviated and differently formulated.

The wound of entrance, with all calibres of ball and at all ranges, except at contact or in certain instances in which impact is made upon a cranial curve, is smaller than the ball. Its diameter varies from $\frac{1}{16}''$ to $\frac{3}{16}''$, and its average is the same for each calibre except 0.44, for which it is perceptibly larger and for which a maximum of $\frac{1}{4}''$ may be attained.

Disintegrated brain matter may be forced into the wound of entrance, or may be extruded from it with more or less violence, at all ranges with all calibres of ball. It occurs in rather more than half the cases in the use of 0.32, 0.38, or 0.44 cal., and in rather less than half the number with 0.22 cal.

The staining of the skin by smoke at different ranges varies in its occurrence and extent with the use of different calibres of ball.

(*a*) 0.38 cal. A smoke stain upon the skin never occurs at firm contact; is invariable at a range of 6″ or less—except possibly when intercepted by thick hair, or when in rare instances a lacerated wound is inflicted at a range slightly beyond contact; is of uncertain presence at a range of from one foot to two feet; and is absent at greater

distances. At a range of 1″ and less it covers an area of 1¼″ to 2½″, and at a range of 3″ an area from 3″ to 5″ in diameter, and at both ranges includes a black area which is the result of smoke, burn, and the ingraining of finely divided grains of powder. At a range of 6″ it covers an area of 2½″ to 4″, and at a range of from one foot to two feet either covers a well-defined area of 1″ or is faintly diffused over a space of 5″ to 6″.

(*b*) 0.32 cal. A smoke stain is usually perceptible at contact, forms a distinct area from 1¼″ to 2½″ in extent at any range less than 6″, infrequently occurs and forms an area of 1½″ at one foot, and is only occasionally present as a mere trace at two feet.

(*c*) 0.44 cal. A smoke stain occurs at contact and at ranges less than two feet. At contact and at one foot it is faint and inconstant. At 3″ and less it is dense, covers an area from 2″ to 2½″ in diameter and is invariable. At 6″ it has the same density and area, but ceases to be invariable.

(*d*) 0.22 cal. A smoke stain covers an area of ⅛″ to ¾″ in diameter in 75 per cent. of cases at contact; may form a double ring of 1½″ to 3″ aggregate diameter at imperfect contact; extends over a space from 1″ to 4″ in diameter at a range of 1″ to 6″; exists only as a faint trace at one foot, and is absent altogether at greater distances.

Burning of the hair or skin occurs at contact with all calibres and is limited: with 0.44 cal. to a range of 15″, with 0.38 cal. to a range of 10″, with 0.32 cal. to a range of 6″, and with 0.22 cal. to a range of 3″. At the extreme limits it is confined to the edge of the wound or to the hair, and at intermediate ranges it additionally includes the burning, which is a factor in the production of the black area, or a still more extended scorching of the skin.

FIG. 20.—0.44 Cal. Range, 2 ft. Area of Powder Grains, Mainly Embedded.

The black area which is formed at a range of ½″ to 6″ with the 0.38 cal., or of ½″ to 3″ with the 0.32 cal., is from ⅛″ to ¾″ in diameter. The scorching of the skin in the use of the 0.38 cal. occurs in an area of 1″ to 1¼″, and of the 0.32 cal. in an area of ⅛″ to 1″. In a suicidal case reported in the accompanying series the burned and scorched area extended to a distance of nearly 2″ (0.32 cal.). The black area with 0.22 or 0.44 cal. is limited to ⅛″ and the scorching of the skin to 1″ and 1¼″ respectively.

Embedded grains of powder when the cartridge is of 0.38 cal. may be detected at ranges from ½″ to four feet, and unburned grains upon the surface at ranges from 6″ to just within thirty feet. The embedded grains may be confined to the composite black area, or cover a space of 6″, and at the longer ranges, from three to four feet, there may be none, or the number may vary from one or two to forty. The superficial free grains are numerous at ranges of from one to six feet and may cover the whole side of the face and neck; at longer ranges they may be absent, or may be not more than one or two in number. The embedded grains outnumber those which are free upon the surface at ranges less than two feet, are in variable proportion at that limit, and are fewer, if they exist at all, at longer ranges. When the cartridge used is of 0.32 cal. grains of powder are embedded at ranges from contact to three and one-half feet inclusive, and are left free upon the surface at ranges from 3″ to twenty-five feet. At a range of less than 3″ free grains may be sometimes discovered in the hair or upon the underlying cloth. The number of unburned grains is not generally less than with the 0.38 cal., and the areas which they cover and their relative numeri-

FIG. 21.—0.44 Cal. Range, 3 ft. Free and Embedded Powder Grains.

cal proportions are the same. When the cartridge is of 0.44 cal. the areas and relative numbers of embedded and superficial grains vary slightly with the type of pistol used. The ranges at which they are ingrained extend from ½″ to five feet, and the ranges at which they are deposited upon the surface of the skin or upon neighboring objects from contact to twenty-five feet. At ranges of less than 3″ the proportion of embedded grains is greater with the inferior weapon, and at ranges of more than 6″ is greater when the weapon is of the more efficient type. The areas covered by unburned grains are: at ranges of 3″ and less, ½″ to 1½″; at a range of 6″, 1½″ to 3″; at a range of one foot, 2½″ to 4″; and at ranges of three to five feet they include the whole side of the face. When the cartridge is of 0.22 cal. the unburned grains are fewer in number and inconstant at all ranges. They may be observed from contact to a range somewhat less than three feet for those which are embedded, and somewhat less than twenty-six feet for those which are free. The embedded grains are found in an area of less than 2″, and those upon the surface within an area of less than 3″. At ranges of more than three feet the superficial grains may be sparsely scattered over the whole side of the face and forehead.

The subcutaneous lesions with all calibres, at contact, include laceration of the tissues from the explosive effect of the bullet, and their blackening by smoke, burning, and power infiltration, together with some separation of the layers of the scalp, which usually occurs at the level of the temporal fascia. The laceration involves an area of 1″ to 2″. At ranges of 1″ to 2″ lesions are confined to

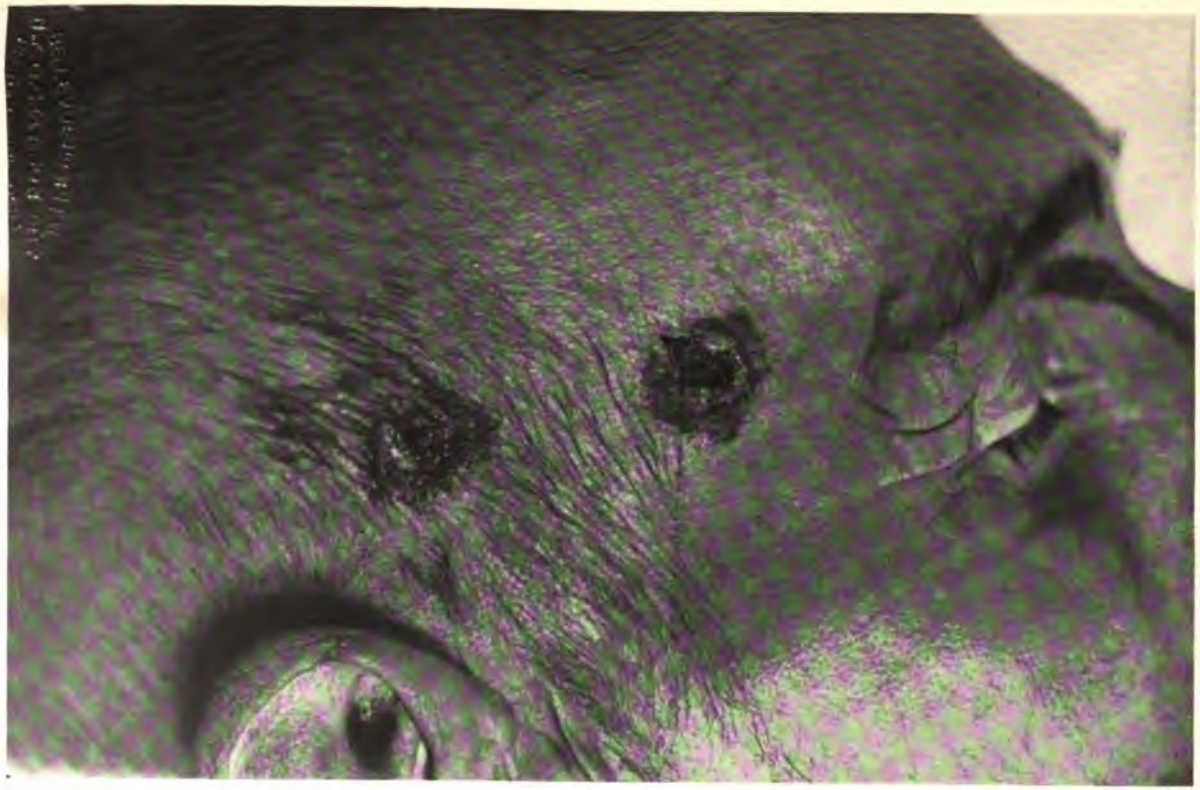

FIG. 22.—0.22 Cal. At Contact. Two Wounds, Smoked and Scorched Areas.

neurosis or temporal fascia, or of the margin of the osseous entrance, over an area of ¼″ to 2. At or beyond ranges of 3″ there is only an exceptional staining of the tissues outside the track of the ball. The extreme limit of range at which these changes occur is for 0.38 cal. of ball 6″, though possibly a few grains of powder may be carried into the temporal muscle at one foot; for 0.32 cal., not to exceed 3″; for 0.44 cal. 6″; and for 0.22 cal. not exceeding 1″. Fragments of lead and lead stains are frequent at all ranges and with all calibres of ball.

Grains of powder appreciable upon simple visual inspection may be carried through the osseous wound into the intracranial cavity with all calibres at contact and within a possible range of 6″. At contact they may be invariably detected, and perhaps with equal certainty at a range of 1″. At a range of 3″ their detection becomes doubtful, and at 6″ only exceptionally possible. At contact they may be found upon the contiguous surfaces of the calvarium and dura, and in large number through the whole length of the cerebral track and perhaps even through the external wound of exit. At a range of 1″ they are likely to be confined to the track through the contiguous cerebral lobe; and at 3″ or 6″, if they exist at all, they are few and isolated and near the osseous wound of entrance. Their number seems to be independent of the calibre of the ball, except at contact, when the correspondence is direct.

Fragments or particles of bone more or less finely comminuted are carried into the brain track with all calibres and at all ranges. The differences ob
have no essential or diagnostic importance.

These generalizations have bee

FIG. 23.—0.22 Cal. Range, 1'. Black Area Concealing Faint Scorching of the Skin, Three or Four Fine Powder Grains Embedded.

comprehensive to include conceivable variations in the effects of different weapons and cartridges upon different subjects under ordinary circumstances. They directly summarize the average results obtained from the use of factory-filled cartridges of the usual type at specified ranges. There are differences to be reckoned with in individual cartridges and in individual weapons, as there are in individual subjects and in attendant conditions. Cartridges and pistols of the same calibre vary in their effects, not only as they are the product of different makers, but as they are of different types and lengths, and each may have even individual peculiarities. Atmospheric conditions may affect cutaneous indications, as may accidental conditions of the surface, or as may physical properties dependent upon age, sex, or congenital conformation. Smoke will not be so densely deposited upon the surface in dry as in damp weather; the hair which is wet or smooth will not be so readily burned as will the hair which is dry and fluffy; the skin which is tough and resistant, or which is covered by thick hair, will not be so closely ingrained with powder as skin which is of softer texture or which is unprotected; and the pistol of antique fashion or the cartridge which is old or made of inferior powder will not have the same penetrative power, or occasion an external wound having the same characters, as will the products of most recent manufacture. It is not to be expected, therefore, that a ball of given calibre discharged at a given range will in every instance and under all circumstances produce exactly the same superficial lesions, or occasion precisely the same extent of cutaneous change from more or less perfect combustion

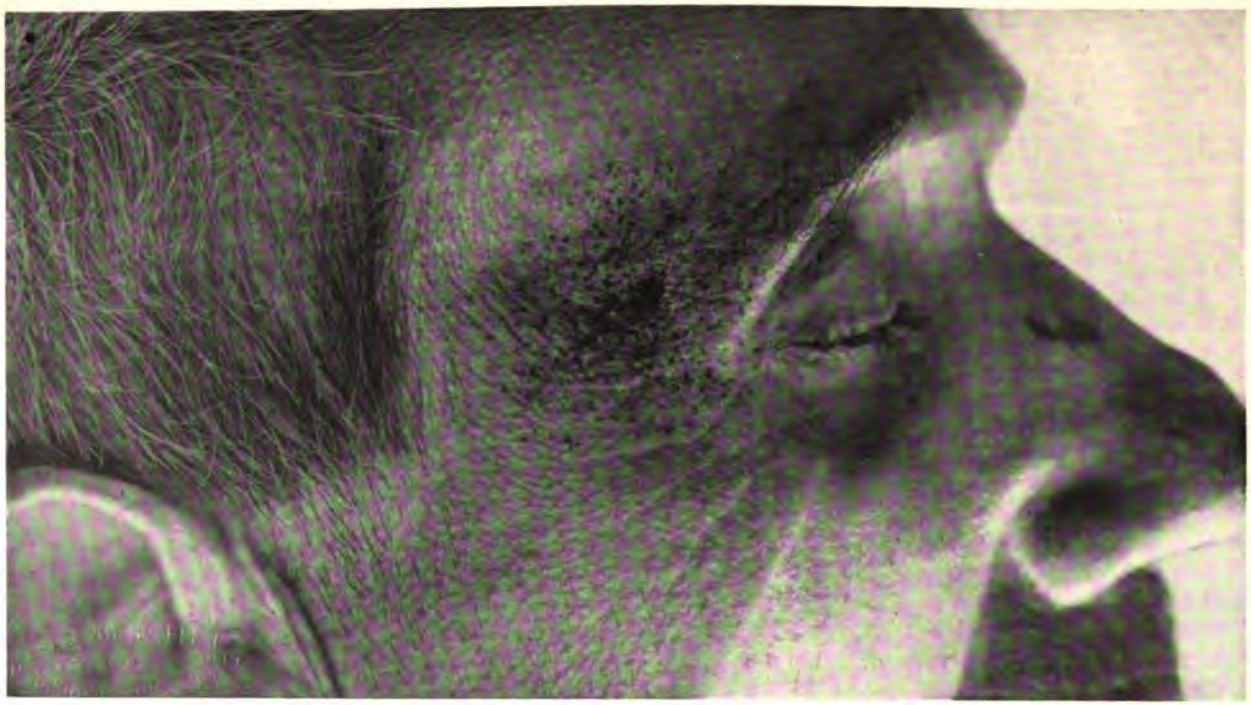

FIG. 24.—0.22 Cal. Range, 3″ Indistinct Smoke Area, Faint Scorching of Skin Anteriorly, Area of Free and Embedded Powder Grains.

paratively slight, and can be estimated with sufficient exactitude.

The averages which have been reached in the measurement of the degree and extent of superficial lesions were established primarily for pistols and cartridges of the highest grade in use for other than target purposes; but in the instance of each calibre a sufficient number of substitutions was made to demonstrate resulting variations in effect at practicable ranges. Such variations were generally trivial. The influence exerted by natural or accidental differences in the physical properties of the external parts, while often appreciable and sometimes considerable, was, in the great number of observations made, still insufficient materially to modify the general conclusions as originally formulated. In all essential particulars these may be regarded as established truths, so far as absolute general laws may be deduced from an aggregation of individual instances.

The characteristics of the external wound of exit are in general too well defined to demand formal or extended consideration. This wound is usually larger and more extensively lacerated, and contains a greater amount of disintegrated cerebral and subcutaneous tissue, than that of entrance. Its margin is everted, and everted osseous fragments may often be detected before or after its enlargement for more thorough examination. The adjacent cutaneous surface is devoid of marks of flame, smoke, or powder. These conditions are largely independent of range or calibre, but if calibre is large and range approximates contact, the destructive effects of the ball at exit will be emphasized, and unburned powder which has been driven through the brain may be found through and

FIG. 25.—0.22 Cal. Range, 6". Area of Free and Embedded Powder Grains, Trace of Smoke Detected only by Use of Damp Cloth.

even at the surface of the wound. If in any case doubt may conceivably exist, it may be resolved by comparison with the wound of entrance or by examination of the osseous lesion.

The question is pertinent as to how far lesions and indications produced in the post-mortem state correspond with those which are incident to traumatisms in the living subject. Differences undoubtedly exist, but they are manifest rather in the extent of such changes than in the range at which they occur. In a case of suicide, No. CXXXIX. of the annexed series of histories, in which the true skin was charred through its entire thickness, not only the degree but the superficial extent of burn was greater than in any of the cadaveric observations made, but it was still within the determined limit of distance from the wound. In general, burning of the skin occurs within the same limit of range, and is confined to the same area, upon the living as upon the dead subject; but while upon the cadaver it is no more than a mere staining of the surface, or possibly a destruction of the epidermis, during life the true skin may be involved and the whole structure be desiccated and hardened. The number of grains of powder embedded in the skin might very conceivably differ with the varying conditions of life and death, but the number of grains deposited upon the surface, or the occurrence of smoke stain, which depend solely upon the perfection of combustion within given

FIG. 26.—0.22 Cal. Range, 1 ft. Free Powder Grains and Six Embedded.

post-mortem experimentation. The instances of gunshot wounds of the head included in the accompanying series of intracranial injuries suggest no greater discrepancies in superficial appearances than have been indicated when such wounds are inflicted after death.

The enumerated alterations suffered by the external soft parts, in structure, or appearance, are not equally constant factors in the estimation of calibres or ranges. The more or less forcible extrusion of brain substance through the external wound, or the projection of bone fragments through the cerebral track of the ball, have in this regard no diagnostic value, since they are possible at all ranges with balls of all calibres. The deposition of unburned grains of powder upon the skin or surrounding surfaces, though of great importance when observed, is probably in the great majority of instances in which it has occurred unavailable as a means of determining either of those points in diagnosis. They are so readily displaced and lost upon the surface of the earth or elsewhere, and the body is so certain to have been disturbed before expert examination can be made, that their recognition can be scarcely more than fortuitous, even in the cases in which they have been most abundantly precipitated. So, too, the powder grains which have been driven into the cerebral substance by the force of the explosion, and are readily recognizable in cadaveric experimentation, are so concealed by intracerebral hemorrhage that they are more than likely to escape detection. The smoke stain is very generally washed away, either by external hemorrhage or by the application of water in a sometimes misguided effort to render the appearance of the wounded man presentable upon the arrival of the surgeon or of the under-

FIG. 27.—0.22 Cal. Range, 2 ft. Free Powder Grains upon Side of Face.

taker. The original characters of the external wound, finally, are not infrequently changed in an early attempt at exploration and their significance is lost. Notwithstanding the slender probability that certain characteristic conditions of pistol-shot wounds which have been specified can be utilized for determining the circumstances under which they have been produced, it may well happen in any case that some one of them may remain sufficiently in evidence to make clear an otherwise doubtful history. Other conditions of such wounds and attendant lesions of the skin which have been subjected to experimental investigation in the cadaver may be reasonably expected to afford, in every instance, either positive or negative evidence of the size of the ball, or of its range. The superficial wound of entrance, though liable to surgical interference and alteration prior to observance of its original characteristics, is oftener left intact for proper medico-legal examination; or, as it may chance, the peculiarities of the primary wound may be discerned through the secondary changes which have been made in its extent and conformation. The burning of the hair or skin involves structural changes, and, however trivial it may be, its traces can hardly disappear before opportunity is afforded for their discovery. The grains of powder which are fully embedded in the skin can be removed only with difficulty and by direct design, and their presence or absence must have a definite value in the estimate of every case which demands investigation. The subcutaneous lesions of the scalp, if they exist outside of the track of the ball, involve structural changes which cannot be altogether obscured, even by inexpert examination or exploration of the wound.

It must not be expected that typical cases of pistol-shot wound will be often encountered in which there will be a complete and symmetrical presentation of all the possible superficial alterations which indicate the range at which they were inflicted or the calibre of the ball. Conclusions must be reached here as on other lines of surgical inquiry, from the study not of complete pictures, but of fragments, and may be as positive as the much-quoted results which have been similarly attained in the field of comparative anatomy. A single indication may be all that is necessary. The fact that the skin has been scorched is sufficient evidence that, whatever the calibre of the ball, the range of fire has been not more than six inches, just as the ingraining of the skin with powder is that it has not been more than five feet. Confirmation is probable through the presence or absence of some other indication, but without it the single fact, uncontroverted, remains sufficient.

Indications of range and calibre may exist which are of apparently contradictory import. Their reconciliation is probably always possible and involves the recognition of the established limits within which their variations may legitimately occur, and, it may be, some experience in their observation. The difficulties which such cases present are not insuperable, and not usually greater than those incident to the solution of other medico-legal problems.

It is scarcely possible to overestimate the medico-legal importance which attaches to these anatomical considerations connected with the infliction of pistol-shot wounds of the head. The instances in which the ball has passed quite through both cranium and soft parts, and been absolutely lost, or in which the distance it has traversed

can be gauged only by the nature of the wound which it has inflicted, or by the traces it has left upon the surface, are of great frequency. Its size or its range, thus indirectly determined, may perhaps solve the question of accident, suicide, or homicide; and the vindication of innocence or the punishment of guilt may rest solely upon the possibility of fixing with precision the nature and extent of the superficial lesions, and upon the correct interpretation of the indications which they afford.

The grave responsibility incurred by the expression of expert opinion in cases of known or suspected homicide can be justifiably assumed only after rigorous investigation and careful consideration of all the anatomical facts and their comparison with established data. Cadaveric observations, if practicable, might well be made with the pistol which has been the instrument of death, and with cartridges similar to the one it carried; but it is not certain that more definite ground for opinion will be found in special and, it may be assumed, limited experimentation than in the comprehensive series of observations which have been here collated, though its results might conform more closely to the technicalities of judicial requirement. If such special experiments are to be undertaken for the elucidation of a particular case, an adequate number of heads should be assured, the use of which may be economized by accepting data already acquired in order to limit the field of special inquiry. The effects of balls upon paper targets are not admissible in evidence, as they are not comparable with those which are observed upon the human skin, and body shots at the same range are not precisely the same in their characters as those inflicted upon the head. As in no case except with balls of

the smallest calibre can more than two or three observations be made upon the same head, and if the ball is of large calibre and is fired at short range probably not more than a single one, and as observations must be largely multiplied to justify positive conclusions, it follows that unless anatomical material is fully at command, it is ordinarily safer to interpret the phenomena presented in a given case by a comparison with the aggregate results of previous clinical and experimental experience. In case of wounds inflicted by weapons which are now of unusual calibre, as 0.30 or 0.25, it will be safe to make the ascertained effects of the approximate standard calibre the basis of comparison. The range at which with a ball of 0.30 cal. the skin ceases to be burned, or at which powder grains are no longer embedded, will be less than with one of 0.32 cal., and with a ball of 0.25 cal. the range within which these effects are possible will be somewhat greater than with one of 0.22 cal. The problem to be solved is usually that of the possibility of suicide in cases in which homicide is suspected, and as in homicide the range is usually within that in which suicide is practicable, and within which superficial effects are not essentially different for approximate calibres, sufficient accuracy will be assured.

The number of instances in which cadaveric observation can be made decisive in determining the exact conditions under which wounds have been inflicted during life is by no means large, but this restriction cannot be taken as a measure of its value. The absolute certainty that there is no range within which a suicidal bullet wound might not have been homicidal, and that in the vast majority of cases no evidence afforded by necropsy can discriminate the one from the other, is in its application to indi-

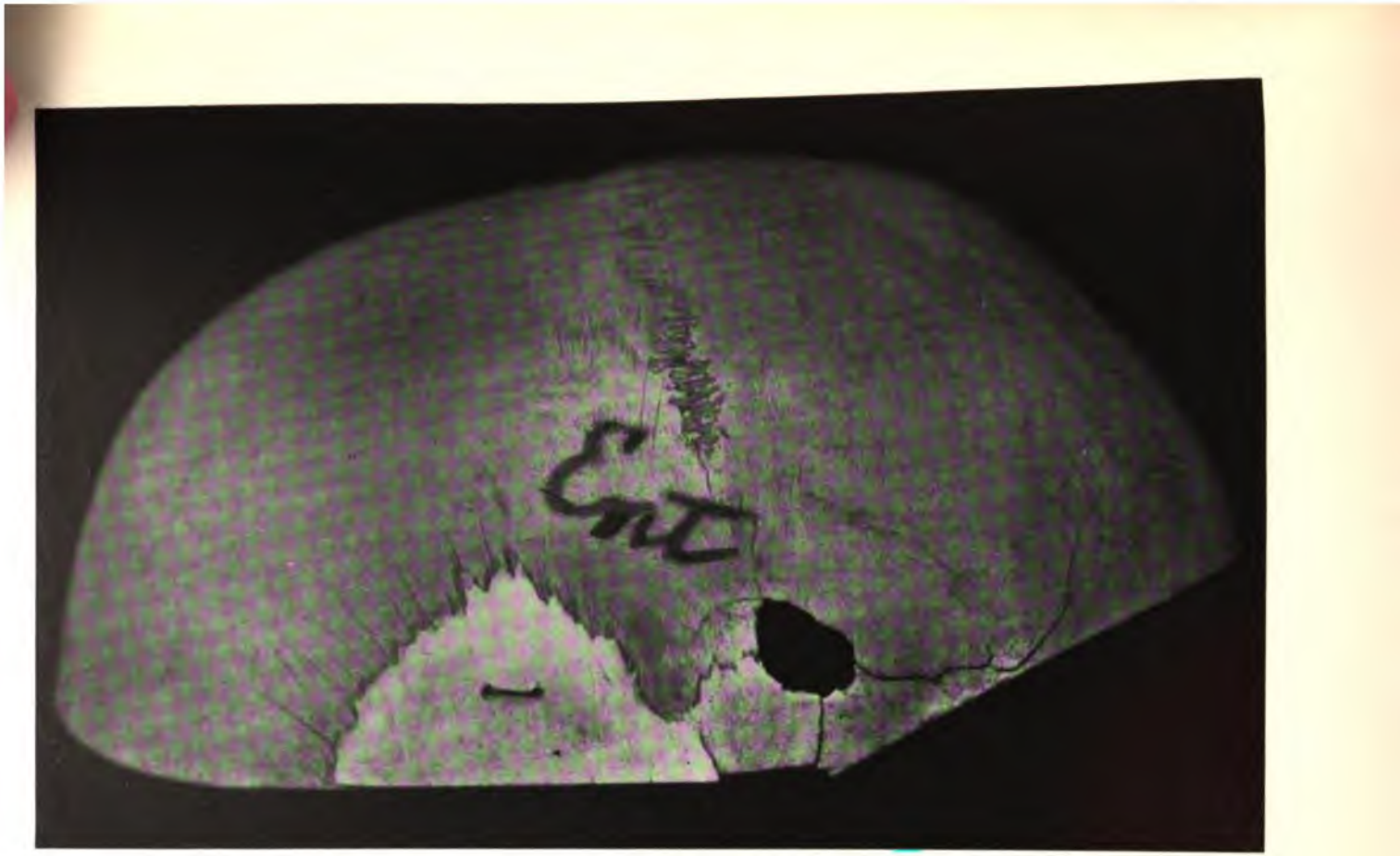

FIG. 28.—0.38 Cal. Short Range. Suicide. Osseous Entrance of Ball.

vidual cases no less important as a negative conclusion than the positive fact that in certain exceptional cases the wound is necessarily homicidal. It is only by largely extended experimentation that the line which separates these two classes of cases can be accurately defined.

Cranial Lesions.

The osseous wounds of entrance and exit present certain peculiarities which are invariable, whatever may be the calibre of the ball which has produced them or the range at which they have been inflicted. There are instances, not infrequent, in which the cranial lesions may determine both range and calibre, but in general they have few characteristics absolutely indicative of either. The characters which they have in common are an osseous opening larger than the ball and an unequal comminution of the osseous tables, which has a definite relation to its direction. The wound of entrance is usually not very much larger than the ball, and may thus absolutely determine its calibre. The diameter of a circular perforation of the bone made by a ball of 0.22 cal. may be smaller than that of the ball itself of any of the larger calibres; and the diameter of a similar perforation when made by a ball of 0.44 cal. may be larger than any which has been observed with balls of smaller size. Irregular or even circular openings when made by balls of 0.32 or 0.38 cal. are individually indistinguishable from each other, as they may be even from those of 0.22 or 0.44 cal. The direct osseous wound is usually made by a fine comminution, but instances are observed in which a circular piece is punched out of the bone and perhaps remains attached to

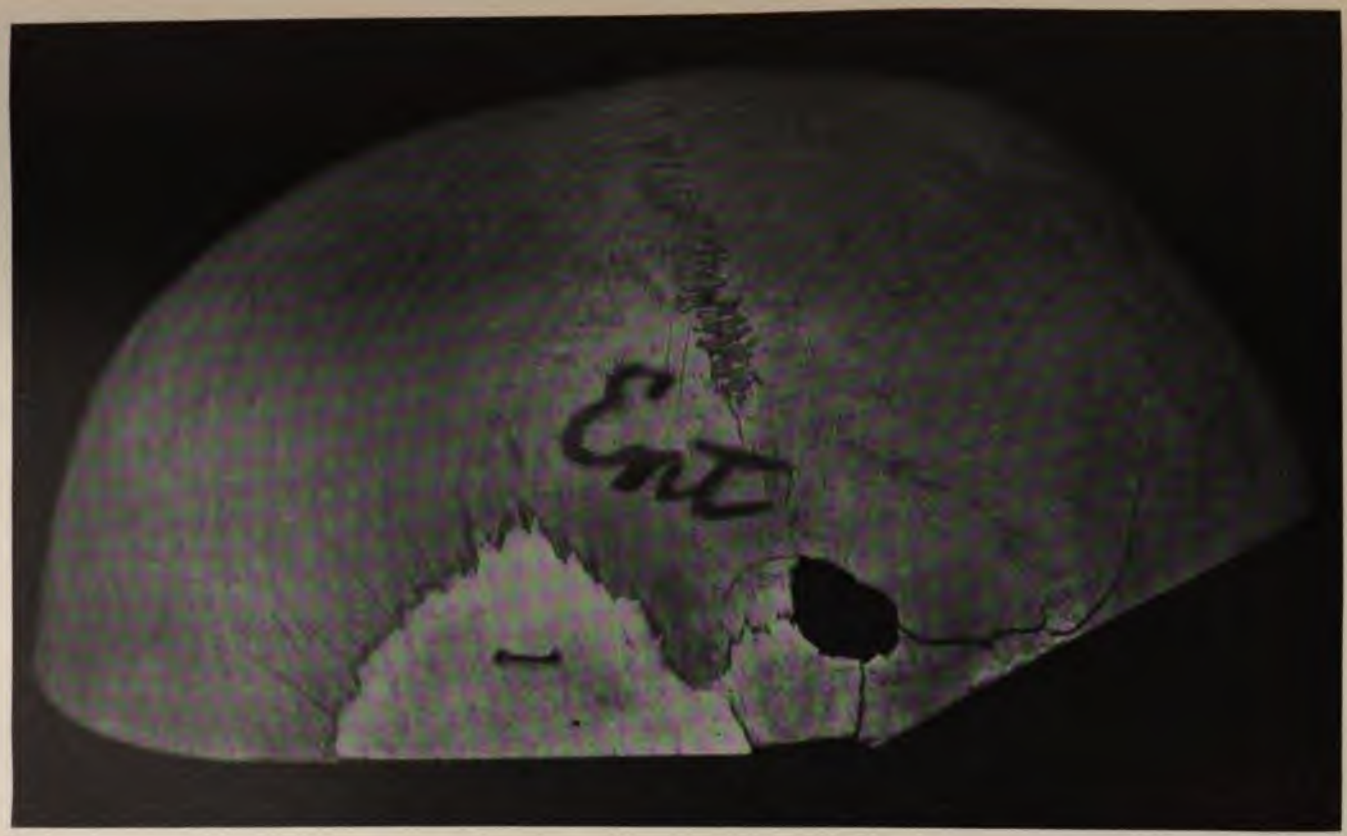

FIG. 28.—0.38 Cal. Short Range. Suicide. Osseous Entrance of Ball.

the dura. The wound of exit, in which comminution is more extensive and involves larger fragments, can hardly afford in any case a clew to the calibre of the ball.

The unequal comminution of the two tables is not only observed at all ranges and with all calibres, but occurs in all regions of the cranium where two osseous tables exist. At the site of entrance the edge of the external table is sharp and clean cut, while the margin of the internal table, to an extent of $\frac{1}{8}''$ more or less, is eroded by fine comminution. This erosion of the margin of the inner table has the appearance of having been produced by the gnawing of small teeth or by the use of a fine rongeur, and is very characteristic. At the site of exit, when the bone is not too extensively comminuted for observation, these conditions are reversed; the margin of the inner table is clean cut, and that of the external table eroded.

The exact diagnostic value to be attributed to other circumstances of cranial injury may be best appreciated by a study of the results of observation arranged in statistical form.

1. *Cranial Penetration.*

(*a*) 0.44 cal. Pistol of most efficient type.

41 observations.

40 penetrations—40 exits.

1 non-penetration at range of 30 ft.,

with the point of incidence just above the supraorbital ridge and with one fragment of the ball within the external table.

1 exit not cutaneous.

Ranges, from contact to 100 ft., inclusive, in frontal, temporal, parietal, and occipital regions.

FIG. 30.—0.32 Cal. At Contact. Osseous Wound of Entrance.

(*b*) 0.44 cal. Pistol of inferior type.

34 observations.

19 penetrations.

6 exits, and

4 cases in which without exit the bone was fractured and the ball fell back into the brain, at ranges of contact, 6″, 5 ft., and 20 ft.

15 non-penetrations:

1 at range of 1 in.	1 at range of 10 ft.
1 " " " 6 "	3 " " " 30 "
2 " " " 1 ft.	1 " " " 40 "
1 " " " 3 "	1 " " " 50 "
1 " " " 5 "	3, range not noted.

These involved all regions of the cranium.

The ranges at which exit occurred were:

At contact, 1.	At 50 ft., 1.
" 3 in., 1.	" 75 ft., 1.
" 20 ft., 1.	" 100 ft., 1.

The ranges at which penetration occurred without exit were from contact to 50 ft. inclusive.

(*c*) 0.38 cal.

114 observations.

106 penetrations—75 exits.

8 non-penetrations.

Non-exits:

0 at contact with 10 observations.

2 at range of ½ to 1 in. with 17 observations.

1 " " "	3 " "	7	"
8 " " "	6 " "	16	"
2 " " "	1 ft. "	9	"

FIG. 30.—0.32 Cal. At Contact. Osseous Wound of Entrance.

14	at	range	of	6	in.	with	18	observations.
11	"	"	"	1	ft.	"	17	"
4	"	"	"	2	"	"	12	"
6	"	"	"	3	"	"	6	"
2	"	"	"	3½	"	"	2	"
2	"	"	"	4	"	"	3	"
8	"	"	"	5	"	"	8	"
5	"	"	"	6	"	"	7	"
1	"	"	"	10	"	"	3	"
2	"	"	"	15	"	"	2	"
2	"	"	"	20	"	"	2	"
3	"	"	"	25	"	"	5	"
2	"	"	"	30	"	"	2	"

A large proportion of the exits were not cutaneous.

Non-penetrations:

1	at	range	of	3	in.	in	mid-frontal	region.
2	"	"	"	6	"	"	"	"
1	"	"	"	1	ft.	"	"	"
1	"	"	"	1	"	"	mastoid	region.
1	"	"	"	3	"	"	inferior occipital	region.
1	"	"	"	4	"	"	"	"
1	"	"	"	4	"	upon	temporal	ridge.
1	"	"	"	5	"	in	mid-temporal	region.
1	"	"	"	6	"	"	posterior parietal	region.

It will be observed that failure of penetration with this, as with 0.38 cal. usually occurred in regions in which the resistance offered by the cranial wall is greatest, or upon curves which favor the deflection of the ball.

(*e*) 0.22 cal.

163 observations.

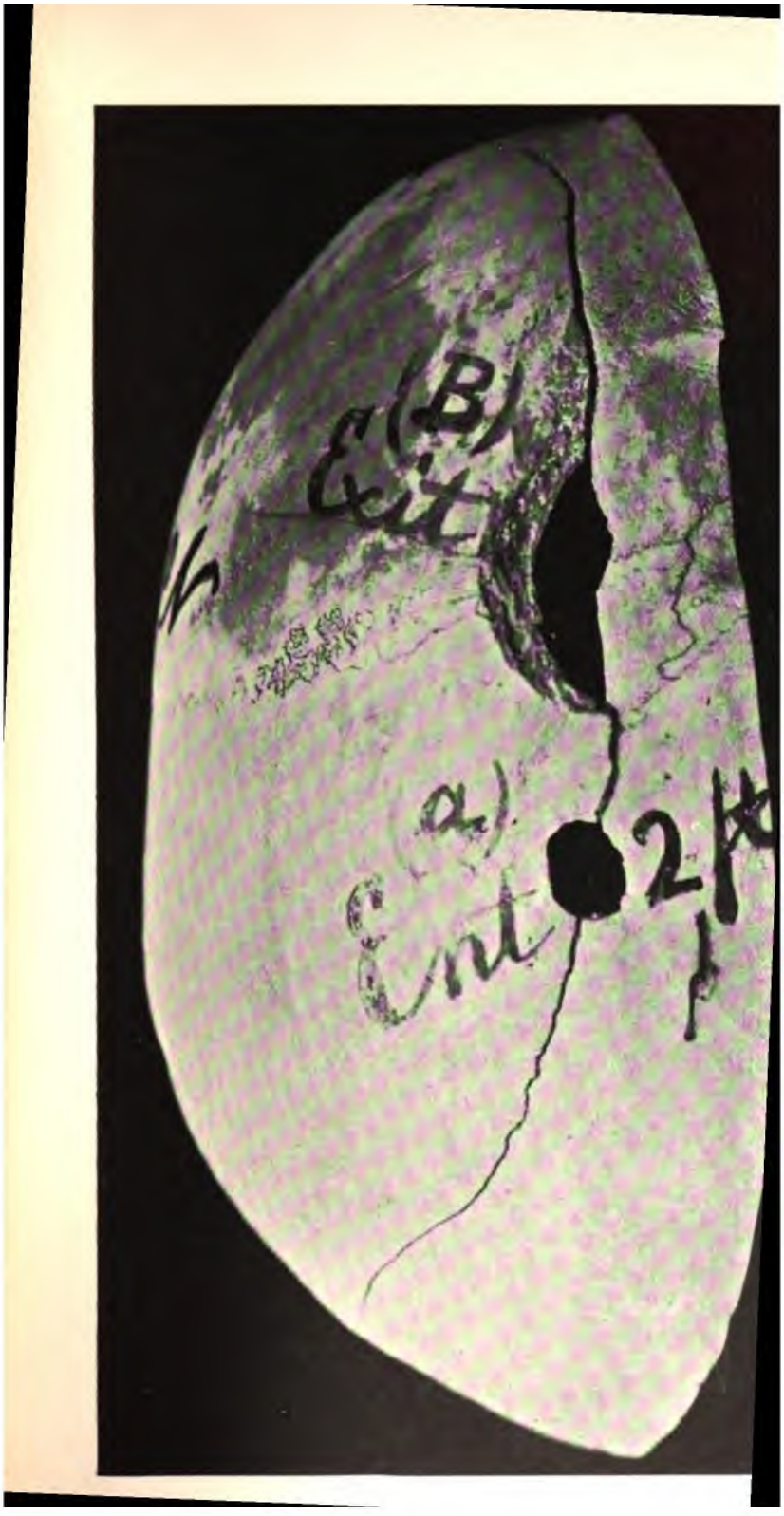
(B)
(a)

14	at	range	of	6	in.	with	18	observations
11	"	"	"	1	ft.	"	17	"
4	"	"	"	2	"	"	12	"
6	"	"	"	3	"	"	6	"
2	"	"	"	3½	"	"	2	"
2	"	"	"	4	"	"	3	"
8	"	"	"	5	"	"	8	"
5	"	"	"	6	"	"	7	"
1	"	"	"	10	"	"	3	"
2	"	"	"	15	"	"	2	"
2	"	"	"	20	"	"	2	"
3	"	"	"	25	"	"	5	"
2	"	"	"	30	"	"	2	"

A large proportion of the exits were not cutan

Non-penetrations:

1	at	range	of	3	in.	in mid-frontal region.	
2	"	"	"	6	"	"	"
1	"	"	"	1	ft.	"	"
1	"	"	"	1	"	"	mastoid region.
1	"	"	"	3	"	"	inferior occipital regio
1	"	"	"	4	"	"	" " "
1	"	"	"	4	"	upon temporal ridge.	
1	"	"	"	5	"	in mid-temporal region.	
1	"	"	"	6	"	"	posterior parietal regio

It will be observed that failure of penetration w as with 0.38 cal. usually occurred in regions in w resistance offered by the cranial wall is greatest. curves which favor the deflection of the ball.

(*e*) 0.22 cal.

163 observations.

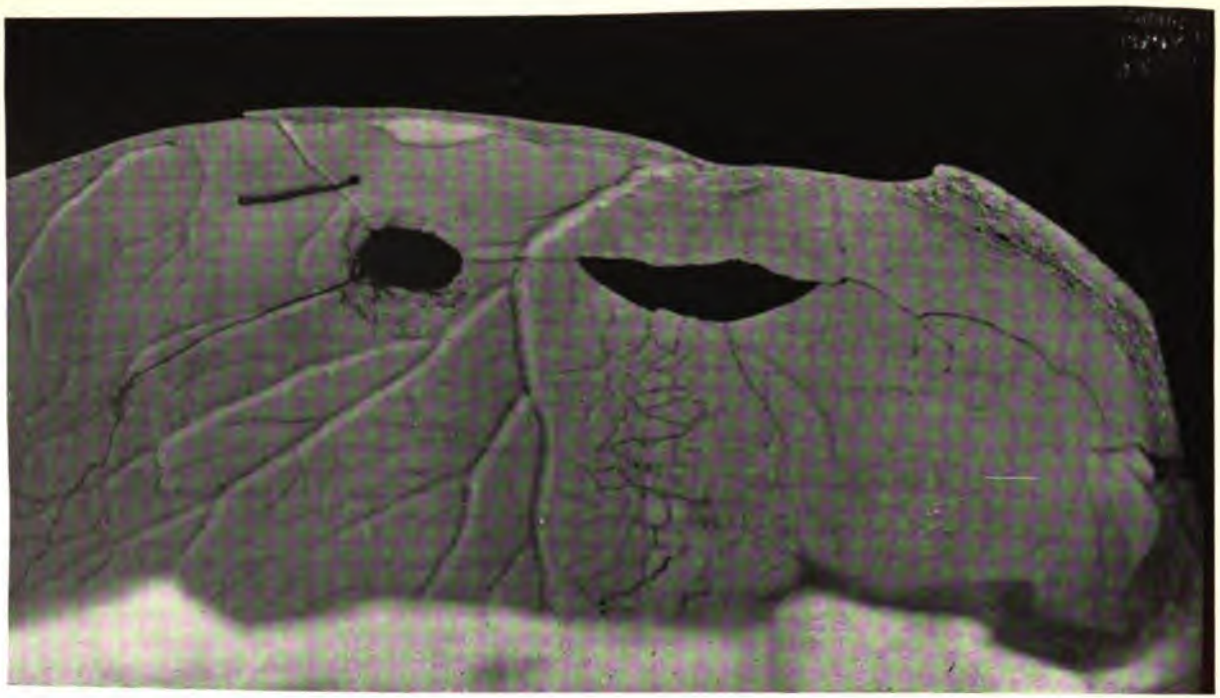

FIG. 32.—0.32 Cal. Same Shots as in Fig. 31. Osseous Entrance and Exit through Inner Table of Same Side of Calvarium.

In a first series of 30 observations there were but 11 penetrations, and in 6 of these the dura mater was uninjured. As all cartridges of 0.22 cal. are rim fire and deteriorate with age, it is probable that those used in this instance were old and in bad condition. In a second series comprising 133 observations, there were 100 penetrations. Both series were at ranges from contact to 25 feet, inclusive, and involved the frontal, temporal, and occipital regions, as did the previous observations made with other calibres. In the second series there were:

At a range of	contact,	5	penetrations	in	7	observations.		
"	"	"	1 in.,	12	"	"	14	"
"	"	"	3 "	15	"	"	21	"
"	"	"	6 "	14	"	"	15	"
"	"	"	1 ft.,	13	"	"	16	"
"	"	"	2 "	11	"	"	15	"
"	"	"	3 "	8	"	"	12	"
"	"	"	4 "	2	"	"	2	"
"	"	"	6 "	6	"	"	12	"
"	"	"	10 "	10	"	"	15	"
"	"	"	15 "	2	"	"	2	"
"	"	"	20 "	1	"	"	1	"
"	"	"	25 "	1	"	"	1	"

There were no exits, and only one instance in which the opposite surface of bone was fractured.

The fact of cranial penetration or non-penetration depends not only upon range and calibre but upo
comitant circumstances of even greater importance.
are pistols of inferior grade with which penetrat
always uncertain if not improbable; many of those o
cal. are of this character, and the cheaper varieti

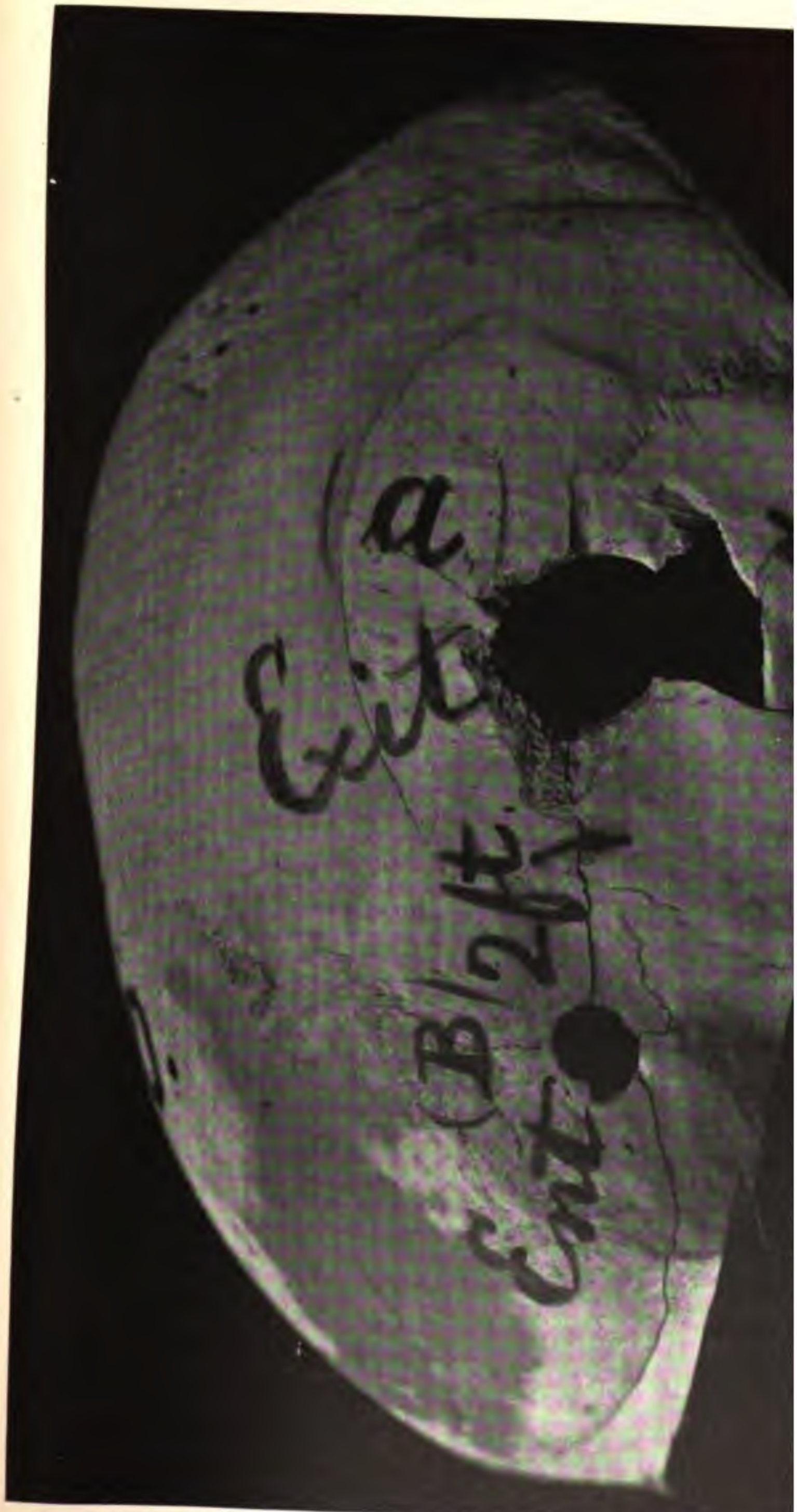

Exit
a
B 1/2 ft.
Ent.

0.44 cal. are scarcely more efficient. In observations made with what is termed an "American bulldog" of 0.44 cal. penetration occurred in but little more than 50 per cent. at all ranges, while in those made with a pistol of the same calibre of the highest grade it failed in but a single instance. It is necessary therefore to found such conclusions as may seem justifiable only upon the results attained in the use of weapons of standard type. The physical characters of the crania assailed, *per contra*, may be such as abnormally to increase their power of resistance. Their density not less than their comparative thickness, and the absence of diploic structure, often render them impenetrable even to balls of large size at short range. The impact of a ball upon a cranial curve, or at an angle of great obliquity, may determine its deflection from the surface. These several considerations make it difficult to formulate any exact rules which may govern penetration for balls of given calibres at stated distances. In general, the larger the calibre of the ball, other conditions being the same, the greater the probability of penetration. The truth of this proposition is evident from the present series of tabulated results. The influence of range can be less positively stated. It is probable that with any pistol, except it be one of 0.22 cal., penetration rarely fails at contact; that with a pistol of 0.44 cal., of the better type, it always occurs at a range of one foot or less, except in rare instances in which cranial peculiarities or the angle of incidence afford obvious explanation; that with a pistol of 0.32 calibre it is practically cert but the conditions are too complicated for mathemat expression. The ball has invariably made exit at all rang when of the best type of 0.44 cal., and never at any range

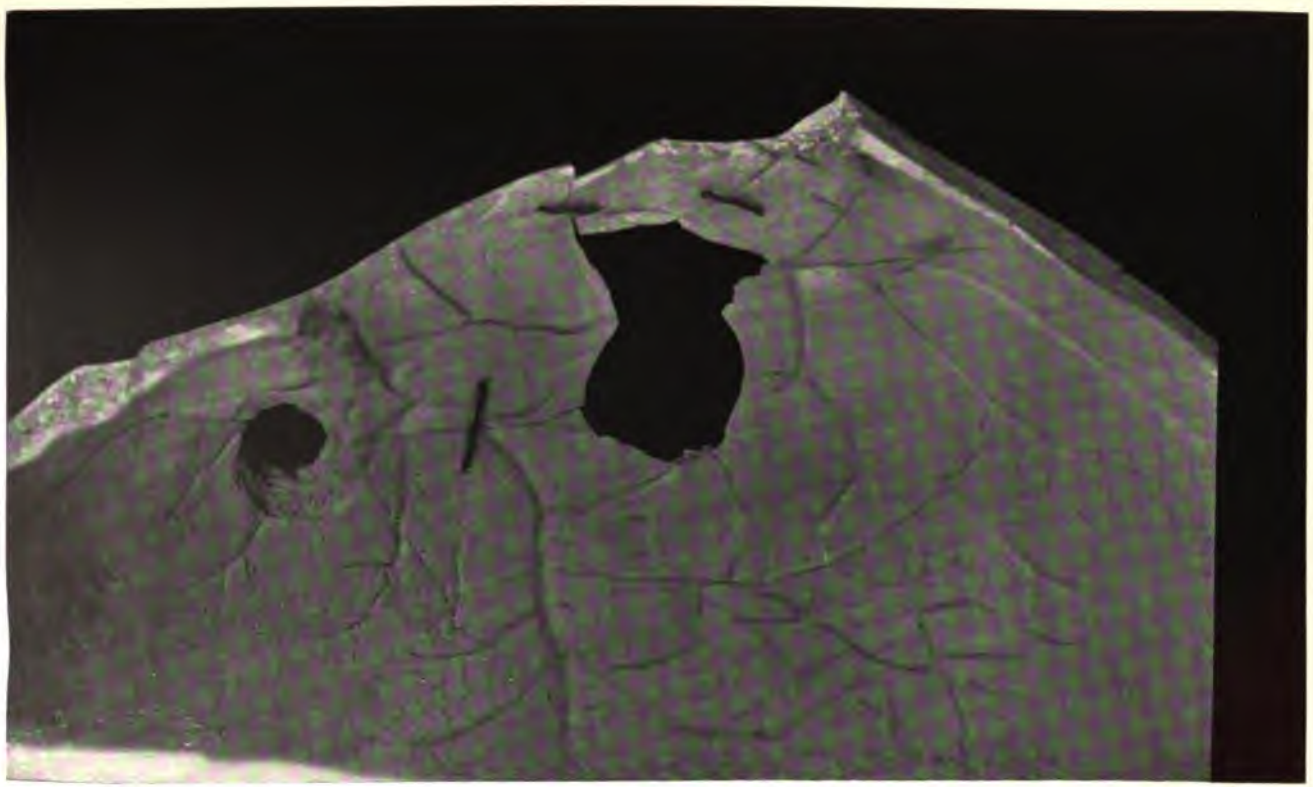

FIG. 34.—0.32 Cal. Same Shots as in Fig. 31. Osseous Entrance and Exit through Inner Table of Opposite Side of Calvarium.

when of 0.22 cal. Exit, like penetration, with balls of 0.32 or 0.38 cal., is influenced by accidental conditions and made to some extent uncertain. The average number of exits with balls of 0.38 cal. is 70 per cent. or more, and with those of 0.32 cal. less than 35 per cent.

2. *The Dimensions of Cranial Wounds.*

Measurements were made of the cranial wounds of entrance and exit in 308 observations.

The wound of entrance was apparently unaffected in size or form by length of range. It was circular in 123.

0.44 cal.—45 observations.

Range, from contact to 100 feet:

In	14	obs.,	diam.	$\frac{1}{2}$	in.	In	1	obs.,	diam.	$\frac{3}{4}$	in.
"	4	"	"	$\frac{7}{16}$	"	"	1	"	"	$\frac{7}{8}$	"
"	1	"	"	$\frac{5}{8}$	"	"	1	"	"	1	"

Total, 22.

In the 23 observations remaining, the diameters varied from $\frac{1}{2}'' \times \frac{7}{16}''$ to $\frac{1}{2}'' \times 1\frac{1}{4}''$.

0.38 cal.—75 observations.

Range, from contact to 100 feet:

In	18	obs.,	diam.	$\frac{3}{8}$	in.	In	2	obs.,	diam.	$\frac{5}{8}$	in.
"	4	"	"	$\frac{1}{2}$	"	"	3	"	"	$\frac{7}{16}$	to 1 in.

Total, 27.

In the 48 observations remaining, the diameters varied from $1\frac{1}{4}'' \times \frac{7}{8}''$ to $\frac{7}{16}'' \times \frac{3}{8}''$.

FIG. 35.—0.44 Cal. At Contact. Osseous Wound of Entrance.

0.32 cal.—96 observations.

Range, from contact to 30 feet:

In	16	obs.,	diam.	3/8	in.	In	1	obs.,	diam.	1 in.
"	5	"	"	1/2	"	"	3	"	"	1/4 "
"	4	"	"	5/8	"	"	3	"	"	5/16 "
"	1	"	"	7/8	"	"	1	"	"	7/16 "

Total, 34.

In the 62 observations remaining, the diameter varied from $\frac{5}{8}'' \times \frac{1}{2}''$ to $\frac{3}{8}'' \times \frac{1}{4}''$.

0.22 calibre—92 observations.

Range, from contact to 20 feet:

In	24	obs.,	diam.	1/4	in.	In	7	obs.,	diam.	3/8 in.
"	5	"	"	5/16	"	"	1	"	"	7/16 "
"	3	"	"	3/16	"		Total, 40.			

In the 52 observations remaining, the diameter varied from $1'' \times \frac{3}{4}''$ to $\frac{1}{4}'' \times \frac{3}{8}''$.

The number of wounds of entrance which are circular is thus much more than one-third of all those subjected to measurement; those of the remainder which are nearly so add materially to the percentage and do not affect the average of diameters. These circular wounds may be properly regarded as characteristic of the several calibres, while those of irregular form indicate secondary comminution. In the case of balls of 0.44 cal. the diameter of more than 75 per cent. of circular osseous wounds of entrance is $\frac{1}{2}''$, or a trifle less; in the case of those of 0.38 cal. it is $\frac{3}{8}''$ in 66 per cent.; in the case of those of 0.32 cal. it is also $\frac{3}{8}''$ in nearly 50 per cent.; and in

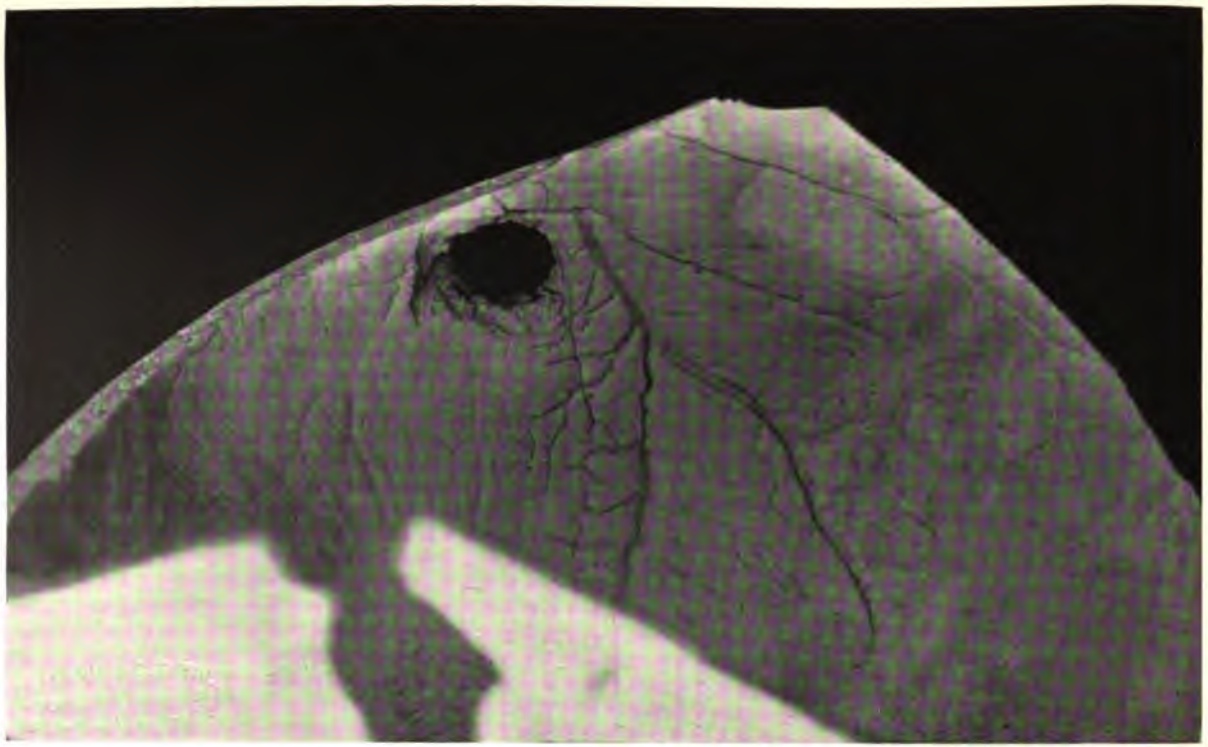

FIG. 36.—0.44 Cal. Range, ½". Osseous Wound of Entrance through Inner Table, Erosion.

the case of balls of 0.22 cal. it is $\frac{1}{4}''$, or a trifle more, in nearly 75 per cent. The osseous wounds when circular are the result of a fine comminution of bone by the ball in its progress—so fine that no part, or an inconsiderable part of it, may be detected in the intracranial cavity. Even if the wound is more than double the diameter of the bullet, no osseous particle of appreciable size may exist either within or without the cranial opening. In occasional instances, in place of this species of disintegration, a single circular fragment may be punched out and remain attached to the dura mater. It is not impossible that in every case the bone may be sufficiently compressible to permit some further enlargement of the wound.

The size of cranial wounds of exit is difficult to describe, as they are irregular in outline and as there is no means of discriminating, what may be termed direct from attendant or complicating comminution. The only practicable method of limitation seems to be to regard only those fragments as constituting a part of the wound which are of small size and in immediate relation with the course of the ball.

In the 308 observations there are 43 exits, of which the longest diameters are tabulated:

a. 0.44. cal.

In	1	obs.,	diam.	2	in.	×	3	in.
"	1	"	"	2	"	×	2	"
"	3	"	"	2	"	×	1	"
"	1	"	"	1½	"	×	1½	"
"	1	"	"	1½	"	×	1	"
"	4	"	"	1½	"	×	¾	"

FIG. 37.—0.44 Cal. Range, ½'. Same Shot as in Fig. 36. Osseous Wound of Entrance through External Table; Comminution.

In	3	obs.,	diam.	1	in.	×	1 in.
"	2	"	"	1	"	×	¾ "
"	1	"	"	¾	"		

Total, 17.

b. 0.38 cal.

In	1	obs.,	diam.	2	in.	×	1¼ in.
"	1	"	"	1¾	"	×	1¼ "
"	1	"	"	1½	"	×	1½ "
"	1	"	"	1¼	"	×	¾ "
"	1	"	"	1¾	"	×	1 "
"	5	"	"	1½	"	×	1 "
"	2	"	"	1½	"	×	1¼ "
"	1	"	"	1⅛	"	×	¾ "
"	1	"	"	1¼	"	×	1 "
"	1	"	"	1⅛	"	×	1 "
"	1	"	"	1	"	×	1 "

Total, 16.

c. 0.32 cal.

In	1	obs.,	diam.	2	in.	×	¾ in.
"	1	"	"	1½	"	×	1¼ "
"	2	"	"	1½	"	×	1 "
"	1	"	"	1½	"	×	½ "
"	2	"	"	1¼	"	×	1 "
"	1	"	"	1	"	×	1 "
"	2	"	"	1	"	×	¾ "

Total, 10.

d. 0.22 cal.

No exits occur; in only a single instance the bone was fissured by the impact of the ball at a point opposite its entrance.

The size of the osseous wound of exit is not materially influenced by the length of range, and while its average

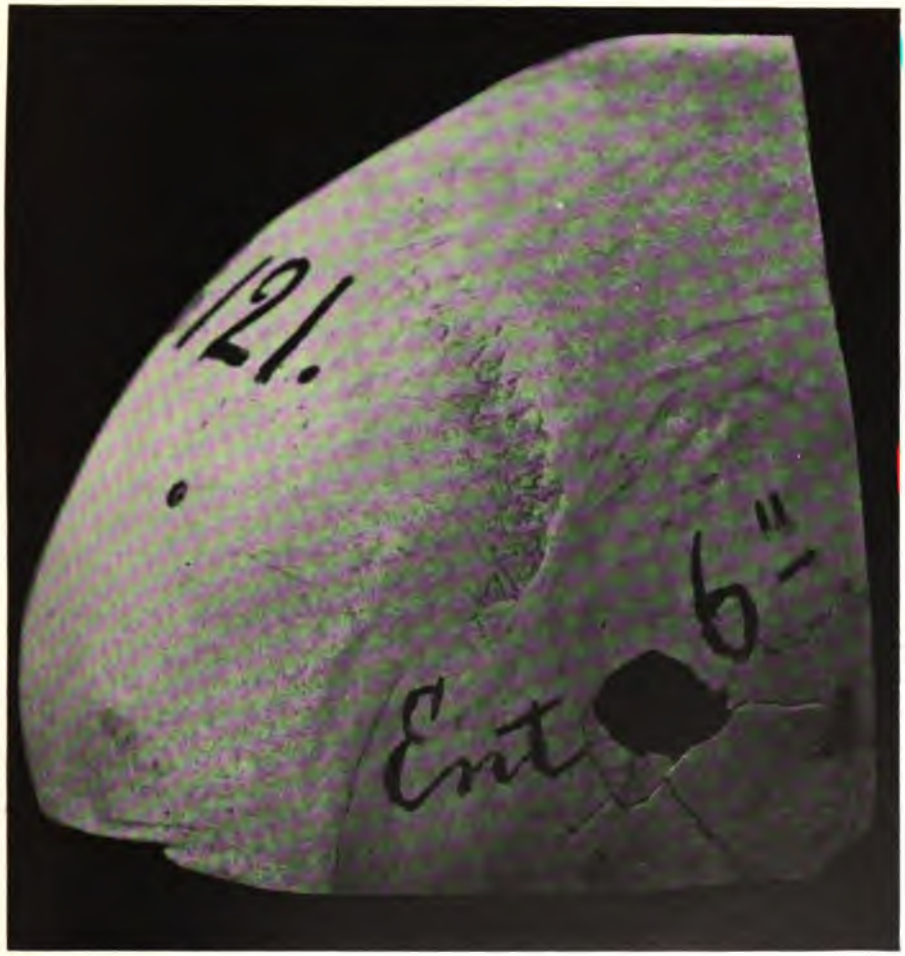

FIG. 38.—0.44 Cal. Range, 6'. Osseous Wound of Entrance through External Table

is somewhat increased with the calibre, the differences are insufficient to be of value in the determination of doubtful cases.

3. *Cranial Comminution and Fissuring.*

Comminution or fissuring of the skull may occur either at entrance or at exit, or at both points at once. The comminution of the wound of entrance usually consists, where the bone is thin, as in the temporal fossa or squamous region, in a limited and unimportant breaking down of the immediately contiguous part; and where the bone is thicker in a slight scaling of the external table. The destruction of bone at the exit is likely to be much more considerable. The fissures which are produced may be quite as extensive when beginning at the point of entrance as at the point of exit. The minute fissures which may radiate for a little distance from either wound, of scarcely more than capillary size, are not reckoned in the tabulation.

0.44 cal.

Range, from contact to 1″:

Entrance, 8 observations, 5 fissured.
Exit, 7 " 3 " 3 comminuted.

Range, from 3″ to 6″:

Entrance, 5 observations, 1 fissured, 2 comminuted.
Exit, 5 " 1 " 1 "

Range, from 1 foot to 6 feet:

Entrance, 9 observations, 5 fissured.
Exit, 7 " 5 " 1 comminuted.

Range, 10 feet:

Entrance, 2 observations, 2 fissured.
Exit, 2 " 1 "

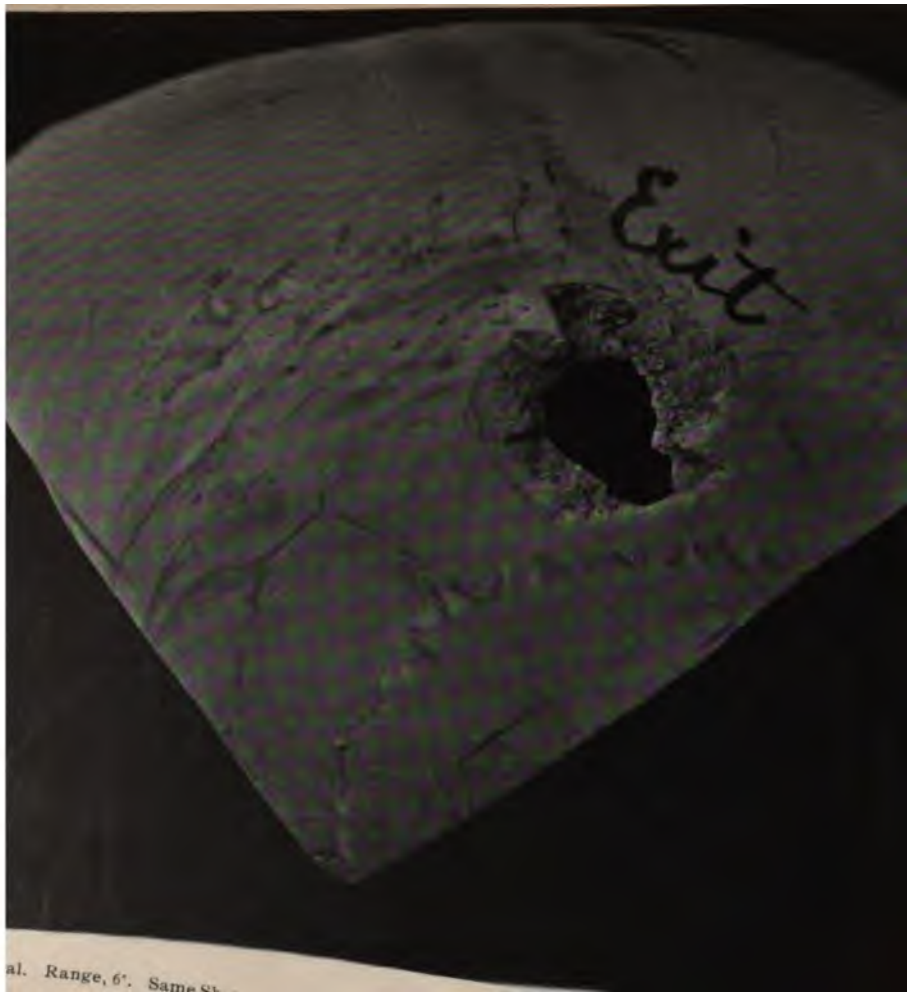

al. Range, 6'. Same

Range, from 15 feet to 30 feet:

Entrance, 8 observations, 7 fissured,
Exit, 6 observations, 2 fissured, 2 fiss'd and com'd.

Range, 40 feet:

Entrance, 1 observation, no fissure or comminution.
Exit, same observation, fissured.

Range, from 50 feet to 100 feet:

Entrance, 3 observations, 2 fissured, 3 comminuted.
Exit, 3 " 1 " 2 "

0.38 cal.

Range, from contact to 1″:

Entrance, 17 observations, 4 fissured, 4 comminuted.
Exit, 14 " 4 "

Range, from 3″ to 6″:

Entrance, 14 observations, 6 fissured, 1 comminuted.
Exit, 10 obs., 2 com'd, 1 fiss'd and com'd.

Range, from 1 foot to 6 feet:

Entrance, 19 observations, 12 fissured.
Exit, 12 " 4 " 3 comminuted.

Range, 10 feet:

Entrance, 4 observations, 3 fissured.
Exit, 10 " 1 "

from 15 feet to 30 feet:

5 observations, 4 fissured, 1 comminut
vations, 1 fissured, 1 fiss'd and com'

FIG. 40.—0.22 Cal. Ranges of 6 ft., 10 ft., 15 ft., and 20 ft. Osseous Wounds of Entrance through External Table.

Range, 40 feet:

Entrance, 1 observation, 1 fissured.
Exit, same observation, fissured.

Range, from 50 feet to 100 feet:

Entrance, 4 obs., 1 fiss'd, 1 fiss'd and com'd.
Exit, 2 " (at 50 ft. and 100 ft.), both com'd.

0.32 cal.

Range, from contact to 1″:

Entrance, 22 observations, 5 fissured, 4 comminuted.
Exit, 5 " 1 " 1 "

Range, from 3″ to 6″:

Entrance, 18 observations, 4 fissured, 3 comminuted.
Exit, 9 " 4 " 1 "

Range, from 1 foot to 6 feet:

Entrance, 43 observations, 10 fissured, 8 com'd.
Exit, 18 " 3 " 7 "

Range, 10 feet:

Entrance, 5 observations, 0 fissured, 2 comminuted.
Exit, 3 " 2 " 0 "

Range, from 15 feet to 20 feet:

Entrance, 8 observations, 4 fissured, 1 comminuted.
Exit, 3 " 2 " 0 "

Range, from 25 feet to 30 feet:

Entrance, 5 observations, 1 fissured, 2 comminuted.
Exit, 2 " 2 "

0.22 cal.

Range, from contact to 1″:

Entrance, 14 observations, 3 comminuted.

FIG. 41.—0.22 Cal. Same Shots as in Fig. 40. Osseous Wounds of Entrance through Inner Table.

Range, from 5′ to 6′:

Entrance, 25 observations, no fissure, no com'n.

Range, from 1 foot to 6 feet:

Entrance, 42 observations, no comminuted.

Range, from 9 feet to 10 feet.

Entrance, 8 observations, 3 comminuted.

Range, from 15 feet to 20 feet.

Entrance, 12 observations, no fissure, no com'n.

In wounds of entrance made by balls of 0.22 cal. it will be noted that there is no fissuring of the bone, and that comminution is absolutely or relatively small. In case of other calibres of ball, fissuring is only exceptionally extensive at either entrance or exit, and unless at contact is governed rather by the physical properties of the crania than by range.

The amount of positive information to be derived from the observation of cranial lesions is limited, but may be important, both intrinsically and as confirmatory of that afforded by the changes wrought in the superficial structures. The further inferences which they may warrant, though not authoritative in elucidating the history of doubtful cases, may so materially strengthen probabilities already established by external examination as to give to them the semblance of certainty.

Intracranial Lesions.

In the investigation of the conditions under which pistol-shot wounds involving the cranial cavity have been produced, cadaveric observation is of only confirmatory

value. It is impossible to determine how far post-mortem changes in the brain structure or in its membranes may modify the characters of injuries experimentally produced, and this uncertainty is sufficient to vitiate any conclusions they might otherwise suggest. The cadaveric changes in the brain are undoubtedly rapidly destructive and attended by marked alteration in its physical properties. Its power of resistance is lessened by a process of softening and disintegration, and at the same time the elasticity of its fibrous covering is probably lost, as it is known to be in other dead tissues of similar character. The first proposition may be assumed from common observation, and the second is illustrated by the course of balls of 0.22 cal., which in the living subject so often penetrate the cranium and traverse a considerable distance beween it and the uninjured dura mater, and in the cadaver, having penetrated the bone, rarely fail to enter the brain. The course of the ball through the living structures, therefore, cannot be inferred with even reasonable certainty from post-mortem experimentation under analogous conditions. Fortunately it is practicable to determine the characteristics of intracranial pistol-shot lesions from their necropsic inspection when inflicted during life, since the possibility of accidental disturbance or alteration which attaches to the peculiarities of the external wound is averted in consequence of their inaccessible situation. The number of recorded instances in which attention has been directed to this class of intracranial lesions is not large, and these have been in great part scattered through the history

the simple fact of death from pistol-shot wound of the head.

The present collection of cases of intracranial injury includes forty of pistol-shot origin, which is perhaps an adequate number for the purpose of medico-legal, if not of clinical conclusions.

The three points which it may be of medico-legal importance to determine in case of pistol-shot wounds are the calibre, range, and direction of the ball.

The calibre of a ball inaccessibly located in the cranial cavity during life, or lost upon exit whether before or after death, must in general be inferred or demonstrated, if at all, from conditions of the external and osseous wounds which have been already indicated. The laceration of the brain substance produced by the passage of the ball presents no differences in character or extent which serve to measure its size with any useful degree of precision. In general, the larger the ball the wider the area of laceration which attends its course, but as it may be driven forward either with or without change in its axis, its track may approximate in width either its transverse or its longitudinal diameter and the value of this distinction be lost. In a minority of cases in which the ball is exceptionally large or small, the greater or lesser extent of laceration may be sufficient in itself to determine positively the question of calibre. The cerebral track of a ball of 0.22 cal. may be, and usually is, too minute to have been conceivably made by one of any larger size; the corresponding track of a ball of 0.44 cal. may be too wide to have been possibly made by one of 0.22 cal., and, range and attendant conditions of the cranial and external wounds taken into consideration, too wide to have been

probably made by one of intermediate size; but with balls of 0.32 or 0.38 cal., in regard to which, by reason of more general and almost equally frequent usage the distinction becomes most important, it is impossible to make.

The absolute extent of brain laceration greatly varies. The wound made by a ball of 0.22 cal. may be of such tenuity that it is difficult to trace beyond the beginning of its course, and in necropsic examinations it may become necessary to abandon the effort and to locate the position of the ball except by minute dissection of the entire organ. If the ball has been one of larger calibre, the area of laceration is from $\frac{3}{8}''$ to $1''$ in diameter, the brain tissue is disintegrated and mingled with minute coagula, or the cavity which has been formed is more rarely filled with a single coagulum through its whole extent. Its width can be most accurately appreciated by incising the brain at right angles to the plane of its general direction. If incision be made through its long axis, a gaping wound is displayed of deceptive size, which becomes larger with every disturbance of the parts. Along its margin the punctate extravasations and local discoloration of the limited form of contusion may be often noted. The concomitant lesions, the general œdema and hyperæmia of general contusion which is characteristic, and the several forms of hemorrhage which are accidental have no significance in this relation, and no inferences can be derived from the depth to which the ball may penetrate.

The range or the distance traversed by the ball from the point of discharge from the weapon to the point of impact cannot be estimated even approximately from an examination of the cranial contents. One or two exceptions may be made to this general statement. At contact, or within

a range which approximates it, the dura may be torn or destroyed, and the contiguous brain substance irregularly lacerated to an extent which is not observed at greater distances. It has been stated in a previous section that in wounds inflicted upon the cadaver, at ranges of six inches or less, grains of powder may be detected upon the contiguous surfaces of the cranium and dura or in the course of the cerebral laceration; but it has been also noted that in wounds inflicted during life hemorrhage is sufficient to make the appreciation of this indication improbable. Aside from these exceptional instances, in which external appearances are corroborated by some circumstance of internal injury, there are no conditions of the intracranial wound which help to establish even a probability in estimating length of range. At all distances, from contact to limit of observation, the ball may traverse the whole extent of the brain in any of its diameters. The thickness or density of the skull, the point of impact, or the angle of incidence are much more influential than range in determining not only the depth of penetration but also the amount and character of laceration.

The direction in which the ball has been projected is readily determined in those cases in which after penetrating the cranium it has overcome the elasticity of the dura and entered the brain. The resistance offered by the bone does not deflect it from its course, and the passing of a probe through the superficial and cranial wounds into the beginning of the cerebral track establishes a line which in its continuation is the one which the ball has traversed. If the bone has not been penetrated, or the dura has remained uninjured, it is impossible to ascertain with either certainty or precision the course the ball has taken.

At ranges short enough to afford marks of smoke, flame, or powder upon the surface, their limitation in some instances to a single aspect of the wound may indicate in a general way, as may subcutaneous fragments of lead carried beyond the osseous entrance, the side from which the ball has been discharged. At longer ranges no inferences as to direction can be made unless a cerebral track exists.

The general study of pistol-shot wounds of the head, by means of extended experimentation upon the cadaver, has afforded a definite amount of positive information. It has been equally fruitful of negative results of no less positive value. The certainty that a questionable medico-legal fact cannot be determined by the presence or absence of given post-mortem conditions may be quite as important as the demonstrably necessary dependence of the same conditions upon some other circumstance of injury. It may be of even greater importance to recognize fully the impossibility of solving a question of suicide or homicide than to be able positively to infer the calibre of the ball or its approximate range. The uncertainty which, in the absence of previous investigation, has existed as to just how far the circumstances under which a wound has been inflicted can be legitimately inferred from post-mortem phenomena, has led to the expression of dogmatic opinions which have been altogether unwarranted. Conclusions, largely theoretical, and more or less based upon undue generalizations from scanty observation, and exploited as demonstrated facts, are not rare in the records of criminal procedure. The preceding observations will be of

with that absolute certainty necessary to criminal investigation, but also as they serve to fix the limit at which knowledge ends and conjecture begins. The practical combination of positive and negative indications for the interpretation of particular cases, the reconciliation of apparent discrepancies in certain instances, the utilization of the material collected, properly concerns the formal writer upon medical jurisprudence. It is the present purpose to aggregate, compare, and generalize the facts noted, rather than to direct their application.

The total number of observations made upon the cadaver in this study of pistol-shot wounds of the head is slightly in excess of one thousand, exclusive of those made upon the body and extremities. Many of these individually included an examination of all the extracranial, cranial, and intracranial lesions; others were limited to such larger or smaller proportion of their number as circumstances might permit; and some did not extend beyond the observation of an isolated fact. A single head could sometimes be utilized for a number of shots if the ball was of small calibre or if the range was long, or it might be serviceable for not more than a single one if the calibre was large and the destructive effects were great.

The illustrations which accompany the text are of life size and are from photographs taken immediately after the wounds were inflicted. They are, therefore, exact reproductions of what was observed in these specified instances. Those of them which concern the external parts are confined to short ranges, since at greater distances there are no other superficial lesions than the cutaneous opening, which is not characteristic. The osseous wounds which are represented were selected nearly at random from those

in calvaria collected from this series of observations and now in the Wood Museum of Bellevue Hospital, and are intended to show the characters of such injuries in both the external and internal tables, at entrance and exit, independent of range or calibre.

Chapter VIII.

SURGICAL RELATIONS.

SYMPTOMATOLOGY.

THE surgical history of pistol-shot wounds of the head is largely included in that of the general class of intracranial injuries to which they belong. It involves the same lesions: fractures of the cranial base and vault, general contusions and lacerations of the brain, and epidural, meningeal, and cortical hemorrhages, which are peculiar only in the fact that they are always direct, and never the result of indirect violence. It presents essentially the same symptoms, general and localizing, which are produced by other traumatisms affecting the same parts. Its questions of diagnosis, prognosis, and treatment are to be solved in accordance with the significance of symptoms upon lines already established, and differ only as they are modified by the lodgement of a foreign body in a perhaps unknown and inaccessible part of the brain or cranial cavity. It is sufficient therefore in the special consideration of this form of intracranial traumatism to regard simply such points of difference as may obtain in consequence of the introduction of this additional element in the case.

The number of such wounds included in the present

series of intracranial injuries is limited, and in but few instances has life been sufficiently prolonged to necessitate raising a question of either localization or treatment. From 1879 to 1895 inclusive there have been recorded in more or less detail in the British, Colonial, and American journals and transactions of societies, one hundred and forty-five cases in which patients have survived the primary shock of pistol-shot injury involving the cranial cavity, of which one hundred and ten have been accessible for comparison. The aggregate number of these published cases, with the addition of those in the appended series in which death was not immediate or was not too early to permit the notation of symptoms, or the consideration of prognosis or treatment, is one hundred and thirty-six, and it is believed affords a sufficient basis for generalization and to warrant the conclusions formulated in the present study of the subject. The tabulated collections of pistol-shot or other gunshot intracranial wounds which have been previously made in skeleton form for statistical purposes are so wanting in essential elements of comparison as to be practically valueless for the solution of problems in diagnosis or treatment.

Pistol-shot wounds of the head, unlike those produced by arms of longer range or greater power, rarely occasion serious injuries without having penetrated the cranium. Fragments of shell, spent rifle balls, and various missiles, by which gunshot wounds are otherwise inflicted, may fracture the cranium or lacerate the brain without so much even as breaking the skin; the lesions are then not different from those occasioned by other means of violence, and their symptoms and termination are in no wise peculiar. A pistol ball, on the contrary, never causes a simple frac-

ture, and rarely a compound fracture which is more than nominal, unless the bone is also penetrated. If the ball is of 0.22 cal. it may even penetrate to the dura without cerebral lesion; if it is of a larger calibre, there is no reason to believe that its simple impact upon the bone has ever been attended by intracranial complications.

In only exceptional instances a compound fracture without penetration has entailed consequences of a serious character. In a case reported by Mr. Butcher, remarkable in various particulars, a compound depressed fracture of the frontal bone and a subsequent osteogenic process, occasioned by the discharge of a pistol loaded only with powder and hard wadding, produced epilepsy and absolute imbecility through a circulatory disturbance. The same effects might legitimately follow in any case in which a bullet had penetrated only the outer table and depressed the inner one, if remedial treatment were not employed. It is always possible also that a non-penetrating compound fracture, even though a simple fissure, in the absence of aseptic precautions whether from neglect or from an inaccessibility of position, should afford a channel for intracranial septic infection. This accident will hardly occur in fractures of the cranial vault, but is not unknown at the base in regions where the bone is thicker and its vascular spaces are larger, or where the peculiarity of its situation prevents discovery or effective approach. There is a recorded instance of such an intracranial infection from pistol-shot wound, in which a suppurative arachnitis resulted from the lodgment of a bullet in the petrous portion. There is a similar case in which two rifle balls were embedded in the basilar process and led to gangrene of the dura mater, epidural abscess, and suppurative meningitis.

It may be fairly stated that in a pistol-shot wound confined to the soft parts and cranial vault this complication can occur only through a neglect of the most ordinary aseptic care.

If the bullet, of whatsoever calibre it may be, penetrates the brain, the lesions it causes are still contusion, laceration, and hemorrhage, and the general symptoms are still those which pertain to such conditions, however they may have been induced.

The characteristic initial symptom of this variety of intracranial injury is in the serious cases likely to be especially prominent. The unconsciousness, which is never absent in those which are immediately fatal, is of a remarkable profundity. It is in part explicable by the general contusion which is a factor in the production of primary unconsciousness in all cerebral lacerations, and is continued and deepened by the often profuse immediate cortical hemorrhage. An additional cause of this condition, and a possible explanation of its depth, may be found in a cerebral shock due to the directness and magnitude of the destruction of the nerve centres. This is apart from material change or the intervention of the sympathetic or spinal ganglia, and is rather akin to the effect of emotional shock as exemplified in the sudden and entire abolition of consciousness from an extremity of grief or horror. This distinction is in a measure recognized by Dana, who, having defined shock as a "sudden depression of the vital functions due to nervous exhaustion following an injury or a sudden violent emotion," divides it accordingly into "corporeal" and "psychic." In this instance the injury is corporeal, but it is inflicted directly upon the cerebral ganglia, and its effect is manifested without the impulse

having been transmitted to the sympathetic system, the irritation of which, as shown by Boise, is the immediate cause of the contracted arterioles, pallid skin, and rapid pulse which characterize the shock of bodily injury. If the profound unconsciousness is to be ascribed solely to the general cerebral contusion, or, as that lesion is interpreted by Von Bergmann, to the suspension of general cortical activity from circulatory disturbance, it presupposes a greater derangement of cortical circulation than results from other forms of violence or is indicated by necropsic examination. In this state of unconsciousness, death may ensue almost if not quite instantaneously, or after an interval of hours or even minutes. Aside from an abundant hemorrhage which issues from the external wound and is of frequent occurrence, and the changes in pulse, temperature, and respiration, this is the entire clinical history of a large majority of cases. If the pulse is primarily diminished in frequency, the change in this direction is so transitory that it is a necessarily inappreciable symptom.

In those cases in which consciousness has not been instantaneously abolished, it is not often possible to ascertain the immediate subjective symptoms. Suicidal subjects are indisposed to speak of the circumstances which attended the infliction of their injury, and in many instances acute mania, alcoholism, or innate stupidity has prevented its appreciation, but it has been occasionally chronicled. In the case of a man who shot himself in the vertex and lacerated the longitudinal sinus without implicating the brain, it was described by him as a sensation like an electric shock followed by paraplegia and a brief period of unconsciousness. A woman who shot herself in

the mastoid process without penetrating the cranial cavity experienced excruciating pain. A youth whose right frontal lobe had been traversed by a bullet found his immediate sensations to be those of pain in the ear and vertigo. Another man, in whose right frontal lobe the bullet was deeply embedded, felt at the instant of pulling the trigger a sense of general numbness and then of deep-seated pain in both ears. In still another case of pistol-shot wound of the frontal region, in which both lobes had suffered extensive laceration, the suicidal person was enabled long afterward not only to analyze his thoughts at the moment the injury was inflicted, but to recall the impression upon his mind of the almost simultaneous shriek of his mother from an adjacent room. He was suffering from melancholia with a feeling of oppression in his head, which was the immediate incentive to self-destruction. The act was deliberate, and, while he was not unmindful of his family, the discomfort he felt in the top of his head was, as he expressed it, "uppermost in his mind." He remembered his mother's cry at the report of the pistol, but had no further definite recollection of what occurred till he "awoke" twenty-three days later in the infirmary to which he had been removed; and yet for the first two weeks he was apparently rational and in full possession of all his intellectual faculties. After a subsequent period of mental disorder with delusions and paroxysms of acute mania he was apparently quite recovered at the end of the fifth month (Sloane).

This case, which was recorded with unusual care by his medical attendant, demonstrates that even with extensive destruction of the psychical centres neither the perceptional nor the ideational powers are necessarily

suspended for the minutest conceivable measure of time. The cry was heard and its source recognized, which involved a reasoning process, in the time required for sound to traverse twice the distance between two adjacent rooms; for, as instinct is even quicker than thought, no appreciable interval could have intervened between the mother's perception of the report of the pistol and her instinctive response.

This history parenthetically illustrates the unsuspected enfeeblement of will and incapacity of judgment which may really exist in a case of apparently simple melancholia, and in this instance permitted the man to believe that an absurdly trivial ill so far transcended all the obligations and interests of life as to make it not worth the living, and left him powerless to restrain his suicidal impulse. His later mental condition was in one respect anomalous. In the period immediately succeeding the injury it was believed to be absolutely normal. After a consecutive longer period of acute mania and apparently settled aberration, his mind was permanently restored, except that his memory was wanting so far as it concerned the previous rational interval. It is usually the remembrance of events directly connected with the infliction of a grave cerebral injury that is temporarily or permanently lost, and subsequent events, if forgotten for a time, are recalled before the reparative stage is ended. In the case of this patient, memory was perfect for everything that had been felt or done until an instant after the wound was inflicted, and partially retained for occurrences during the maniacal episode, but a hiatus was complete as to the rational period which intervened between the condition of melancholia and the access of mania. How far his aber-

rations depended upon traumatism and how far upon the progress of his prior mental infirmity, it is of course impossible to decide.

These phenomena scarcely belong to the consideration of the primary symptoms of pistol-shot wounds of the brain, but are not altogether impertinent, in view of the relation which so frequently subsists between such wounds and mental disorder.

If the first effects of injury be survived, there is no essential variation in the course of symptoms as it has been noted in the general class of brain lacerations. Consciousness is perhaps less frequently retained, vomiting of rather more frequent occurrence, and pain in the head more severe. Death may result from the continuance of intracranial hemorrhage, or from the direct inhibitory action of laceration and attendant general contusion upon the vital cerebral functions. In a much smaller proportion of cases these dangers are safely passed only to give place to others, scarcely less formidable, which attend retrograde nutritive changes in the cerebral tissue. Softening and abscess with paralysis, mental deterioration, and epilepsy may follow in the course of time, with their usual symptoms in no degree modified by the nature of the original traumatism. The localizing symptoms which may be at any time manifested, in consequence either of limited lesions in the track of injury or of the presence of the ball at the point at which it is lodged, equally conform to rule as established in the general symptomatology of intracranial injuries.

Diagnosis.

The problem of diagnosis distinctively concerns but a single point, the location of the bullet when it still remains within the cranial cavity. The nature of the traumatism, the circumstances under which the wound has been inflicted, the point at which the cranium has been penetrated, and the direction which the missile has taken, have all been elucidated so far as it has been possible, in the study which has been made of the external wound in its medico-legal relations, and are independent of intracranial conditions. The character and extent of the lesions produced by the bullet in its passage through the brain and appendages can be determined by no different means than have heretofore served for the estimation of similar lesions of different origin. As they have been manifested by the same symptoms in either case, they must be recognized, if at all, by giving these symptoms an identical interpretation. The location of a bullet which has failed of exit alone demands special diagnostic consideration, and involves the employment of special methods of investigation. It is sometimes easily accomplished, oftener with difficulty, and oftener still it is impossible. Any effort directed to this end is necessarily deferred until the immediate safety of the patient is assured. If, after the partial restoration of consciousness, localizing symptoms become apparent which can be disassociated from lesions caused by the bullet while still in motion, they are practically pathognomonic. The occurrence of limited paralysis upon the side of the body corresponding to a wound of entrance, for example, in the temporal region, with the corroboration which might be afforded by the

axis of the cerebral wound, would point with great certainty to the lodgement of the bullet in a designated part of the motor area. In like manner the existence of motor or sensory aphasia, or at a later period the occurrence of certain disorders of vision, might equally indicate its location in a definite part of a speech or visual area. The instances in which dependence may be placed upon cerebral localization are after all comparatively infrequent. The extent of cortical area which as yet must be regarded as latent or of indeterminate function is so great, and the further probability that the bullet will rest in some subcortical region is so strong, that such aid is hardly to be expected. In another small proportion of cases a clew to the position of the bullet may be had in a discoverable injury to the opposite wall of the cranium. This may be more or less evident; the scalp may be contused above it or the bone obviously elevated, or there may be only a tender spot, beneath which after incision some fine fissures may be detected. The shaving of the head, which is practised as a part of the routine of treatment in all intracranial injuries, permits careful examination, and will probably insure the discovery of any lesion which includes the external table.

The main reliance of the surgeon in this investigation must be upon the use of the probe, by which it is sought to trace the bullet from its osseous entrance to its point of lodgement. This method of exploration of gunshot wounds as they affect important visceral cavities has been much and properly criticised, but the procedure is in itself proper, and the limitations to which it is subject concern the consideration of treatment rather than of diagnosis. The instrument is variously adapted to its purpose; the

ordinary one of silver which is employed for general surgical exploration is supplemented by those of Fluhrer, Nélaton, and Girdner. Fluhrer's probe, like the one in more common use, is designed for general exploration, but is differently constructed. Nélaton's and Girdner's are both intended not only to detect the presence of a foreign body in the tissues but to determine its metallic character.

Fluhrer's probe is so fashioned as to obviate some of the disadvantages which are found to attach to the use of the commoner instrument. It is of large size, tapering toward two bulbous extremities; it is twelve inches long, and in diameters one-eighth of an inch at its middle, and one-fourth and one-eighth of an inch respectively in its larger and smaller terminal bulbs. Its shaft is rigid, and its weight is lightened by the use of tempered aluminium in place of silver. The ends are made large in order to diminish the danger of wounding the tissues and of making false passages; the shaft is made rigid in order that its relation to the bulbous ends shall be fixed; and its weight is made light in order to transmit without loss delicate vibrations to the hand.

The probe of Nélaton, by reason of its capability of receiving and retaining a lead stain, has been long used to determine the fact that a foreign body is a leaden bullet. It is a simple ball of unglazed porcelain at the end of a flexible silver stem; it may be of any size, but is usually of about one-eighth of an inch in diameter. It acts as an ordinary probe in detecting the foreign substance, and specifically determines its nature by acquiring or escaping the peculiar stain of lead as the two substances are firmly pressed or rubbed together. The porcelain will be stained always if actual contact can be obtained; but the practical

difficulty and possible source of error lies in the fact that this contact cannot be positively assured. It is found in practice that the surface of the bullet may be so protected by blood and shreds of tissue, and the surface of the porcelain so smeared by the fluids of the part, that while the impact upon a hard body may be evident the characteristic stain may be wanting. The positive evidence which it affords is unquestionable, but its failure to demonstrate the presence of lead does not equally prove that the hard body felt is not a bullet.

Girdner's telephonic probe, which is of comparatively recent introduction, like that of Nélaton, acts as an ordinary probe, and at the same time, when the foreign body embedded in the tissues is a bullet, demonstrates its metallic nature by the grating sound produced from the interruptions of an electric current established through it, the circuit being formed by the probe in the hand of the operator, a battery, and a bulb in the mouth of the patient. Every precaution of course must be taken to insure the continuity of the current except as it is broken upon the surface of the concealed object when the end of the instrument passes over its inequalities. The receiver is held to the ear with one hand, while the probe is guided with the other. This instrument is now sufficiently well known to require no more detailed description. If contact be made with the alien substance, it cannot fail positively to determine whether or not it be the bullet, and in this has manifest advantage over the device of Nélaton. There can be no doubt of its value in gunshot wounds of other regions of the body, as in the extremities or in the neighorhood of the spinal column, when to decide this question is to decide the question of operation. It has less practical im-

portance in case of brain wounds, in which a fragment of bone carried into the substance of the organ may be as much a menace to life as is the bullet itself. In the numerous instances in which the position of a foreign body cannot be determined it can be of no avail, because contact is an essential condition. Its usefulness is limited, therefore, not only since it does not necessarily make the surgeon's position clearer as regards the propriety of operation, but as it fails of even the possibility of very general application. In wounds of the basilar and mastoid processes, and of the petrous portion, or when the bullet has lodged in the basic fossæ without having penetrated the dura, or in the orbit, it may be of the greatest service. If it were possible for the electric current to make manifest the vicinage of a bullet to which it could not quite be made to reach, it might more nearly solve one of the still difficult problems in surgery. It has been sought to determine in this way the location of bullets in the brain, as well as elsewhere, by means of an instrument known as the induction balance. In the opinion of Dr. Girdner, who has given it much attention, this mechanism is so delicate in construction and so easily deranged that it can be made effective only in the hands of a professional electrician. It would seem, therefore, that it must take its place with other surgical appliances of theoretical value which are too complex for practical general use.

If the cerebral wound be large, and especially if not too deep, the finger, when confined within the limit of laceration, may prove the best instrument of exploration.

The use of the Röntgen rays for determining the position of a bullet within the cranial cavity has thus far been attended with little success. Two cases have been re-

ported by Dr. A. Eulenberg during the past year (1896), in which by a new process of Dr. Buka, of Charlottenburg, the location of the missile seems to have been demonstrated. In both instances a wound had been inflicted in the right temporal region by a pistol shot of small calibre. In one of them exposure to the rays was made a few weeks after injury, and in the other not till after the lapse of ten years. In one, symptoms indicated lesion of the right side of the brain, and in the other no such localizing indications existed. The only apparently successful instance of the employment of this process for the detection of a bullet in the brain, which has been reported in America, is one occurring in the service of Dr. Willy Meyer in the German Hospital of New York. The patient, whose early history is recorded in Case CCC. of the appended series, was some time after his discharge from Bellevue Hospital, and at a date later than that of Eulenberg's cases, subjected by Dr. Meyer to the Röntgen test, with the discovery of three minute objects in the frontal lobes, and in line with each other, two of which were believed by him to be fragments of the bullet. In neither of the cases reported by Eulenberg or Meyer was the result verified by subsequent operation or necropsic examination. The subject of the case last mentioned again became a patient in Bellevue Hospital, but was for various reasons deemed unfit for operative interference.

It is not improbable that the development of this form of photography may in the future add greatly to the certainty with which intracranial foreign bodies can be discovered and their position accurately determined; it seems less certain that by thus increasing the possibility of positive diagnosis it will equally add to the resources and suc-

cess of treatment. Increased perfection of method and apparatus will tend to remove it still farther from the uses of private practice, except in cases in which recovery has been had from the immediate effects of injury. In hospitals, where it might otherwise be available, the condition of the patient will be likely to preclude its employment at the outset, when operation, if not imperative, will at least afford the best prospect of a successful issue. If the missile or fragment of bone is superficially situated, it should be discovered and removed at once without the necessity of resort to other than ordinary means; if more deeply embedded, and undiscovered at the time when exposure to the light rays has become practicable, success in the disclosure of the bullet will still leave special operative difficulties to be encountered. The original cerebral wound will probably have been closed, and after the exact location of the bullet has been fixed at the intersection of different planes of view, it may be far from easy to utilize this conception in the mind of the operator for making a new and lengthened incision with the precision which is essential for the justification of so serious a procedure. It is idle, however, to speculate upon the practical application of as yet unattained results in scientific progress; new conditions may conceivably involve the use of more facile and widely applicable instrumentalities, but at the present time no demonstrated advantage has accrued in this department of surgery from the Röntgen process of photography.

A final diagnostic method consists in thrusting a sharp needle into the cerebral tissue, not quite at random, but in directions which there may be reason to suppose the bullet has taken. If perfect asepsis has been secured, this

may ordinarily be done with safety and the bullet possibly discovered. It is a legitimate procedure, recognized in general cerebral surgery, but should be resorted to advisedly and with great discretion. If the bullet cannot be reached through the cerebral wound, and there are at the same time localizing general symptoms or other indications which point to its approximate position, it may be properly sought in this manner, but reckless punctures of the brain which are uninspired by some intelligently directed purpose are scarcely justified by the slender chance of their accidental success.

These several methods of search, guided by the observation of existing localizing symptoms or of indications of injury to the opposite cranial wall, are the only means available for the discovery of the bullet. Their successful use requires not only manual skill, but quickness of perception and sagacity of interpretation in the study of the often obscure attendant conditions.

It has been assumed that the bullet in its passage through the brain is likely to be diverted from its direct course by trivial obstacles, as is known to be the case in the extremities or in certain regions of the trunk. This contingency is in fact less to be expected within the cranial cavity than elsewhere. The density of the brain substance is very much the same from one surface to another, and it is found in both ante-mortem and cadaveric wounds that the reflections of the dura mater are usually penetrated without the direction of the bullet having been changed. There are not wanting instances in which it has been deflected by the falx cerebri, or in which, having entered a dural sinus, it has traversed it to the end, but these are exceptional. It is nevertheless the fact that in a consider-

able proportion of cases the bullet which fails of exit is turned aside from its direct course. The change impressed upon its direction is due, not to deep intracranial obstruction, but to the resistance offered by the cranial wall and dura mater at its entrance, or by the same structures upon which it may impinge at a point upon the opposite side of the head. A bullet, especially if of small size, with or without penetration of the dura mater, is often at once deflected at a right angle, or if of larger size, after traversing the brain and having insufficient force to penetrate the opposite dural wall, falls back into the track and is diverted perhaps to a considerable distance in some new direction. It may be that it drops directly downward through the cortex or immediately subjacent tissue toward the base, or it may quite as probably take some undiscoverable course which leads to inaccessible cerebral depths. In any attempt at exploration of a cerebral wound to discover the location of the bullet, it should be borne in mind that it is not in the central part of the brain that it is most likely to go astray. If the wound can be traced directly inward for an inch or more, while it is still possible than an elusive pistol ball may have been deflected by a dural reflection, or have stopped short from exhausted force at any point just out of reach, it is more probable that it has gone straight onward at least as far as the opposite dural wall, and that further search must involve a new departure. The larger the ball the more likely is this generalization to prove true in an individual case.

In a wound involving the anterior temporal region especial heed should be given in doubtful cases to the condition of the eye and to the orbit. Sight may have been destroyed by an injury of the optic nerve at the optic fora-

men, and, in the absence of ocular hemorrhage or other apparent ocular or orbital changes, escape discovery unless the parts are subjected to systematic examination. The lack of attention to these local indications, in one case at least, has permitted the resort to serious operation in the vain search of the brain for a bullet, the presence of which in the orbit was evident, but ignored because it failed to respond to the electric test. Considerable hemorrhage in the post-orbital region, causing discoloration of the lids and protrusion of the eye, is not to be lightly disregarded; and the suspicion which they engender may be strengthened by the direction which the bullet may be found to have taken from the point at which it entered the brain.

It is also possible that the bullet should escape from the cranial cavity in some region of the base which is beyond the possibility of direct examination. This may be detected in rare instances, as it was in Case CCXCIX., by passing the probe through the whole length of the cerebral wound and through the osseous exit. Such a lodgement of the ball can ordinarily only be suspected, and confirmation can be had only in the recovery of the patient. It is sufficient to recognize the possibility of this issue to give perhaps a new significance to apparently trivial signs and symptoms, and sometimes to make easy the interpretation of an otherwise inexplicable case. Pain or swelling in some cervical region, or functional disability of the muscles there or in the pharynx, with some dysphagia or dyspnœa, without apparent cause, together with unexpectedly inconsiderable or improving cerebral symptoms following a wound, perhaps in the mastoid or inferior temporal region, through which the ball has passed in an an-

swerable direction, make up a picture distinct enough if it be but seen in proper focus.

The antithetical case in which the bullet passes through the mouth or neck or even through the eye to penetrate the cranial base is occasionally difficult of diagnosis. Ordinarily in such a wound, its evident nature, or the immediate occurrence of characteristic symptoms, so plainly mark the intracranial complication that the diagnostic problem is solved before it has really challenged thought. In the exceptional case it may be impossible to follow the track of the ball or even to surmise its course, while the general condition of the patient may cause vague suspicion of some hidden lesion; or after an interval devoid of symptoms some decided change occurs, a notable and continued rise in temperature it may be, for which the closest scrutiny of accessible regions affords no adequate explanation.

There are no formal rules to follow in the examination of the doubtful cases in which the bullet may have escaped from the cranial cavity into inaccessible adjacent parts, or in which from primary wounds of those parts the bullet may have terminated its course within the cranial walls. It is necessary for the surgeon to be at once alert and suspicious in the presence of symptoms of uncertain significance, to bear well in mind all the possibilities connected with the whereabouts of vagrant bullets, and to be wary in the formation of opinions while premises are not yet positively settled.

Treatment.

The consideration of treatment may properly precede that of prognosis, and may be essentially limited to that division of the subject which concerns the question of interference or non-interference with the bullet when retained within the cranial cavity. The management of the lesions which the bullet has produced involves no new principles, and is not different from that which has been prescribed for the same cerebral conditions when they have resulted from ordinary forms of violence; it is therefore unnecessary in the present connection to reconsider its details.

The inception of any treatment comes in question in only a minority of cases; passing those in which death has been nearly or quite instantaneous, and those in which it is so obviously imminent that there is room only for the simple offices of humanity, but few remain in which the surgeon is called upon to treat primary shock and hemorrhage. The recumbent position, the application of external heat, the hypodermic exhibition of cardiac stimulants, the use of hot saline enemata, or the resort to transfusion, and at the same time, if it be possible, the repression of hemorrhage, are here as elsewhere the means at his disposal. Until the establishment of reaction nothing more remains to be done. Thus far the procedure is the same as it would be for other surgical injuries; the general treatment of shock is scarcely modified by the nature or location of a wound; and the necessity of postponing surgical interference, except for the control of hemorrhage, until after the restoration of nervous force, must be regarded as a fundamental law in surgery. Usually if hemorrhage is

sufficient to be matter of serious concern it will be uncontrollable, but it may be derived in some or even greater part from the vessels of the scalp, which may be then easily secured by ligature. There are perhaps cases in which intracranial hemorrhage, though moderate, is persistent, and in which temporary plugging of the intracranial wound with aseptic gauze is justifiable, as it is in operative wounds inflicted upon the brain. If resort is to be made to this means of hæmostasis, great care should be exercised to prevent the further escape of blood from the cerebral wound into the arachnoid and epidural spaces.

At the same time that restorative measures are being employed, and as opportunity is afforded, external lesions should be scrutinized, both for medico-legal reasons and for guidance in subsequent surgical procedure. The smoke stain, the unburned grains of powder upon the surface, and slight traces of flame are so easily lost that when present they should be noted at the earliest possible moment. The original characteristics of the external wound are liable to alteration and therefore should also receive immediate attention.

The further treatment of these cases has been the subject of varied opinion, and is still based upon widely different views of surgical propriety. It has been held: First, that the wound should be left absolutely undisturbed, and intrusted to the simplest form of external aseptic dressing, since the dangers of interference outweigh any which may result from the direct cerebral injury or from the retention of a foreign body. This may be regarded as an ultra-conservative and traditional judgment unmodified by changed conditions of surgical practice. Second, that while operative interference may be-

come a necessity, its only justification will exist in the establishment of drainage, and that the removal of the bullet is of minor or no importance, since it is in itself harmless, having accomplished all the mischief of which it is capable in the infliction of the wound. This is a semi-recognition of the fact that aseptic methods are demanded for the successful management not only of wounds of the surface but of the cavities and viscera of the body. Third, that the condition of the superficial, cranial, dural, and cerebral wounds should be subjected to thorough examination, fragments of bone removed, drainage insured when necessary, and the bullet, if possible, extracted. This course of procedure is in accordance with general surgical practice at the present time, and is founded upon a belief that asepsis demands absolute cleanliness, and that its laws are of universal application and are to be enforced in their integrity.

These several views of the proper plan of treatment of cerebral wounds of this character have been clearly asserted, and the results of their practical application fully illustrated in the reports of cases published during the past sixteen years. Such a series of clinical observations affords the only ground for opinion, aside from theoretical considerations based upon the general principles of surgery. The one hundred and thirty-six cases collected represent the almost entire published experience of English, Colonial, and American practitioners since the adoption of thorough aseptic methods in surgery, and include twenty-six taken from the personal records which so largely form the basis for the present study of general intracranial lesions.

The principles of surgical practice are so well estab-

lished that it would seem scarcely necessary to insist upon the propriety of exploration of the external and cranial wounds, and the removal thence of fragments of bone and other foreign bodies, if some of the most recently reported cases had not shown that this simple procedure is still often neglected. There is no reason *a priori* why these particular wounds should be made exceptions to accepted general rules of treatment, and the only conceivable justification, if any existed, would have to be found in the results obtained in actual practice. An examination of this entire series of cases faills to disclose any instance in which a conformity to rule in this respect has inured to the prejudice of the patient, but evidently its neglect has often entailed a fatal result.

Death occurred in forty-two out of seventy cases in which no operation was performed. In ten of these reaction was never sufficiently established to justify interference; and in five the history is not sufficiently detailed to determine whether operation was done, and, if not, whether its omission was responsible for the result. In at least seven of the remaining twenty-seven cases, death can be directly traced to the want of exploration and of thorough aseptic treatment of the osseous and superficial cerebral wound.

The necropsic conditions were:

CASE I.—A mass of bone piercing the dura and brain, with a superficial cavity containing the bullet and pus, and a nearby abscess in the frontal lobe.

CASE II.—Many osseous fragments embedded in the brain and a wound of the middle meningeal artery, which was the direct cause of death twelve hours later.

CASE III.—Operation on the forty-seventh day and the

removal of small osseous fragments from the frontal region with discharge of a purulent fluid. The bullet on necropsic examination was found to be encysted in the cerebellum.

CASE IV.—Superficial cavity containing the bullet, fragments of bone, and a sero-purulent fluid.

CASE V.—Large fragments, composed of both osseous tables, driven into the brain, and contiguous abscess. No cerebral change at the site of the distant bullet.

CASE VI.—Large fragments of bone removed by operation in the eighth month. Necropsy six days later; subcutaneous suppuration and localized meningitis; large abscess in subjacent temporal lobe.

CASE VII.—A depressed dural cicatrix, containing osseous fragments and a piece of lead. The remainder of the bullet was subcutaneous.

In another case, classed among the fatalities following early operation, an osseous fragment was removed on the eighth day with a considerable discharge of pus. Death occurred from sepsis some time afterward.

In two instances there was apparent recovery before the development of the fatal symptoms.

These cases are perhaps not to be regarded as statistically denoting the fatality which results from the neglect of this simplest form of operative interference; the proportion of reported cases to the whole number of pistol-shot wounds of the cranial contents is too small. They are quite sufficient to establish the fact that osseous fragments resting upon the cerebral surface or penetrating the cerebral cortex may be more dangerous than the bullet itself; that there is no safety in the absence of early symp-

toms of irritation; and that instances are not infrequent in which these fragments constitute not only the most imminent but the sole source of danger. They make it no less clear that the bullet may rest scarcely below the cranial wall, removable by the simplest possible operative means, but left undisturbed as surely leading on to death as though buried deep in the cerebral substance. They can leave no question that the continuance of removable foreign bodies in accessible tissues, the neglect to provide a channel for natural drainage, and a wilful ignorance of the conditions of a wound, in defiance of the canons of surgical law, are no more to be tolerated here than in other regions where the proper course to pursue has been long unquestioned.

The incision of the dura mater is a more serious procedure than exposing and enlarging the osseous wound. There are instances of brain implication in which the dura is intact or has suffered no more than trivial injury; in these some natural hesitation in resorting to deeper exploration may be felt. If the dura mater is bulging with or without pulsation, or is bruised, or even discolored, the necessity of exposing the cerebral surface is not to be doubted. In one of the more recently reported cases, dural incision gave exit to a small amount of blood and cerebral *débris*, and was followed by immediate relief of profound coma and the recovery of the patient, the bullet having been previously removed from the external wound. The dura mater was here bulging, though apparently uninjured. In another case, also of recent date, in which the bullet was impacted in the cranial wound, the uninjured dura, which maintained its normal relation to the subjacent cerebral surface, was not incised and death ensued. On

necropsic examination a small superficial clot was found in the midst of a mass of softened and disintegrated cerebral tissue. In a third case, the inner table of bone, though not apparently broken through, was fractured and driven back into the cranial cavity. After removal of the osseous fragments, the dura mater, which was bulging and had been slightly wounded by a spiculum of bone, was, evidently against the better judgment of the surgeon, neither incised nor sutured. A week later death resulted from an extensive purulent meningitis. The external wound had been drained and aseptically treated.

These instances constitute a sufficient argument from experience to demonstrate the danger which may lurk behind a dura mater which the bullet has left untouched, and which can be estimated and possibly surmounted only by inspection of the parts beneath. If the appearance of the membrane is abnormal, decision should be no less easy than action prompt. It is the cases in which the dura mater itself affords no clew which occasion doubt and hesitation. It may be assumed that cortical contusion does not often exist without some dural indication; but, as this is possible, the question still remains whether or not it is safer in every case to arrive at certainty. When the bullet is of large or medium calibre, and the amount of cranial injury indicates much force of impact, the probability of cerebral lesion would seem not only to justify but to demand this measure of prevention. If the bullet is not of larger calibre than 0.22, the inner table of bone not comminuted, and the dura not affected, it may be well to forego subdural exploration. In any case in which doubt fairly arises preference should be given to the aggressive course, and with adequate aseptic care no harm will come

from simple exploration, though the event should prove suspicion to have been unfounded.

The second proposition in regard to the proper objects, demands, and limits of operative treatment recognizes the necessity of superficial exploration and removal of foreign bodies, and extends similar methods to deeper parts of the brain and intracranial cavity, but holds their utility to exist only in the establishment of aseptic conditions. It denies the irritative effect of foreign bodies in the brain tissue, and asserts the harmlessness of a bullet after its lodgement has been effected. A modified view admits danger from its retention, but regards this as less than that which attends an attempt at its removal.

As this proposition involves the question of management of the bullet, in regard to which there has been not only great diversity of opinion but of practice, it demands careful scrutiny in the light of experience as it has been disclosed in recent years.

First, it is claimed that the innocence of stranded bullets has been established by the subsequent history of persons who have survived the immediate effects of injury. There have been forty-one recorded cases in the series of one hundred and thirty-six, the greater part of which, in the opinion of their chroniclers, may be placed in this category. Of these, at least twenty-five should be discarded as of questionable character, or as unverified by a sufficient lapse of time. In four of the twenty-five the penetration of the cranial cavity was doubtful, in one of which in fact the failure was demonstrated; in a second the bullet could not be traced through the orbital wall; and in a third, though a wound of the occipital lobe was made certain by the presence of brain matter in the

hair, the absence of any sort of primary symptoms made it more probable that the missile had fallen back and escaped externally through the wound of entrance. The fourth case is that of a man who is said to have carried in his brain for sixty-five years a bullet received at the battle of Waterloo. There is no medical evidence that the cranial cavity was penetrated, no necropsic examination was made, and no symptom is noted, except "a feeling at the back and lower part of his head, such as would be expected to arise from a bullet which had destroyed his eye and traversed the brain but had not effected its escape." To those who have not experienced this "feeling" the corroboration of this story of Waterloo is not entirely sufficient to remove it from the doubtful class.

In six of the remaining twenty-one cases the final observation was made within one month; in ten within six months; and in five within eight to eleven months. In some of them at such time there were no symptoms; and in others there were continued indications, more or less important, of cranial injury.

From an examination of the sixteen cases which remain from the forty-one, though in some instances their duration was brief, it is possible to derive some information as to the alleged innocuousness of the bullet when retained within the cranial cavity.

(1) Purulent discharge from a wound of the left parietal lobe, which continued till the seventeenth day, when the bullet was removed, with some osseous fragments, from a cavity just beneath the cerebral cortex. Subsequent recovery.

(2) Wound of right frontal lobe, which healed. Symptoms of mental decadence continued till death on the thir-

tieth day. Bullet lodged in a cavity in opposite frontal lobe, surrounded by clot and disintegrated brain tissue.

(3) Wound of right parietal lobe. Death on the thirty-sixth day; bullet in necrotic tissue beneath median surface of same lobe.

(4) Bullet of 0.22 cal. lodged in petrous portion; purulent discharge till death from sepsis on forty-first day.

(5) Wound of left frontal lobe; purulent discharge from wound till death at the end of six months. Bullet found post mortem with osseous fragments in a superficial abscess cavity.

(6) Wound of right frontal lobe; purulent discharge till removal of bullet from just within the osseous wound in the seventh month, followed by hernia cerebri and ultimate recovery.

(7) Wound of left frontal lobe; purulent discharge till death at a period not stated. Bullet with osseous fragments found in a superficial abscess cavity.

(8) Bullet of large calibre, lodged in an undescribed part of the brain, caused epileptic convulsions after the lapse of several months; ceased at some undefined later period.

(9) Both frontal lobes traversed by a bullet of 0.22 cal. At a later period patient became irritable and quarrelsome.

(10) Mid-frontal region penetrated by a bullet of 0.22 cal. without cerebral injury. No symptoms eighteen months later.

(11) Wound of left frontal lobe followed by epileptic convulsions, which continued till removal of osseous fragments after thirteen months. No symptoms six months later, except improving right hemiplegia.

(12) Necropsy in case of a demented criminal two years

after injury. Earlier mental condition not stated; cerebral convolutions atrophied; bullet encapsulated upon surface of occipital lobe; bullet track subdural but not traversing the brain.

(13) Wound in right parietal region; brain not penetrated; toy pistol; four years later, only symptom dilatation of right pupil.

(14) Wound through ear; petrous portion fissured at its base; bullet discharged six years later from an abscess in the throat.

(15) Wound of frontal lobe by a Minie ball; beginning of epileptic convulsions at the end of fifteen years, which became very frequent and severe. Bullet then removed from just within cranial cavity. Entire subsequent recovery.

(16) Wound of left frontal lobe; bullet of 0.22 cal.; epileptic convulsions four years later, becoming frequent at the end of thirteen years; trephination and removal of a fragment of bone and a piece of lead; convulsions not controlled. Death one year later from cerebral laceration, the result of a fall during a paroxysm. Bullet found in left trunk area, projecting through the cortex near the median fissure at the end of a membranous canal.

There are other cases of similar import in which recovery was not claimed.

(*a*) Bullet of small calibre made entrance through the chin. Death twenty days later. A canal extended through left frontal lobe, which was obstructed by reparative products; bullet in pus cavity at its farther extremity.

(*b*) Bullet traversed both hemispheres; death five months afterward. Bullet then found resting upon the dura mater covering the basilar process, having fallen

downward from an abscess cavity in the parietal lobe, at the end of its original course.

(*c*) Wound of left frontal lobe and death in twenty-two months; bullet and osseous fragments contained in a pus cavity beneath a depressed dural cicatrix.

(*d*) Wound in right frontal region and bullet removed after counter-trephination from abscess cavity in occipital lobe on twentieth day; death ten days later.

(*e*) Wound in mastoid region; unsuccessful operation on eleventh day after pyæmic chill; bullet found post mortem partly within lateral sinus.

In twelve cases of this series of twenty-one there was sepsis from abscess or necrosis of the cerebral tissue which was directly related to the retention of foreign bodies. In two the nature of the lesion was discovered by operation and the patient recovered; in ten death resulted, usually at an early period and without attempt at operative relief. In three of the fatalities, and in one of the recoveries, the bullet was contained in a superficial abscess cavity and was associated with osseous fragments; in seven of the fatalities, and in one of the recoveries, the cerebral lesion, whether abscess or simple necrosis of tissue, was dependent solely upon the presence of the bullet, which with one exception was at a distance from the wound of entrance. In all, symptoms persisted from the time of injury.

In another group of four cases, though the bullet remained in the cranial cavity, the brain was uninjured and there were no symptoms while the patient continued under observation, a period of from one and one-half to six years. In the one instance in which death is known to have occurred later, it was due to intercurrent disease two years after injury, and the bullet was encapsulated.

In still another group, also of four cases, after a lengthened interval in which no symptoms were noted, epilepsy occurred: in one, after several months, in one after thirteen months, in one after four years, and in the last after fifteen years. In three of them the attacks ceased: in one after the removal of the bullet, in one after the removal of osseous fragments, and in one without operation. In the fourth case the convulsions continued from the fourth to the fourteenth year, when death resulted from accident.

The final case of this series must be omitted from consideration, since the mental disturbance which followed was due to the laceration of the frontal lobe in the passage of the bullet and not to changes at the point of lodgement.

There are scattered cases of earlier date in which life has been said to have long continued despite the presence of a bullet in the brain. These histories are usually indefinite, but in some instances it seems probable that there were no important attendant symptoms.

It is evident that the retained bullet has proven a menace to life not only when associated with osseous fragments but of itself, and it is remarkable that an opposite opinion, supposed to be founded upon actual experience, should have become prevalent. There is probably no authenticated case of recent Anglo-American record in which a bullet left in the brain substance has failed to work mischief, nor has the evil been often long procrastinated. There have been occasional instances in which it has remained harmless for a number of years in the cranial cavity, but the brain has not been penetrated. The fact that epilepsy has developed so late as fifteen years after

injury must make even apparently exceptional cases doubtful.

It may be justly concluded from these actual observations, that:

1. The bullet left by necessity or choice within the cranial cavity is usually septic; and necrotic changes ensue with constitutional infection.

2. The bullet when aseptic may become encysted and may then be harmless, or, more probably, may be the source of dural or cerebral irritation at a perhaps distant period.

Second: it has been thought that while it may be safer to resort to operative measures, if necessary, for the exploration and disinfection of the superficial cerebral wound, the peril of the patient is augmented rather than diminished by an effort to extract the bullet from deeper parts. This belief, also, has been credited to the teachings of experience.

In the forty-nine cases which constitute the sum of this experience, as it has been made known in English and American record during the present surgical epoch, death occurred in one before deep exploration had been begun, and in another from anæsthesia before the beginning of operation. In fifteen cases operation was confined to the cranial wall or to the surface of the brain. There remain thirty-two cases in which the removal of the bullet from a distant point of lodgement was made or attempted. Of this number of cases, eighteen ended in recovery; in twelve of which measures instituted for the removal of the bullet succeeded, and in six failed. In fourteen fatal cases removal was effected in seven, and in seven failed. In the nineteen cases in which the removal of the bullet was success-

fully accomplished, it was withdrawn from the wound of entrance in but three, of which two ended in recovery. In sixteen cases in which it was removed through the oposite cranial wall, counter-trephination or its equivalent was done in six in which no counter-fracture existed, twice with recovery and four times with the subsequent death of the patient; in three other cases, all ending in recovery, serious operation was required; in the final eight, three of which were fatal, the bullet after simple external incision was removed from the bone or cerebral cortex. In the fourteen cases of failure to discover or extract the bullet, recoveries and fatalities were in equal number.

In the fourteen cases which proved fatal, whether or not the effort to remove the bullet was successful, death was due to septic infection in eleven, to age and shock of operation in two, and to shock alone in one. The salient points in their histories may be briefly stated:

(1) Trephination in left frontal and counter-trephination in right parietal region on the first day, and removal of bullet of 0.32 cal. from subcortical tissue after incision of the dura mater. Death twenty-four hours later from shock, due to age and unfavorable conditions, including extensive cerebral laceration at wound of entrance.

(2) Trephination in left frontal and counter-trephination in left occipital region, and removal of bullet of 0.22 cal. from one and one-half inches below point of counter-operation; drainage of both wounds, followed by small fungus cerebri in each wound with other symptoms of cerebral necrosis. Death in twelve days. No necropsy.

(3) Counter-trephination in left posterior cranial region twenty days after a wound inflicted through right malar

bone, and removal of bullet of 0.32 cal. from a pus cavity. Death ten days after operation.

(4) Trephination in left frontal, and counter-trephination in right frontal region on the fourth day; bullet not discovered; drainage tube through the brain. Death seven days later; purulent meningitis, and left frontal diffuse abscess. (Bullet in right orbit.)

(5) Trephination in right frontal region on the first day; osseous fragments removed, but bullet not discovered. Death on the twelfth day.

Necropsic conditions: Pus in the subcutaneous cellular tissue; purulent meningitis, and cerebral necrosis; osseous fragments found in the brain substance, and bullet of less than 0.22 cal. lodged in the right frontal lobe, three inches from the surface.

(6) Trephination of right mastoid on the eleventh day; previous pyæmic chill. Death on the sixteenth day, and bullet of 0.22 cal. found partly within the lateral sinus.

(7) Trephination in the right frontal region on the ninth day; large cavity, filled with blood and necrosed brain tissue, drained; bullet not discovered. Death on the fourteenth day, and the cavity found to extend to the occipital lobe; fragment of bullet near lateral ventricle.

(8) Trephination in right parietal region on the second day; bullet not discovered. Re-examination in another hospital on the thirtieth day; external wound infected; large cerebral cavity containing necrotic tissue and having firm walls. Death on the thirty-sixth day, and bullet found to have been deflected by falx cerebri one inch backward from the cavity previously recognized.

(9) Bullet removed from right petrous portion on the fourth day by finger and elevator after incision. Death

two days later; fissure found in petrous portion: purulent meningitis.

(10) Incision over counter-fracture in posterior temporal region on the fourth day, and bullet of 0.32 cal. removed from cerebral cortex; drainage tube. Death on the ninth day; drainage tube found to contain pus and its exterior covered with necrotic brain tissue.

(11) Incision over counter-fracture in right frontal region and removal of the bullet on the fourth day. Death in fourteen hours from "exhaustion."

(12) Removal of bullet from pharynx on the second day; the patient, aged eighty, then unconscious, with irregular respiration. Death in sixty hours.

(13) Probing to depth of two inches on the eighth day; pus and osseous fragments removed; bullet not discovered. Death from septic infection on the thirty-eighth day. No necropsy.

(14) Probing deeply through right frontal lobe on the second day; bullet not discovered; wound of entrance afterward healed. Death on the thirtieth day; bullet found surrounded by necrotic tissue in the left island of Reil.

It is apparent that in the greater part of these fatalities interference was deferred until septic changes had already occurred, with or without symptoms of general infection. Operation was primary in but three cases, and in four of the others indications of the constitutional disorder were already manifest. In the forty-two deaths which occurred in non-operative cases, inclusive of those already considered in relation to retention of the bullet and osseous fragments in the superficial cerebral wound, and exclusive of the ten in which it was a primary result of shock and

hemorrhage, all but four were occasioned by septic infection following a local lesion, abscess, meningitis, or cerebral necrosis.

The ultimate result, therefore, of a critical analysis of all the available records of practical experience, the court of last resort in matters of scientific opinion, is that the cause of death has been ordinarily the same, whether or not operative interference has been made; and that the percentage of recovery has been greater when operation has been performed. If allowance were made for the number of cases in which sepsis was declared prior to operation, or in which other antecedent conditions made interference practically hopeless, the statistical advantage of operation would become very decided.

The series of cases collated is practically complete within its limits of time and place. It has not included reports of cases from Continental sources, as their examination if made with equal care would have entailed an almost impossible amount of labor.

The statistical results which have been obtained have been only incidental to an exact determination of what have been the real teachings of experience. Their value in this relation is not to be questioned; they demonstrate the accordance of the facts of observation with general laws of surgery. The pathogenic germs are not less prevalent in the surroundings and instrumentalities of treatment of cerebral wounds than elsewhere, and it would be inconceivable that their preventive control or destruction should be less indispensable.

The propriety of operation having been established, its methods and limitations, and the details of treatment, are still to be considered.

When the general condition of the patient has so far improved that it has ceased to occasion immediate anxiety, the superficial and osseous wounds should receive more thorough attention. The surface should be cleansed and shaven, and search should be made for embedded grains of powder or remaining traces of smoke and flame, the cutaneous wound enlarged by incision, the extent of subcutaneous lesion determined, and the superficial soft parts made surgically clean. If there has been large comminution, the fragments of bone may require elevation, though in such cases the subjects rarely survive the immediate shock of injury. If, as is more probable, the fracture has been a simple perforation with possibly a fine marginal comminution, the osseous wound should be adequately enlarged by the rongeur, the dura incised, and whatever small detached fragments and foreign substances can be detected removed from the accessible part of the cerebral laceration. In those cases in which the bullet has made exit, the second wound in its superficial and deeper portions is to be primarily treated like the wound of entrance, and both wounds are to be closed with the usual aseptic precautions. It may happen that the bullet is lodged just within the cranial wound of entrance, or of exit, and may be readily removable. This fact is to be borne in mind in the preliminary examination.

The necessity of securing and maintaining the most perfect attainable asepsis is so well recognized as the inexorable law in all surgical procedures that it may be assumed to be enforced in whatever dressings, explorations, or operative interferences may be deemed proper, though its specific mention may be sometimes omitted.

It is at this point that differences of opinion have led to

differences in practice. These affect not only the attempt at removal of the bullet and foreign substances from deeper parts through the wound of entrance, and the resort to counter-trephination, but also the use of the probe and the extent to which mechanical drainage may be employed. The obligation of exploration, and of operation if practicable, can no longer be evaded when answerable conditions exist in the individual case. The analytic study of the results obtained in actual practice, and the disclosures of necropsic examination, leave no justification, and the authority of the general principles of surgery affords no warrant, for inaction. The opinion that the bullet is harmless while at rest, or if not harmless is less harmful than the effort to determine its position or to effect its removal, is disproved by the experience from which it claims to be derived. The evidence is conclusive that bullets when retained in the brain, even though encapsulated or unproductive of symptoms for a length of time, eventually lead to death, while their removal not infrequently permits recovery. The baneful influence exerted by osseous fragments, when left in contact with the dura mater or embedded in the cerebral substance, is even less likely than that of the bullet to be delayed by encapsulation or by the exceptional tolerance of a sensitive tissue; and the imperative necessity for their removal is even less an admissible question, as the record of cases has made evident.

An exaggerated estimate of the danger of necessary and reasonably skilful mechanical treatment of brain wounds was naturally made in the early days of aseptic methods before the mental focus had been adjusted to new conditions, and while men's minds were still dominated

by their earlier experience. It is more difficult to comprehend how it should prevail to some extent at the present time, when greater familiarity with aseptic laws has brought a juster appreciation of the widened limits within which surgical interference may still be conservative. The imminent danger of sepsis which once attended operative invasions of the great cavities of the body has been precluded, or at least made possible only by neglect; the real source of this danger is from within, where it is absolute, and not from without, where it is only contingent. The peculiar peril of such operations arises from the occurrence of shock, when they are too extensive, too sanguinary, or too much prolonged. The brain tissue is not especially tolerant of mechanical injury, but the procedures taken to discover or extract a bullet need never be made a test of its endurance. The proper use of the probe is confined to the existent wound, so that contact is made only with already disintegrated tissue which is no longer capable of irritation; the penetration of adjacent uninjured parts is not contemplated and is indefensible. This withdrawal of a foreign body from along the track which it has followed will, if it be deeply situated, probably involve additional laceration. The extent of visceral injury necessary to the extirpation of a clearly diagnosticated and accessible brain tumor of moderate size has not prevented its acceptance as a justifiable operation in surgery. The bullet, rendered accessible by the wound which it has made and traversed, its situation clearly defined by the probe, its size necessarily small but its capacity for mischief unlimited, can be ordinarily extracted with less injury or destruction of tissue, and with less hemorrhage or expenditure of time, than the smallest conceivable tumor. The

simple fact that some additional brain laceration must be involved in the withdrawal of a bullet is evidently insufficient reason to forbid the attempt, though its probable extent may be a sufficient contraindication in individual cases. The possible capacity or technical skill of the surgeon cannot be ignored in such a review of the subject, but its adequacy must be assumed in a general discussion of surgical propriety.

In view of these several facts and inferences, it may be regarded as established that if the bullet remains within the cranial cavity an effort should be made to determine its location, and if detected that the advisability of an attempt to effect its removal should at once be brought in question. It may be so readily approachable, and its removal so evidently practicable, as to leave no room for hesitation; or its situation may be so uncertain or so inaccessible that to attempt operation, or to refrain, may seem fraught with equal danger, and the decision will then require the exercise of great discretion as well as of careful and perhaps prolonged examination. The advantage of the earliest possible interference, in view of the patient's general condition, if it is to be made at all, is as positive here as it is in amputation for trauma involving the extremities. The comparative tolerance exhibited by the recently wounded brain to further injury by operation should be given much weight as an element in the consideration of all very recent cases in which doubt exists in deciding upon a policy of action or inaction. The imminence of septic infection from the earliest moment, and in its face the probable futility of a deferred operation, are still more potent reasons for quickness of decision and for promptitude in whatever action is to be taken. The data

and conclusions of writers of a somewhat earlier period are no longer of authority. The fact that the missile of which they wrote was the musket or rifle and not the pistol ball, is perhaps of no great importance, nor even the changes which have been made in its weight, form, and velocity, if lodgement has been once effected; but the methods of surgery have so radically changed with more exact knowledge of pathology that the propriety of operations generally must be reconsidered and new rules of procedure formulated.

The first step in the attempted removal of the bullet, the exploration of the cerebral wound with a view to localization, is not only a diagnostic method but an incident of treatment. The necessity of some explorative invasion of the cranial cavity is always involved; for, even though the bullet rest in the external wound, more dangerous osseous fragments may yet lurk beneath the cranial opening. The extent to which it may be properly carried and the manner of its pursuance still require consideration. The fundamental law which should govern the surgeon in his choice and use of the means of exploration is that the least possible additional laceration, compatible with the attainment of the information sought, should be inflicted. It is desirable that a single instrument should be selected, preferably that of Fluhrer or of Girdner as best suited to the purpose, and that no substitution of one instrument for another should be subsequently made except for sufficient and well-defined reason. If the probe first employed should have a bulb too large, or be otherwise unsuited to follow the path which the bullet has opened, it should at least indicate with precision the character of the one which should take its place. The utmost caution should be ex-

ercised to keep within the wound, since false passages are as readily made and, when made, as embarrassing to further exploration as those which follow the reckless use of the urethral sound. It has been held that when the probe ceases to advance without the exercise of force, the limit of persistence has been reached. This is approximately rather than exactly true. The probe does not fall by its own weight into the depths of the cerebral wound. The channel which the bullet has left behind it is not likely to be open, but filled with coagula and disintegrated tissue, and some force, gentle as it may be, is required to penetrate this pulpy mass, and some manipulation alone can guide the instrument past obstructing osseous fragments or through an intracerebral dural opening. The judgment of the surgeon must decide what measure of force is excessive, as the acuteness of his perception must indicate when the bulb impinges upon the denser but still tender wall of normal structure. The work of exploration may be tedious, but time is of minor importance, while caution is imperative.

The bullet, if not at once deflected, ordinarily holds a straight course into the opposite hemisphere; it is better, therefore, if the track can be followed deeply but without result, to resume the search from the opposite cerebral surface. If the track be lost near its outset, the osseous wound should be further enlarged and the brain incised to reach and follow its new departure. The manipulation of the probe should be not only gentle and cautious but always directed by a settled purpose, and, this accomplished, should be at once abandoned. When the surgeon, disappointed and impatient at failure in his quest, thrusts the instrument into the brain recklessly and at random,

or nervously again and again explores a channel which the first examination shows to lead to nothing tangible, in the hope that some chance may disclose to him what his intelligence has been unable to discover, no good and much harm may come from it. Every misdirected or superfluous insertion of this small instrument may increase already dangerous laceration and hemorrhage, and invite already imminent necrosis of tissue and subsequent general sepsis. These rules of conduct in the employment of the probe are simple, and may seem too obvious for much insistence, but their neglect and its known results have excited a popular prejudice against its proper and necessary use, which has in turn sometimes engendered too much timidity on the part of the surgeon. The instrument first chosen, if unfit or if it has served its purpose, should be unhesitatingly changed; investigation should be thorough, but nothing should be done without reason; force should never take the place of art, and no dependence should be had upon the aid of accident.

If the bullet cannot be detected by the probe, there may be circumstances which invite the use of the needle. A resistance may be felt which the blunt instrument fails directly to reach; there may be reason to believe that the missile lies near the cerebral surface while an angle in its track prevents direct pursuit without incision; a deeper wound may be too tortuous to follow; or localizing symptoms may have been developed; any one of which conditions might justify this resort. The wound made is so minute that hemorrhage is inconsiderable, and laceration can be scarcely said to be produced. The experience gained in the use of this sort of puncture in cerebral oper-

ations which have not been necessitated by traumatism confirms its comparative if not absolute safety. There may be other indications which the exigencies of a case will suggest, but, while even occasional instances of fatality from this seemingly harmless method of investigation are recorded, its purely empirical employment should not be recommended.

In those cases in which from shortness of range or profuseness of hemorrhage, or at a later period from neglect, there may be much laceration or disintegration of brain substance, the finger may well supersede any other medium of exploration. It is more sensitive than metal and is in immediate in place of indirect communication with the guiding intelligence, and, as room is already provided without new destruction of tissue, there is nothing to counterbalance the positive advantage which it offers. This gives no warrant, however, for its introduction in ordinary cases in which the track is comparatively narrow, and in which the violent invasion of an organic structure heretofore intact must necessarily add a new element of danger.

There are exceptional cases in which there may be sufficient reason to believe that the bullet has escaped from the cranial cavity to justify an abandonment of cerebral search, even though the point of exit may not be discernible. Its course may be so manifestly toward the orbit, or subbasic or suboccipital region, that, in the absence of serious cerebral symptoms and after fruitless exploration of the cerebral wound, it may be judicious to assume this extracranial lodgement and to await the possible development of local confirmatory symptoms. It may even happen, as in several of the accompanying series of cases,

that the osseous exit into the base or orbit may be discovered.

The bullet having been recognized in an accessible region of the brain, the same care, gentleness, and avoidance of cerebral laceration which are essential in the determination of its position should be observed in the use of instruments for its removal. The particular instrument employed, if adapted to its purpose, is of less importance than the manner of its use. The operation is often difficult and may be sometimes judiciously abandoned; the bullet, already deeply situated, may with every effort at extraction sink deeper into the yielding tissue in which it is embedded and in a direction inaccessible for counter-operation, or until its removal, if finally accomplished, would involve lesion of the brain substance so extensive as to entail greater danger than would result from leaving it undisturbed. If pursuit be abandoned from the rear, there remains the resort of attacking it from in front. The bullet may have originally occupied, or been forced into, a position in which it is in evident close contiguity to the superior orbital plate. If the effort to withdraw it through the wound of entrance seems hopeless without too greatly destructive laceration of brain structure, success may attend approach through the orbit. An incision may be made which will permit the enucleation of the eye and its appendages *en masse*, and their replacement without subsequent deformity or injury to vision. The bullet is then reached through the orbital wall at the point indicated by the probe passed through the cerebral wound. The same method is applicable when the original lodgement of the bullet is effected within the orbit. If vision has been destroyed by intracranial or orbital injury, or by

lesion of the optic nerve as it passes through the optic foramen, operation will be simplified by the necessary removal of the eye.

The equivalent of the operation through the orbital plate is found in counter-trephination through the opposite wall of the calvarium which has remained intact. It is indicated in a case in which the bullet has been discovered deep in the substance of the brain, perhaps across the median line, the attempt to withdraw it having been foregone as fruitless or desperate and with no hope of reaching it through the orbit; or when, the bullet having been traced far inward, its track has been utterly lost, and no clew exists to its place of lodgement. There is no alternative, except the chance of recovery with the bullet left undisturbed or this single operative resort. It is a dilemma in which inaction, the easier course, seems to have been the oftener chosen in the few instances in which, as it would seem, such an operation might have been undertaken with fair prospect of success. The early successful cases of Larry and Charles Bell are familiar. In recent years but five others have been recorded, of which four proved fatal. Fluhrer's case in 1884, followed by recovery, has attracted much and deserved attention. The bullet of 0.22 cal. penetrated the mid-frontal region, and was followed by the probe for six inches through the left frontal lobe and falx cerebri into the opposite hemisphere. The cranial wall on the right side was trephined three-fourths of an inch below the point at which the instrument if projected would emerge, and the dura was incised. Following a trail of blood and later of brain matter, the bone was cut away and the dura further incised till a wound in the pia was discovered, through which the bullet was removed from one-half inch

below the cerebral surface. The only reported case of removal of the bullet from the brain through the orbital wall, Case CCXCIV. in the accompanying series, is practically of the same character, though the chisel was used in place of the trephine. Operation was done on the second day, with a rectal temperature of 104°. The wound of entrance in the right temporal fossa was enlarged by the trephine, fragments of bone were removed, and the bullet was discovered near the optic foramen. The eye, which was distended with blood, was removed; the superior orbital plate, which was much comminuted by fissures, but not broken through, was perforated by the chisel; the dura was incised, and the bullet removed from the cerebral cortex. The patient eventually recovered. The necropsic examinations included in the series of published cases disclose occasional instances in which the directness of the bullet's course, and its lodgement near the cerebral surface in an accessible region, would have made such operations anatomically possible, and which the histories show would have been clinically proper. Their number, after an eliminative process by death before reaction, by extraction of the bullet through the wound of entrance, or by an obvious impropriety of further interference, is necessarily very limited.

The justification of counter-operation through the uninjured cranial wall in properly selected cases is based upon the same considerations which justify the use of the probe for localization and, under suitable conditions, the effort to withdraw the bullet through the original wound. The avoidance of sepsis, and the conduct of operation in such manner as to limit shock, are no less under the control of the surgeon, but, as additional and more considerable injury is to be inflicted upon the brain, still greater

caution, if not more conservatism, in estimating the relative danger of an aggressive and of an expectant policy will be required.

The circumstances adverse to this operation are: First, a bad general condition of the patient succeeding primary shock, a high temperature, a feeble and frequent pulse, and other indications of an inability to sustain the shock of further cerebral injury; second, extensive cerebral laceration about the wound of entrance from the explosive effect of a large bullet at close range, or a suggestion of wide destruction in its track from the severity and diversity of localizing symptoms; third, great uncertainty as to the course of the ball, or its direction toward an inaccessible cranial region; fourth, the fact that its course has involved the base of the brain; and fifth, the bullet having been of 0.22 cal. or less. The fact that the bullet has taken its course upon or near the basilar surface is to be regarded as a contraindication, because it is more than likely to be deflected near the median line into a central region of the brain by resistance offered by some part of the ethmoid or sphenoid, or by the basilar process of the occipital bone. The fact that the bullet is of 0.22 cal. or less is a contraindication, because its course is usually erratic and its track minute, and because its momentum is so comparatively slight that it rarely reaches an accessible part of the opposite cerebrum. No one of these contraindications of course is an absolute bar to operation. If, on the contrary, the constitutional condition is good and the laceration is confined to a narrow track, if a bullet of 0.32 cal. or larger has been driven through the central or upper regions of the brain toward some part of the vault, if its track can be traced deep into the opposite hemi-

sphere, and more especially if the patient has the advantage of youth, it will be judicious, after the exhaustion of other means, to resort to this ultimate method of relief.

If the counter-operation be resolved upon, it is well to regard it in the first instance as simply explorative. The cerebral surface having been exposed, and the area of exposure having been increased at discretion without perceptible evidence of lesion, the operation may be properly terminated at this point, unless the bullet can be discovered by palpation, or unless its position has been ascertained by the exploration of the original wound to be of easy access through the new incision. This amount of additional or secondary injury, confined essentially to the scalp and cranium, can be inflicted with almost absolute safety, provided sufficient care is taken to control hemorrhage. If, however, a trail of blood or of particles of brain matter can be traced to a wound in the cerebral cortex, or if the color and consistency of the surface indicate subjacent laceration, the operation should be continued with a view to extraction of the bullet, and no harm can come from incision of the already lacerated tissue. If the patient be enfeebled by age or be in ill condition, and much blood be lost in the incisions of the scalp and dura, or if the uninjured brain be too freely wounded in exploration, the operation may readily lead to disaster.

Such methods of treatment as have been outlined are in consonance with present views of the proper utilization of the surgical resources at command for the management of lesions of the great cavities. Ideas are no less conservative than formerly, but conservatism is more intelligent. Ten years and more ago it was the fashion to abstain from interference with gunshot wounds of the brain, to the ex-

tent of leaving the bullet or fragments of bone at the very entrance of the cerebral track or even beneath the skin at the point of exit. It was considered proper to depend wholly upon aseptic treatment as represented by covering the external wound with a single layer of carbolized lint. The principles of asepsis were recognized, but their applications were primitive and inefficient, and the journals of the period contain many histories of this kind with answerable results of septic inflammation and death. It is characteristic of the present epoch to employ available instrumentalities to their full extent, and to pursue to a logical and practical result whatever advantage they may offer. The later consideration of prognosis as affected by the removal or retention of the bullet will demonstrate the conservatism of what under imperfectly appreciated conditions were regarded as radical measures.

The final point in treatment, in regard to which difference of opinion may exist, concerns the methods of disinfection and drainage of the cerebral wound. The bullet, whether it has pierced the opposite cranial wall, or been removed by counter-trephination, or has been withdrawn through the track by which it entered, has necessarily left an area of disintegrated and dead tissue which may become the source of subsequent general infection. This danger, which was noted as attendant upon cases of ordinary brain laceration without external injury, is, of course, more imminent in gunshot cases, in which sepsis is not only possible from original contamination by foreign substances, but from continued exposure to atmospheric influences. The dvantage to be derived from drainage and disinfection is yond question; the extent to which it may be justifia- r profitable to subject the brain tissues to mechanical

interference in the pursuit of these objects is still a matter of somewhat varied opinion and practice. It must not be forgotten that the brain is permeable to fluids, and that less sensitive structures suffer from the irritation of drainage tubes when too freely used or too long continued in the wound. The irrigation of the brain and the insertion of drainage tubes into and through its substance should be practised with great reserve, lest their good results be more than counterbalanced by the structural injury which they inflict. The cases in which neither bullet nor other foreign body has been found in the deeper wound, and in which the track is narrow, will be more safely treated if aseptic fluids are confined to the external parts and to the cerebral cortex, and the removal of the more inaccessible coagula and *débris* of tissue is trusted to absorption and natural drainage. The other cases, in which greater and more widespread damage has been done to the central regions of the brain by the extraction of the bullet or of large fragments of bone, or by complete perforation by missiles of large calibre, demand more active interference. In the irrigation which may then become advisable the prompt return of the antiseptic fluid should be insured by a dependent position of the external wound, by the use of a double catheter or by other adequate means, and its flow should not be unnecessarily profuse. The drainage tube, if used at all, should be withdrawn and abandoned at a very early period, usually on the second day. If drainage is to be maintained for a longer time, horsehairs or threads of chromicized catgut may replace the tube, and their number be reduced from day to day. Certain objections made to the drainage tube by Hunt in the Australasian-Intercolonial Medical Congress of 1892 are

worthy of especial consideration in relation to deep cerebral wounds:

(1) That it is an irritant foreign body.

(2) That it is likely to become filled with clot, and then act as a plug rather than as a drain.

(3) That it is a medium for the deep implantation of septic elements when the surface has become infected.

If the preparation of the tube and the treatment of the wound do not absolutely preclude the possibility of the development of septogenic germs, it is liable to become a no less deadly weapon than the pistol itself.

The reiterated injunctions to observe aseptic care which garnish all modern discourse upon surgical procedure doubtless grow wearisome; but like admonitions to virtue they are always in season, and are nowhere of more vital importance than when they concern operations within the cranial cavity. The arachnoid is more sensitive than the peritoneum, and the brain less tolerant of disturbance than the abdominal visera; septic infection is even more prone to follow errors in technique, and its results are more disastrous than in abdominal operations. In exploration, therefore, not less than in operation, and in the general treatment of intracranial wounds, the most rigorous exactitude is demanded in every detail of aseptic precaution. The responsibility may then be justifiably assumed by the surgeon of using such methods of examination as are necessary to an intelligent apprehension of the conditions of a case and to the subsequent adoption of the course of procedure most likely to insure the eventual safety of the patient.

Prognosis.

The general prognosis of intracranial pistol-shot wounds is absolutely bad; worse probably than in any other class of bodily injuries. Its numerical expression, while not to be altogether discarded, is of comparatively little value. In the series of reported cases collected for the present study of such injuries, the fatalities are only slightly in excess of the recoveries; these cases, however, have been exclusively those which have survived primary shock and hemorrhage, and in many instances they have been avowedly or presumably reported because they were recoveries, and of special interest on that account. In Bradford's tables, again, deaths are recorded in more than half the total number of ninety-one cases; in twenty-two of these, a group comprising all those in which the patient lived to reach the Boston City Hospital, but five survived. In Wharton's tables the comparative secondary mortality is practically the same. Bryant's tables were compiled largely from cases not of pistol-shot origin, and are therefore not pertinent to the present inquiry. In the annexed series of personal observations death occurred at once or within the first hour in fifteen cases, within twelve hours in seven cases, and in from fifteen hours to forty days in ten cases. Apparent recovery followed in but eight cases. This last showing of comparative results is still fallacious, as only a small proportion of the immediately fatal cases is brought under professional observation, even at the morgue. As likely to afford upon a scale of sufficient magnitude the most exact knowledge possible of the great fatality of pistol-shot wounds of the brain, a record was made of all such cases reported in the New York *Herald*, as occurring

in New York and its immediate neighborhood, during the year ending December 31, 1896. This summary comprises accidents, suicides, and homicides, in which wounds were inflicted by weapons of all calibres and under all conceivable circumstances. In a total of one hundred and thirty-seven cases, the subject was found dead or death occurred at once in ninety-nine; twenty-one others were known to have proved fatal at some later period, from a few hours to one or two days; and in eleven the probable result is not indicated. In six cases only recovery was assured or can be reasonably inferred from the circumstances noted. This comprehensive notation of a circumscribed class of pistol-shot wounds permits a much more precise estimate of general prognosis than could be made from clinical observation. It is doubtful if statistical researches are of real importance except for the expression of such elementary facts. They may sufficiently determine, as in this instance, the question of general prognosis, expressed in numerical terms, since life and death are alone involved with no conditions beyond the causation and location of the wound.

Death is the result in so large a gross proportion of cases that it is obvious concomitant circumstances are not largely influential in prognosis. In suicide the range of fire must always be within the limit in which necropsic observations have shown that it does not materially modify effects, and accidental and homicidal wounds are usually inflicted within scarcely greater distances. At these ranges, a bullet, whether of large or medium calibre, has sufficient momentum to penetrate the cranium, whatever its density or thickness, and to occasion equally extensive cerebral injury. Bullets of 0.22 cal., however, must be excepted from these general statements formulated for

missiles of larger size. It has been noted in cadaveric experimentation that with this calibre penetration is less certain; it may fail if the cranium be both thick and dense, even at contact or at short ranges, unless the weapon be of the best type and the explosive of the best quality. The difference in extent of cerebral laceration as produced by bullets of 0.32, 0.38, and 0.44 cal., though sometimes manifest, is not sufficient to be of practical importance; but with a bullet of 0.22 cal. it is distinctively less, enough so to diminish the primary danger from shock unless some large meningeal vessel has been wounded. It is noticeable on a recurrence to published cases, in which immediate danger was surmounted, how frequently the calibre when mentioned was 0.22 or less; and wounds of the head when made by bullets of these small calibres have been generally regarded as involving a minimum amount of danger. The proportion of absolute recoveries is doubtless greater than with the larger calibres, not only from more frequent lack of penetration and from lesser cerebral laceration, but from the smaller number and minuter size of the osseous fragments which are driven into the brain substance, and which experience has shown to be the most active agents of septic infection. The recoveries are still comparatively few; the most vulnerable point for cranial penetration is usually though ignorantly selected in suicides, which constitute by far the largest class of these cases; and if an immediately fatal hemorrhage from division of some large meningeal vessel is evaded, the smallness of the bullet permits it to traverse long distances through the brain, with corresponding liability of realizing conditions of immediate danger; and though it reaches some distant point, in which it is lodged

without having directly brought life in question, there still remains the peril of changes in organic structure from sepsis or irritation which may make death its inevitable sequel though long deferred.

The one important element of special prognosis is to be found in treatment. The several causes of death are shock, hemorrhage, sepsis, and irritation of the cerebral tissue from the presence of a foreign body. If shock is sufficient to endanger life, there is not often time for interference, and the source of hemorrhage is likely to be beyond the reach of hæmostatics; but so far as treatment is possible, there can be little question as to its methods and none which can modify prognosis. The occurrence of septic infection, which is an imminent danger in all cases, and to which the majority succumb, may be amenable to both prophylactic and curative means, and the early extraction of the bullet and osseous fragments, when practicable, obviates the later danger from cerebral irritation. The resort to judicious measures, therefore, for the prevention or control of septic infection, and for the removal of causes of cerebral irritation on the one hand, or the abstention from their use on the other, must necessarily influence the result in individual cases and become a factor in its prediction.

The better chances of recovery when the necessary means are employed for thorough exploration of the wound for the removal of septic foreign bodies, and for the maintenance of aseptic conditions, is evident from analysis of the practically complete series of published cases. A study of this character to determine general principles is apart from mere statistical tabulation, in which incongruous cases are collated, and in which from the omission of

necessary elements of comparison untrustworthy conclusions are deduced. The established facts that in the case of patients surviving the immediate effects of injury a majority die either at once from sepsis, the result of the retention of foreign bodies within the cranial cavity and a concomitant lack of disinfection, or at a later period from the irritation which they occasion, and that present surgical resources are adequate to avert danger of primary or added septic infection from operative interference itself, make the conclusion irresistible that exploration and if possible the removal of the bullet and other alien substances increase the prospects of recovery, whatever may be the attendant conditions. The cases which have collectively afforded these basic facts have been sufficently analyzed and summarized in the previous consideration of treatment.

The choice of means, of instrumentalities to be employed in the application of the general principle, has not been similarly determined, though various authors have tabulated results with this purpose in view. They have failed in showing either that essential conditions were comparable or that proper discretion was exercised by the surgeon. Elaborate computations of the number of cases probed, trephined, or subjected to no interference whatever, and made with sole reference to the death or recovery of the patient, or enumeration of the results of wounds of the several cerebral lobes inflicted under diverse conditions, simply add to that constantly growing fund of useless knowledge to which the most of us are misguided if not guilty contributors. The bald fact that death followed the use of the probe or of the trephine in a certain number of cases and recovery in a certain number of others, while

neither the necessity for its use nor the manner of it, neither the previous hopeless or hopeful condition of the patient nor his subsequent treatment, is in evidence or is given consideration, is not only unimportant, but when stated with the formality of a statistical result is likely to be positively mischievous as leading to unjustifiable inference. In like manner, the formulated fact that in a limited number of cases with imperfect histories a greater number of deaths occurred with or without resort to operative measures can have no legitimate value as a basis for conclusion or practice. The opinion which has obtained, and is reflected in the histories of cases, that a bullet once within the cranial walls is *tapu*, and which has more than once permitted a patient to die from septic infection without examination of his wound, and with a bullet or osseous fragments lying almost upon the cerebral surface, has had its origin in a fatuous belief that numerical statements are infallible and that treatment is to be conducted in accordance with inflexible rules. The general method of treatment is to be deduced from the general laws of surgical procedure and confirmed by the results of observation; but its details in their application to individual cases involve so complex and unstable conditions that they must be determined in each instance by the judgment of the surgeon. The thorough exploration of the wound, and if possible the extraction of foreign bodies, are prescriptive; the practicability of operation, and the means for its accomplishment, lie within his discretion.

THE CONDENSED HISTORIES OF

THREE HUNDRED INTRACRANIAL TRAUMATISMS

SELECTED FROM A SERIES
OF FIVE HUNDRED ORIGINAL CASES

I.

CASES VERIFIED BY NECROPSY.

Fractures of the Cranial Base.

Case I. *Symptoms.*—Wound in left posterior parietal region; hemorrhage from left ear; wild delirium; high temperature; coma. Death in forty-eight hours.

Lesions.—Fracture of left temporal bone, with separation of its constituent parts—squamous, petrous, and mastoid. Laceration of both parietal and right temporal lobes.

Case II. *Symptoms.*—Delirium, which was considered alcoholic; walking case; treatment refused; suicide by drowning on the following day.

Lesions.—Fracture extending from left parietal eminence to foramen magnum. General cerebral and meningeal contusion, and cortical laceration of right temporal lobe.

Case III. *Symptoms.*—Wound in right superior posterior parietal region; hemorrhage from right ear and later from right nostril. Coma; stertor; general muscular rigidity; dilatation of left pupil; left hemiplegia after twelve hours, and recurrence of hemorrhage from the ear, with disappearance of stertor and muscular rigidity; urine not controlled; consciousness not regained. Death in six days.

Lesions.—Fracture extending from point of injury through right petrous portion and middle fossa. Laceration of inferior and external surfaces of left frontal and right temporal lobes; corresponding cortical hemorrhages, thinning toward base and vertex; excessive general hyperæmia.

CASE IV. *Symptoms.*—Compound depressed fracture, external to right parietal eminence; found on trephination to be confined to external table, with fissures extending into middle fossa. Semi-consciousness, mild delirium, imperfect articulation, with slow and irregular respiration, which continued for three days; paralysis of right upper extremity and of right upper and lower face, differing in degree at different times; mental condition varying from normal to one of noisy delirium; patient usually restless, and during last two days unconscious. Temperature on admission, 101°; during first week, 100°; in second week, 99° +; and rose steadily from 103° to 109° through last two days. Death in forty-five days.

Lesions.—Subarachnoid serous effusion; subcortical cavity beneath the point of osseous depression, of large size, containing a reddish semifluid material and brown detritus; cortex not wounded; excessive general hyperæmia.

CASE V. *Symptoms.*—Stupor; gradual unconsciousness; delirium requiring mechanical restraint. Temperature on admission, 102°; ten hours later, 105°; declined to 101.8°, and then rose steadily to 106.6°. Death in twenty-nine hours.

Lesions.—Wound over occipital tuber, and extravasation of blood over whole calvarium; no fracture of vertex, but a fine fissure along posterior border of right petrous portion. Pial hemorrhage over superior surface of both hemispheres; laceration of left frontal, and both temporal lobes, and of inner border of right frontal lobe.

CASE VI. *Symptoms.*—Stupor; incoherence; dilatation of left pupil; slight deviation of eyes to the right; later, delusions, delirium, muscular tremor, irregular pupils, frequent and intermittent pulse. Temperature on admission, 103°; five hours later, 102°; and rose to 106.2°. Death in twenty-four hours.

Lesions.—Wound in right parietal region; linear fracture extending through whole length of right parietal and occipital bones, and through petrous portion into middle

fossa; considerable laceration of inferior surface of left frontal and of left temporal lobes.

CASE VII. *Symptoms.*—Patient fell upon the sidewalk, and was admitted to the hospital twenty-four hours later. Œdema of the scalp under and about an old cicatrix behind the right ear, and beneath this an extensive comminuted fracture; two fragments of bone were removed, and one was elevated, and a large epidural clot extracted as far as possible. Stupor; hemorrhage from right ear; irregular pupils; general muscular rigidity; ataxic gait; diminished sensibility, and loss of urinary control. On the fourth day temperature normal, mind clear, and muscular rigidity lessened; copious serous discharge from right ear and right facial paralysis; on the fifth day increased muscular rigidity and recurrence of stupor; on the sixth day, unconsciousness and frequent general convulsions. Temperature on admission, twenty-four hours after injury 99° +; on the fourth day, normal; on the fifth day, 100° +; on the seventh day, 105°. Death on the seventh day.

Lesions.—The whole central portion of the occipital bone from the foramen magnum upward, and posterior portion of both parietal and right temporal bones, forming an irregular circle from two inches and a half to three inches in diameter, were broken into large fragments, two of which had been removed during life. The mastoid and outer part of the petrous portion of the right temporal bone could be removed by the fingers with the use of very little force. This line of fracture ran through the tympanic cavity, so that after removal of the outer fragment the carotid canal and aqueductus Fallopii, filled with coagula, could be seen in the section. A large epidural clot was situated beneath the occipital fracture, extending half an inch beyond its margin. A large subdural clot filled the right inferior occipital fossa, extending to the foramen magnum. The cavity of the posterior part of the great longitudinal sinus was occupied by a thrombus, and its

walls were infiltrated with blood. There was a large partially decomposed thrombus in the torcular Herophili, extending through the right lateral into the petrosal sinus and internal jugular vein. The whole internal surface of the dura beneath the seat of the external hemorrhage was lined by a firmly coagulated clot with an inflammatory exudation around it. A portion of the surface of the right occipital lobe posteriorly was softened, showed minute hemorrhages, and was torn away in the removal of the dura. The meshes of the pia mater over a large part of the parietal and occipital lobes posteriorly were distended with slightly turbid serum. There was a small laceration on the under surface of each frontal lobe and a larger one, three-quarters of an inch in diameter, in the right cerebellum at a point corresponding to the site of the thickest part of the subdural hemorrhage.

CASE VIII. *Symptoms.*—Œdema of scalp in right parietal region, and fracture discovered by incision. Coma, stertor, general muscular rigidity most marked on the right side, and strong contraction of both pupils most marked in the left; no change in general condition till death fifty-four hours later. Temperature on admission, 100.4°, rising progressively to 103.8°, with immediate post-mortem recession.

Lesions.—Fracture extending from posterior and inferior part of right parietal bone to right jugular foramen, and then turning backward to foramen magnum. Laceration of anterior border of left temporo-sphenoidal lobe and of the anterior and internal borders of both frontal lobes; cortical hemorrhage covering the whole base of the brain; subcortical laceration with clot occupying the whole interior of the left frontal and temporo-sphenoidal lobes, and filling with blood both lateral ventricles and both occipital lobes; slight epidural hemorrhage at point where fracture began in right inferior and posterior parietal region; slight subarachnoid serous effusion; thrombus extending from

torcular Herophili through right occipital and inferior petrosal sinuses into the jugular vein.

CASE IX. *Symptoms.*—Partial unconsciousness for twenty-four hours; became complete; hemorrhage from both nostrils and from right ear; delirium on the fifth day with post-cervical muscular rigidity, restlessness, and retraction of the abdomen; Cheyne-Stokes respiration and death. Temperature for three days, 99.2°; on the fourth day, 103.2°; on the fifth day, 104.8°.

Lesions.—Contusion over right mastoid revealed on raising the scalp. Fracture at base in three fissures, extending from this point; two (fine) across petrous portion, and a third connecting these posteriorly across occipital bone. Deep linear laceration, extending across inferior surface of right cerebellum, near outer border. Cortical hemorrhage over whole left cerebrum, superiorly and laterally; most copious in middle lateral region. Laceration of antero-inferior border of left frontal lobe. White substance of left cerebrum much congested, and with punctate extravasations throughout its extent.

CASE X. *Symptoms.*—Semi-consciousness and left hemiplegia, followed by irritability; hemorrhage from left nostril; depressed fracture involving left frontal eminence; bone elevated. Death in twenty-four hours.

Lesions.—Coronal suture separated on right side; multiple fissures, one extending through body of sphenoid bone into left middle fossa, and others through right middle and anterior fossæ, external to orbital plate. Epidural hemorrhage in left temporal region; laceration of right frontal and right temporal lobes, and of left temporal lobe.

CASE XI. *Symptoms.*—Coma, stertor, dilatation of left and contraction of right pupil, paraplegia, hemorrhage from left ear and nose and under left conjunctiva, and contusion over left eye. Death in five minutes after admission.

Lesions.—Linear fracture extending downward and for-

ward from behind left parietal eminence, across petrous portion, through middle fossa, transversely across anterior fossa, and terminating in right lesser wing of sphenoid bone. Epidural hemorrhage, blood still fluid; slight lacerations of inferior surface of left frontal and temporal lobes and trivial cortical hemorrhage; excessive general hyperæmia.

CASE XII. *Symptoms.*—Contusion in right parietal region, hemorrhage from left ear and nose, loss of fæcal and urinary control, right hemiplegia; temperature on admission, 99.4°. Death in two days.

Lesions.—Fracture extending from right parietal eminence to foramen magnum, of right petrous portion through its whole length, and of left petrous portion for two inches. Laceration of left parietal lobe, and cortical hemorrhage.

CASE XIII. *Symptoms.*—Coma, stertor; normal pulse, respiration, and pupils. Death in five days.

Lesions.—Fracture extending from beneath a contusion near right parietal eminence downward and forward, anterior to petrous portion, through middle fossa and sella turcica. Pial hemorrhage over both hemispheres; laceration of inferior surface of left temporal lobe.

CASE XIV. *Symptoms.*—Patient knocked down by a blow in the face; momentarily unconscious, then walked to the hospital, and afterward walked home. Severe pain in head for three hours, gradual supervention of coma, which became complete in four hours. Death in eight hours.

Lesions.—Wound of lip and contusion of forehead. Linear fracture of external table extending from right inferior occipital fossa across petrous portion. Slight epidural hemorrhage beneath the fracture; large pial hemorrhage over external aspect of left frontal and parietal lobes, with some extravasations into the pia mater; slight limited contusions of brain substance.

CASE XV. *Symptoms.*—Coma; dilatation of right and contraction of left pupil; right hemiplegia; pulse became

slower, and respiration more labored. Death in nine and one-half hours.

Lesions.—Contusion in left parietal region, and fracture extending from that point by two fissures through parietal bone into anterior and middle fossæ. Large epidural hemorrhage from rupture of left middle meningeal artery; slight laceration of left parietal lobe at point where fracture began and another upon lateral border of left temporal lobe.

CASE XVI. *Symptoms.*—Loss of consciousness followed by stupor, slight but increasing dilatation of left pupil, slight hemorrhage from left ear, slight rigidity of left side, and labored respiration; temperature 99°; left hemiplegia first affecting lower extremity; temperature 101.2°. Death in twenty-one hours.

Lesions.—Contusion of scalp in left occipito-parietal region; stellate fracture in centre of left parietal bone; fissures which extended toward median line, into inferior occipital fossa, and along upper border of petrous portion into middle fossa. Recent laceration of inferior and lateral surfaces of right temporal lobe, and of inferior surface of both frontal lobes along median fissure; old laceration of inferior surface of left temporal lobe; deep and irregular in outline, lined with a grayish-yellow viscid substance, surrounded by an area of yellow softening, and about one inch in its several diameters; smaller old lacerations, presenting similar characters, of inferior surface of left frontal lobe. The recent right temporal laceration was of large extent. Extensive cortical hemorrhage over right cerebrum, and well-marked general hyperæmia of brain.

CASE XVII. *Symptoms.*—Loss of consciousness, dilatation of right and contraction of left pupil, right hemiplegia, full and slow respiration; pulse, 66. Death in eleven hours.

Lesions.—Contusion of left parietal region, from the site of which one fissure extended into the anterior and

another into the posterior fossæ. Large epidural hemorrhage from rupture of left middle meningeal artery; general hyperæmia with minute coagula and punctate extravasations.

CASE XVIII. *Symptoms.*—Loss of consciousness for thirty minutes, subsequent irritability when disturbed; temperature, 98°; pulse, 78 and intermittent; depressed fracture below right temporal ridge, and hemorrhage from right ear. Second day: depressed bone elevated, and three fissures disclosed—one running backward, one forward, and one downward; dura incised; temperature, 101.8°. Third day: somnolence and irritability, loss of urinary control; temperature, 102°. Fourth day: delirium and progressive rise of temperature to 105.4°. Fifth day: moderate dilatation of pupils, restlessness, hyperæsthesia, increase of surface heat, followed by deep coma. The temperature from this time varied each day from 104°+ in the morning to 105°+ in the evening till death on the eighth day, and was then 106°.

Lesions.—Skull thin. No pus in the wound or in the small brain cavity which had been disclosed by the antemortem operation when the depressed bone was elevated. Subdural hemorrhage in the opposite (left) occipito-parietal region. An effusion of thick green pus beneath the arachnoid membrane covered the lateral and superior surfaces of the right occipital and parietal lobes, but did not extend forward to within an inch of the cranial opening left by operation. A subdural effusion of similar thick green pus was coextensive with the whole right inferior occipital fossa. There was a deep laceration, one inch in diameter, upon the lateral border of the left temporo-sphenoidal lobe, which involved the subcortical tissue. At a point directly beneath the opening left by the removal of the depressed bone there was a cavity in the brain substance as large as a hickory nut, which opened by its whole extent upon the cerebral surface. (As this surface was intact at time of operation, the cavity must be ascribed

to a direct contusion, subcortical, not involving superficial laceration, and to a subsequent giving way of the cerebral cortex under the influence of arterial pulsation, and in the absence of normal repressive force exerted by the skull and dura mater. The whole brain substance and meningeal vessels were intensely hyperæmic, and there were numerous minute extravasations from general contusion. There was no meningeal or ventricular serous effusion. A fissure extended from the central point of fracture through the petrous portion of the temporal and inferior occipital fossa to the foramen magnum.

CASE XIX. *Symptoms.*—Permanent unconsciousness; irritability when disturbed; dilatation of both pupils, especially marked in right; profuse hemorrhage from left ear, which continued for twenty-four hours, and was then followed by serous discharge; general convulsive movements, most pronounced in right leg; temperature, 100°; pulse, 80; single general convulsion, most violent on left side on second day, and repeated on third day; temperature rose steadily to 107.2°. Death in three days and six hours.

Lesions.—Large hæmatoma in substance of left temporal muscle. Fracture extended from left squamous portion into middle fossa, and by an open fissure along anterior border of petrous portion to the sella turcica. Large epidural clot in left middle fossa; large and deep laceration of lateral surface of left temporo-sphenoidal, and of lateral and inferior surfaces of right temporo-sphenoidal lobes; small and deep laceration at right parieto-occipital junction; large cortical clot in left middle fossa; thin cortical coagulum over right cerebrum.

CASE XX. *Symptoms.*—Contusion of left parietal region and of both eyes. Loss of consciousness, and muttering incoherence when disturbed; subconjunctival hemorrhage at outer part of left eye; slight temporary rigidity of right arm; restlessness and irritability; little change till death, in seven days ten hours. Temperature on ad-

mission, 101°; in two days rose to 104.8°; declined from fourth to sixth days to 101°+ to 102°+, and then rose progressively to 107° +.

Lesions.—Skull thin; fracture of left anterior and middle fossæ, apparently beginning with a comminution of orbital plate of left frontal bone about its centre. At this point two or three small fragments were displaced upward, with fine fissures extending in different directions. One fissure ran outward and upward into left squamous portion of the temporal bone; another ran backward from the crista galli through the bodies of the ethmoid and sphenoid bones, through the optic foramen, and along the anterior border of the petrous portion; and the third ran through the right optic foramen into the squamous portion of the right temporal bone. The optic nerves were uninjured. There was a little blood extravasated over right occipital, and lower part of right parietal lobes. The left frontal lobe was completely excavated by a laceration, which was bounded everywhere by a thin layer of unaltered cortex, except inferiorly, near the anterior border, where it was covered in only by the meninges. It was separated from the ventricle by a thin septum of brain substance. This cavity contained commingled blood, clot, and brain detritus. There was also a laceration of the anterior two-thirds of the external lateral border of the right cerebellum, and an extravasation of the size of a robin shot in the centre of the right corpus striatum. There was no clot anywhere at the base of the brain and no other lesions.

CASE XXI. *Symptoms.*—Patient while in an alcoholic condition fell seventeen feet into the hold of a vessel. Thirty minutes later when examined he was unconscious, bleeding from the mouth and nose, and said to have been in the interval violent and abusive. He was three times in the course of the ensuing twelve hours refused surgical aid by ambulance surgeons, who decided that he was suffering from simple alcoholic intoxication. He was then taken to a police court conscious, apparently rational, but

unable to stand or walk, and sentenced to imprisonment for drunkenness. As an afterthought he was sent to the alcoholic ward of Bellevue Hospital, and later transferred to a surgical division. There was then severe contusion of the face and eyes, and a depressed fracture was readily detected in the right frontal region; there was subconjunctival hemorrhage in both eyes, muscular rigidity of both arms, slow pulse, and labored respiration, soon followed by restlessness, muttering delirium, loss of urinary control, and Cheyne-Stokes respiration. Temperature, 104.8° to 106°. Death in twenty-four hours after injury.

Lesions.—Linear fracture of the temporal bone extending three inches upward and backward from its anterior border; stellate fracture with depression above the right supra-orbital ridge, which on the inner surface extended across both orbital plates, through the ethmoid and the body of the sphenoid bone, and on the left side through the middle fossa nearly to the petrous portion; nasal bones comminuted. There was no considerable intracranial hemorrhage; laceration of superior surface of both frontal and both parietal lobes.

CASE XXII. *Symptoms.*—Coma, stertor, full pulse, hemorrhage from the right ear, and pulmonary œdema for which he had been bled from the arm by a ship's surgeon before admission. Death in two hours.

Lesions.—Hæmatoma over the whole right side of the head. Multiple fissures of the base (six in number), involving both sides and all the fossæ. The primary fissure, of five which were connected, began as a wide fissure behind and a little to the left of the foramen magnum, and narrowed to a hair's breadth as it ran forward to the right superciliary ridge. A sixth and entirely independent fissure ran backward from the crista galli on the left side through the optic foramen to the sella turcica. There were slight lacerations of the under surface of both frontal and right temporosphenoidal lobes, which occasioned slight cortical hemorrhage; an epidural hemorrhage upon the upper and lateral

surfaces of the hemispheres, especially the left, and at the base, in the inferior occipital fossæ.

CASE XXIII. *Symptoms.*—Patient found at foot of cellar stairs, unconscious and restless, with a large lacerated scalp wound, which had bled freely, and several wounds of the face. Admitted to the alcoholic ward on the diagnosis of ambulance surgeon of another hospital, still unconscious. The scalp wound was in the parieto-occipital region, to the right of the median line, and the most extensive face wound was over the right malar bone. As he did not "clear up," he was transferred to a surgical ward four days afterward. He was then nearly comatose, quiet unless disturbed; his pupils were normal, and respiration was slow and regular. Temperature, 102.2°; pulse, 96. Temperature next day was 104.6°, 103.6°, and 106°; and on the morning after it was 105° and 107°, when he died without further symptoms, five days and a half after reception of injury.

Lesions.—Fracture at base, through petrous portion of left temporal bone, extending to foramen magnum. Laceration of left temporal and frontal lobes, with cortical hemorrhage.

CASE XXIV. *Symptoms.*—A woman, aged thirty-eight; habitual criminal; jumped from the third tier of the Tombs Prison to the flagging below, thirty feet or more; punctured wound in left occipito-parietal region; unconscious; hemorrhage from left ear; pupils moderately dilated, more especially the left; and vomiting persistent. Temperature, 98.9°. The next morning the patient was conscious, rational, and the hemorrhage had nearly ceased. In the evening she was slightly delirious, and the following day required mechanical restraint till quieted by sedatives. Both pupils became widely dilated, the left still continuing more dilated than the right, and they were only slightly responsive to strong artificial light. This ocular condition continued till her death. The abdomen was painful and swollen. Her mind remained clear but

apathetic till the sixth day, when she fell into a stupor. On the same day all the extremities became paretic and partially anæsthetic. Up to this time the muscular power had been normal. The paresis and anæsthesia were most marked on the right side. The pulse was rapid, quick, and feeble. A day later the left foot and right hand were less paretic, and her mind was clear but the senses were blunted. She answered questions slowly and after an interval, and complained of pain in the head. On the eighth day she was restless and irritable, and had some right facial paralysis, while power in the left foot and right hand was still further improved. On the ninth day she was delirious and unconscious. On the eleventh day she no longer moved or spoke, and paid no attention to an explorative incision. On the fifteenth day she died from asthenia. The temperature remained below 100° till the close of the fourth day, when it rose to 103°. After that it varied from 100° to 102°+; usually was 101°+ till the twelfth day, when it rose to 104° F., and was afterward from 103° to 104.5° till she died.

Lesions.—Head large and unsymmetrical, and skull thick. No lesion of the scalp or of the bone was discovered before removing the calvarium. The occiput was disproportionately large, and the right occipital fossæ were much larger than the left. The left middle and anterior fossæ were rather larger than the right. A fissure began at a point in the squamous portion of the left temporal bone, beneath the external wound, and, passing through the anterior surface of the petrous portion, terminated in the optic foramen. This fissure was not open, but the fragments were quite movable. There was no epidural hemorrhage, but pressure was made upon the facial nerve by interosseous hemorrhage as a result of the fracture. There was no arachnitis and scarcely the usual amount of serum in the meshes of the pia. There were slight lacerations upon the under surface of the right temporo-sphenoidal lobe, and one somewhat larger upon its external border,

orrhage in posterior fossa; small laceration of inferior surface of left prefrontal lobe; thin cortical hemorrhage over superior surface of both frontal lobes. Fracture confined to base.

CASE XXVIII. *Symptoms.*—Wound in right parietal region; temperature, 98.8°; in twenty minutes left lower extremity became paretic. On the fourth day temperature suddenly rose from 99°+ to 102°. On the fifth day, delirium and temperature of 105.2°–106°. Death.

Lesions.—Fracture extending from right squamous portion through both anterior fossæ, involving right greater sphenoid wing and both orbital plates. Laceration of inferior surface of left temporal lobe, and consequent cortical hemorrhage filling left middle fossa.

CASE XXIX. *Symptoms.*—Wound in left inferior temporal region, fracture of left malar bone, and contusions of face. Coma, moist bronchial râles, dilatation of right pupil, left invisible from ecchymosis, anæsthesia followed by paralysis of right upper extremity; temperature, 101.6°. Three hours later, patient apparently moribund. Second day: mental condition normal; motor and sensory functions restored, urinary control lost; pupils normal; temperature, 99°+. Fifth day: temperature had gradually increased to 103° and some subconjunctival hemorrhage had become evident. Sixth and seventh days: mental condition apathetic, and subconjunctival hemorrhage increased; temperature had declined to 100°. Eighth day: sudden loss of consciousness; temperature, 104.8° with decline in two hours to 102.8°, gradual decreasing strength. Death on the ninth day; temperature, 106°, with immediate post-mortem recession.

Lesions.—An open fissure, through both tables of bone, extended from a point just to the left of the occipital tuber to the left foramen lacerum posterius. Moderate subarachnoid serous effusion; subcortical lacerations, which disintegrated and filled with clot the whole interior of both frontal lobes. On the left side the median surface was

ruptured through the arm centre and gyrus fornicatus, and the lateral ventricle was invaded; the clot was very solid and the external layers of fibrin on its inferior aspect were partially decolorized. On the right side the clot was of equal size, but had not broken through the cortex or into the lateral ventricle. There was no cortical hemorrhage, though the posterior border of the left cerebellar lobe was deeply lacerated. The brain substance was softened and reddened in patches of limited contusion.

CASE XXX. *Symptoms.*—Small wound in left posterior parietal region. Permanent unconsciousness; slight hemorrhage from both nostrils; left pupil dilated, right pupil contracted; loss of fæcal and urinary control; face flushed. Temperature, 101°, and on the second day 101°+; then rose progressively to 106.8° at death, in three and one-half days, with post-mortem increase to 109°. On the last day general sensation obviously diminished.

Lesions.—Fine fissure extended from left of occipital protuberance through posterior fossa and petrous portion to foramen ovale. Laceration excavating inferior surface of right frontal, and extending into right temporal lobe; laceration of middle portion of left gyrus fornicatus, one-half inch in diameter; wide and deep laceration across inferior surface of left cerebellar lobe. The laceration of the gyrus fornicatus involved the cortex. Cortical hemorrhages; clot, three fluid ounces by measurement, in anterior fossæ; hemorrhage slight in right posterior fossa, and in moderate amount over lateral surface of right frontal lobe; all resulted from these several lacerations. General contusion of both hemispheres, most marked posteriorly.

CASE XXXI. *Symptoms.*—Brief unconsciousness, which recurred in the ambulance; in the interval no evidence of serious injury. On admission to the hospital, pupils contracted, sudden cyanosis, and death in twenty-five minutes.

Lesions.—Hæmatoma in left occipital region; blood still

fluid. Stellate fracture, with centre in left upper occipital region, and with fissures running downward into foramen magnum, forward and downward into middle fossa, and upward and laterally. Epidural clot in left occipital region; pial hemorrhage in inferior occipital fossæ over pons and medulla; and cortical hemorrhage over both frontal and both temporal lobes from laceration of their inferior surfaces.

CASE XXXII. *Symptoms.*—Patient injured by the fall of a brick from the fourth story of a building; admitted to

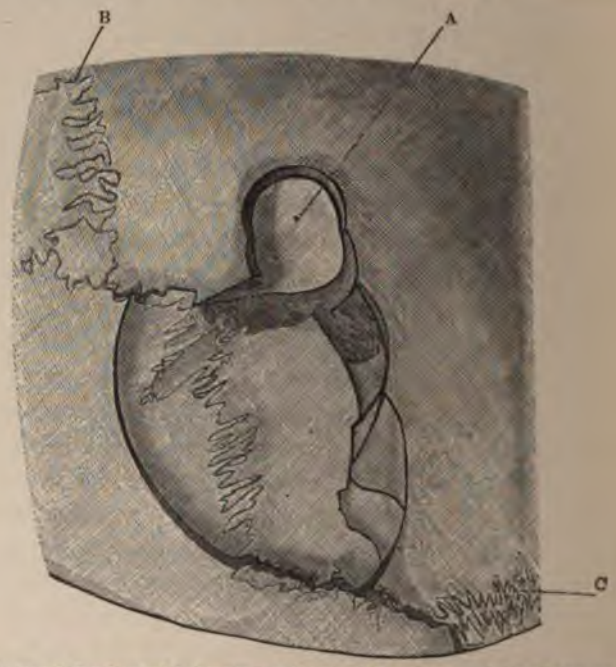

FIG. 42.—External Surface of Calvarium at Point of Fracture. *A*, Trephine opening; *B*, portion of lambdoid suture; *C*, masto-parietal suture.

the hospital on the second day; mind clear; hemorrhage from the right ear; compound comminuted, depressed, fracture in the right supramastoid region; trephination and elevation of bone; dura mater uninjured; primary union of wound, and cicatrization of drainage exit without

formation of pus. Hemorrhage from ear ceased, and during first week no general symptoms; temperature falling from 100.4° to normal. On the eighth day, temperature rose to 101.4°, and an enlarged and painful lymphatic gland was discovered in right posterior cervical triangle. On the seventeenth day, no symptoms, general or local; temperature normal. On the twentieth

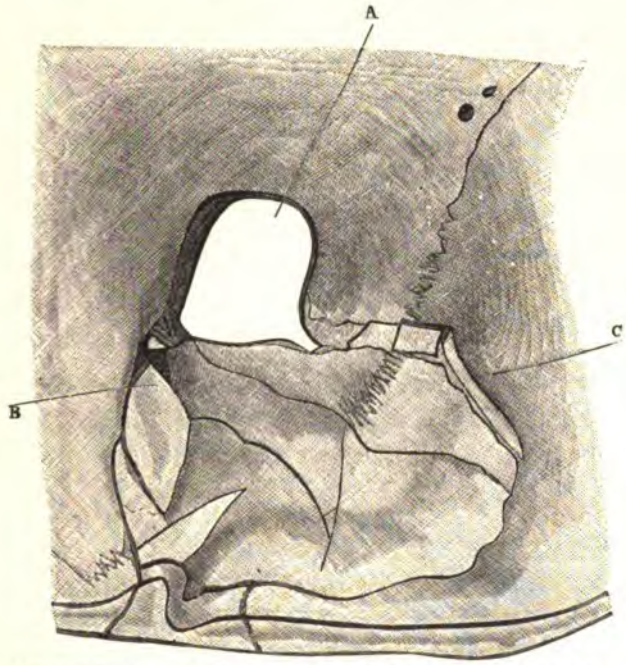

FIG. 43.—Internal Surface of Calvarium at Point of Fracture. *A*, Trephine opening; *B*, *C*, portions of internal table slightly depressed.

day, some malaise and headache, the apparent result of a surreptitious bottle of red wine. On the twenty-third day, severe frontal headache, delirium, somnolence, and left hemiplegia. On the twenty-fourth day, complete left hemiplegia and hemianæsthesia, continued somnolence, and sluggish movement of the pupils; left eye injected; temperature, 98.5°; pulse, 66; cicatrix uninflamed. On the twenty-fifth day, increasing stupor and loss of fæcal and

urinary control; temperature, 100.2°. The wound was then reopened, and the dura, which was pulsating, was incised; the cerebral surface was of normal consistence and had been uninjured. A subcortical abscess was discovered by exploration at the first insertion of the probe, from which one to two drachms of reddish pus and disintegrated brain tissue were evacuated. During the oper-

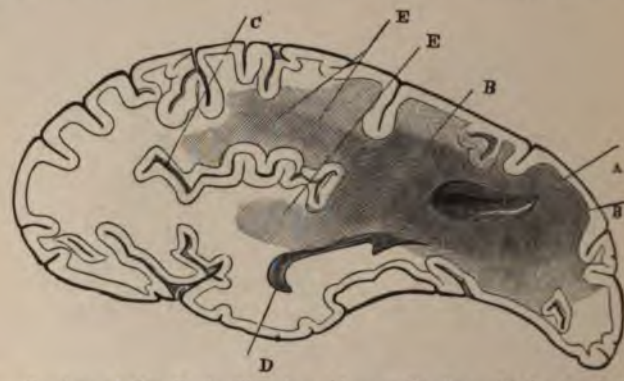

FIG. 44.—Section of the Brain Showing Abscess Cavity and Area of Softening. *A*, Abscess cavity; *B*, area of softening gradually disappearing at *E*; *C*, section of convulution of central lobe (island of Reil); *D*, section of lateral ventricle.

ation respiration failed, and was restored only by tracheotomy; reaction was complete. Temperature rose to 108°, and death occurred sixteen hours later.

Lesions.—The fracture involved the right parietal and occipital bones; the disc which had been elevated was two inches by one and one-half inches in its principal diameters, included the outer half of the lambdoid suture, and was continuous with a fissure which was prolonged through the whole anterior surface of the petrous portion. There was no intracranial hemorrhage, no subarachnoid effusion or arachnoid opacity, and no superficial contusion or laceration. The dura mater and pia mater were adherent to each other over a small area in the posterior and inferior part of the parietal lobe on the right side corresponding in situation to the site of fracture. In this area the meshes of the pia mater were infiltrated with blood, and beneath it

was an area of softening which extended forward for about two and one-fourth inches. The brain was hardened in alcohol, and an oblique longitudinal section then made in a plane passing downward and inward, which intersected the abscess cavity; this was found to communicate, through a canal made by the passage of the probe during life, with the surface at the point where the adhesions between the membranes were firmest. At this point the abscess cavity was most superficial, but was at least three-eighths of an inch distant from the surface. The abscess had a well-defined wall, and broadened as it extended forward and inward toward the median line for a distance of about seven-eighths of an inch. It was surrounded by a wide area of softening, which in the part lying between it and the surface at the site of the meningeal adhesions was slightly hemorrhagic and seemed to date from an earlier period than elsewhere. In front of the abscess cavity the softening extended above and below the convolutions of the island of Reil, and cut the motor and sensory fibres both before and after their passage through the internal capsule.

CASE XXXIII. *Symptoms.*—Unconsciousness, which continued till death; hemorrhage from left ear; dilatation of both pupils, and subsequent contraction of right; muscular relaxation, followed by later rigidity; temperature on admission, 99.6°; afterward, 99.6° to 100.4°; one hour post mortem, 101.2°. Death in twelve hours.

Lesions.—Wound in left posterior parietal region. Semicircular fracture of squamous portion of left temporal bone, with fissure extending into anterior surface of petrous portion; deep, well-defined laceration, laterally and posteriorly, of left temporo-sphenoidal lobe, from which a thick clot extended over occipital region; brain in all its parts excessively hyperæmic; on section, the surface was repeatedly bathed in blood as it was each time wiped away; no punctate extravasation or coagula in minute vessels.

CASE XXXIV. *Symptoms.*—Coma; stertor; loss of urinary control; hemorrhage from nose and later hæmatemesis; pulse, 96 and full; respiration, 18; temperature, 100°, rising gradually to 102.6° some time before death, in fourteen hours after admission to the hospital.

Lesions.—Small epidural hemorrhage at site of fracture; rupture of dura mater; corresponding laceration in anterior inferior parietal region; laceration of anterior half of right middle temporal convolution; small laceration in centre of left cerebellum filled with fluid blood; general hyperæmia, most marked on left side posteriorly. Wound in right occipito-parietal region, and linear fracture in right parietal bone extending through greater wing of sphenoid bone into middle fossa.

CASE XXXV. *Symptoms.*—Unconsciousness; contraction of both pupils; rigidity of both lower and of right upper extremities; pulse and respiration too rapid to be counted; temperature, 101°, and *in articulo mortis* 100.4°. Death in two hours. Temperature two hours post mortem, 99°+.

Lesions.—Extravasation of blood over whole left parietal region, not evident during life; separation of left coronal suture beginning in its middle portion, with a continuous fissure, which in left middle fossa bifurcated and terminated in greater wing of the sphenoid and at petro-mastoid junction. No epidural hemorrhage, and no superficial laceration. Pial hemorrhage over left frontal and parietal lobes upon their superior and lateral surfaces, and about the region of right occipito-parietal junction; small central laceration of left corpus striatum at junction of middle and posterior thirds; excessive general hyperæmia.

CASE XXXVI. *Symptoms.*—Coma; stertor; alcoholic condition; no superficial injury; muscular relaxation; face flushed; pupils slightly contracted; vomiting; temperature, 97°, continuing subnormal; pulse, 60; respira-

tion, 16; one general convulsion just before death, at the end of eight hours and a half.

Lesions.—Fracture through left occipital, parietal, and squamous portion of temporal bone to margin of petrous portion; laceration of inferior surface of right frontal lobe and of both temporo-sphenoidal lobes; pial hemorrhage over whole right parietal region.

CASE XXXVII. *Symptoms.*—Patient in alcoholic condition at the time of injury. Primary and permanent unconsciousness; stertor; left radial pulsations fuller and stronger than right; compound linear fracture in left parietal region, through which blood oozed in large amount at each cardiac contraction. On admission to hospital, temperature, 98°; pulse, 100; respiration, 32. One and one-half hours later, temperature, 96°; pulse, 110; respiration, 40. Death in three hours.

Lesions.—Fracture extending from left parietal eminence into left middle fossa, and terminating just behind foramen spinosum; epidural hemorrhage along the course of the fracture; small pial hemorrhage over left hemisphere; general cerebral hyperæmia. The epidural hemorrhage was derived from the posterior branch of the middle meningeal artery and the blood in great part escaped through the external wound during life.

CASE XXXVIII. *Symptoms.*—The patient, after having passed through three hospitals, with three discharges and two transfers, and after having wandered about the streets and suffered much exposure, was finally received and allowed to remain in an asylum for the insane on the eighth day after a fall from the stoop of her house. She had then delusions and other symptoms of mental derangement, left facial paralysis, left subconjunctival hemorrhage, and hemorrhage from both ears. She died on the twenty-fourth day from the reception of the injury.

Lesions.—Transverse fracture of the base, extending through both petrous portions and left orbital plate; laceration of inferior surface of left frontal lobe; small sub-

cortical laceration of left parietal lobe; cortical hemorrhage at base and over external surface of both hemispheres; general contusion.

CASE XXXIX. *Symptoms.*—Profound coma, which continued till death; stertor; pulse, 70, full and strong; temperature, 99.4°. Death in seven hours.

Lesions.—Linear fracture through right side of occipital bone to jugular foramen; pial hemorrhage over both occipital lobes and posterior portion of left parietal lobe; excessive general hyperæmia.

CASE XL. *Symptoms.*—Contusion of left parietal region; primary unconsciousness; epistaxis; delirium, which continued till admission to hospital two days later; unconsciousness at that time; pupils normal; pulse rapid and weak; respiration, 21; temperature, 101.4°, rising to 102°+; consciousness not restored. Death in four days.

Lesions.—Linear fracture of occipital bone from tuber to right jugular foramen; also fissure of left orbital plate; thrombosis of lateral sinuses; clot firm, but not decolorized; general cerebral hyperæmia, with a few minute coagula.

CASE XLI. *Symptoms.*—Unconsciousness succeeding an injury received on the preceding day; admission to hospital after twenty-four hours; right pupil slightly dilated; temperature, 99.8°; pulse, 96; respiration, 24; temperature rose to 100.2°. Death in about thirty hours from time of injury.

Lesions.—Linear fracture running nearly transversely through left parietal bone into right coronal suture; also V-shaped indirect fracture in right middle fossa; epidural hemorrhage over right frontal lobe from vertex to base; laceration of middle two-fourths of second right temporal convolution, with cortical hemorrhage extending over parietal lobe; general hyperæmia with minute coagula in all parts of the brain.

CASE XLII. *Symptoms.*—Shock; consciousness retained; temperature, 96°; pulse, 78; respiration, 21; sud-

den cyanosis, with extreme dyspnœa, and loss of consciousness, which lasted for only three or four minutes, followed by numbness of both arms; no further dyspnœa; delirium fourteen hours later, and death four hours later still, preceded by a single convulsive movement and without respiratory disturbance.

Lesions.—Occipital contusion and wound behind right ear; bifurcated linear fracture in right inferior occipital fossa; pial hemorrhage beneath tentorium, extending around lateral borders of cerebellum and covering the pons; moderate general hyperæmia.

CASE XLIII. *Symptoms.*—Scalp wounds in left parietal, and large hæmatoma in right parietal region; compound linear left parietal fracture; no known loss of consciousness; shock; dilatation of both pupils; pulse feeble; respiration shallow; temperature after four hours, 96.4°. Death in nine hours and a half.

Lesions.—Parietal fissure extended nearly across greater wing of sphenoid; considerable subarachnoid serous effusion; general hyperæmia and thrombosis of minute vessels, most marked posteriorly.

CASE XLIV. *Symptoms.*—Unconsciousness till death; pupils normal; muscular twitchings over whole right side of body; temperature on admission, 98°; in six hours, 103.6°; in seven hours, 104.4°; in nine hours, 106.6°; pulse, 80 to 145; respiration, 15 to 34. Death in nine hours and a half.

Lesions.—Calvarium crushed; large wound in the skull at the vertex involving the median line, two by three inches in its diameters; on the left side the osseous fragments rested upon the dura mater, on the right they deeply penetrated the brain; a fissure extended into the right orbital plate; epidural clot on the left side, in which the parietal fragments were embedded; on the right side, disintegrated brain tissue, bone, and membranes were commingled; anterior part of both lateral ventricles contained blood; cortical hemorrhage extended beneath the tentorium; general

hyperæmia and vessels even of the larger size filled with thrombi.

CASE XLV. *Symptoms.*—Scalp wound in left frontal region; left pupil dilated; consciousness only partially lost; temperature on admission, 98°; fell in four hours to 97.6°; pulse, 90; respiration, 24. Death in four hours and a half.

Lesions.—Slight depression at left external angular process of frontal bone, and fissure extending thence through both orbital plates and intervening ethmoid body; deep laceration of frontal lobes on either side of inferior median fissure; smaller laceration of posterior border of cerebellum, near median line, from which a cortical hemorrhage extended over both its superior and inferior surfaces; general hyperæmia and minute coagula.

CASE XLVI. *Symptoms.*—Hæmatoma over whole vertex, and small wound of scalp; unconsciousness, which continued till death; dilatation of left pupil; general convulsions, beginning in hands, with marked opisthotonos; temperature six hours after reception of injury, 98.6°; pulse, 84; respiration, 28; extent of fracture determined by incision. Death in nine hours.

Lesions.—Disjunction of coronal suture, multiple fissure of frontal bone, and fissure through right parietal and occipital bones, with branch into posterior fossa; laceration of right frontal, parietal, and occipital lobes, and wound of dura mater permitting escape of brain tissue through osseous parietal opening.

CASE XLVII. *Symptoms.*—Contusions of left side of head and face, and tactile evidence of simple fractures; unconsciousness, which continued till death; epistaxis and hæmatemesis; temperature on admission, 99°; pulse, 96; two hours later, temperature, 96.4°; pulse, 140; respiration, 53; five hours later, temperature, 95.6°; pulse and respiration as before. Second day, deglutition became possible and sensitiveness to external impressions was regained; pupils slightly dilated; temperature, 103° to 103.6°; pulse,

168 to 196; respiration, 48 to 58. Death in thirty-four hours. (In this, the case of a child four years and a half of age, the brain weighed forty-eight ounces, and was in all respects symmetrical; the skull was of normal thickness.)

Lesions.—Separation of the coronal and of the bifrontal suture to nasal bones, which were fractured; fracture continuous into ethmoid body, with complete detachment of the crista galli and cribriform plate; fissure of right parietal bone and depressed fracture of left frontal above orbital ridge; slight epidural hemorrhage over vertex; laceration of frontal lobes in the space corresponding to the site of cribriform plate; general hyperæmia with minute coagula, most marked in cerebellum and occipital lobes.

CASE XLVIII. *Symptoms.*—None discovered, and admission to hospital refused two days after a fall in the street; found dead two hours later a block away; wound over left eye.

Lesions.—Pneumonia involving lower lobe of right lung, and large flabby heart; fracture extending through left supra-orbital ridge and orbital plate into greater wing of sphenoid bone; general hyperæmia and thrombosis.

CASE XLIX. *Symptoms.*—Large hæmatoma over right eye; profuse hemorrhage from mouth, nose, and right ear; unconsciousness; rapid and feeble pulse and respiration; dilatation of both pupils, especially the left. Death in fifteen minutes. (Cæsarean section at six months and a half; child lived forty-five minutes.)

Lesions.—Separation of right sutura additamentum lambdoidalis and fissure continued, through petrous portion and middle fossa, into body of sphenoid bone; large pial hemorrhage over left parieto-occipital region.

CASE L. *Symptoms.*—Wound over left eye and at occiput; shock; unconsciousness; hemorrhage from ears, nose, and mouth; restlessness, and utterance of short, sharp cries; pulse frequent, weak, and symmetrical; respiration slow, irregular, and sighing; right pupil dilated, and

left invisible from ecchymosis; twitching of right side of face, followed by general convulsions, preceded death at end of twelve hours.

Lesions, discovered by incisions: In left temporal region fissures ran into temporal fossa, and squamous suture was partially disrupted; in occipital region open fissure ran into right petrous portion and lambdoid suture was separated; arachnoid hemorrhage in right occipito-parietal region.

CASE LI. *Symptoms.* — Scalp wounds in parietal regions; mobility and crepitation of calvarium; shock; unconsciousness, which continued till death; slight epistaxis and profuse hæmatemesis; both pupils dilated, and after three hours and a half the right more so than the left; one radial pulse fuller and stronger than the other; temperature on admission, 101°; in one hour, 102°; in two hours, 106°; in four hours, 106.8°; pulse, 70, 110, 160, 170; respiration in two hours, 48. Death in four hours and a half.

Lesions.—Fissure, beginning just above left internal angular process, running across middle of parietal bones, and nearly circumscribing calvarium; another detached its posterior portion, and others still extended from primary line of fracture to base; arachnoid hemorrhage on left side; further examination refused.

CASE LII. *Symptoms.*—Contusion in left frontal region and ecchymosis of left eye; consciousness retained; hemorrhage from right ear and from nose and mouth; delirium, becoming violent later in the day and during the night. On the second day, the patient formed a fixed delusion that he had fallen from a mulberry tree. He described with circumstantiality all the details of his imaginary accident. He had no recollection of the manner in which his injury had really occurred, and would give no credence to facts as they were presented to him; he had other and transitory delusions, but this one remained unalterable. Both pupils were moderately and symmetrically

dilated. His mind became remarkably alert, and his conversation was logical and coherent. Nine days later hemorrhage from the right ear recurred; subconjunctival hemorrhage, which had been previously noted, increased, and the left eye became prominent. Mechanical restraint was still necessary to keep him in bed. On the twelfth day, hemorrhage from the ear ceased, and subconjunctival hemorrhage diminished; a scarcely perceptible facial paralysis existed. His mind seemed clearer; he could recollect the street and neighborhood in which he lived, but not the number of his house; only the one delusion persisted. Later, a frontal headache from which he had constantly suffered became less urgent; but his general condition was not materially changed till two days before his death, when he became progressively asthenic from an intercurrent diarrhœa. His mind remained clear with occasional transient delusions, his conversation coherent, and his belief in the mulberry tree unshaken to the last. Temperature on admission was 98.6°; one hour later, 100°; and five hours later, 104.7°; for the two days following it was 103° to 103.8°; and during the fourth and fifth days, 101° to 99°+; it varied till the twentieth day from 99.8° to 101.8°, only twice exceeding 100°. The pulse on admission was 85, and the respiration 20, with no considerable subsequent changes till near the close of life. Thirty-six hours ante mortem temperature rose to 102.4°, and twelve hours later to 105°; in another twelve hours it declined to 97.5°, and immediately before death rose again to 100°, with pulse of 140, and respiration of 42. Death on the twenty-fourth day.

Lesions. — Depressed fracture above left supra-orbital ridge, with fissure extending across both orbital plates and intervening cribriform plate, through right middle fossa, external to greater wing of sphenoid, through outer part of petrous portion of temporal into posterior fossa, and returning upon itself across petrous portion and through body of sphenoid and ethmoid finally to terminate in itself

anteriorly. A second fissure crossed left orbital plate into left middle fossa. Small epidural hemorrhage beneath depressed part of fracture; laceration of under surface of both frontal lobes, mainly subcortical, crossing median line obliquely from centre of left lobe to line of right anterior cerebral artery. This laceration was one inch and one fourth wide by one inch in depth at its commencement on the left side, and on the right side was five-eighths of an inch in width by half an inch in depth. In removing the brain the arachnoid was torn and the diffluent contents of the cavity escaped; its margin and the overhanging cortical tissue were dark and sloughy; its deeper portion was yellow and ragged; it was separated anteriorly on the left side from the median fissure by a single convolution. There were general hyperæmia and minute thromboses, most marked posteriorly.

CASE LIII. *Symptoms.*—Hæmatoma in left parietal region; coma; stertor; no response to external irritation; pupils widely dilated; pulse full, slow, and strong; temperature on admission, 99°, and rose steadily to 107.8°; respiration, 32, 46, 14; pulse, 62, 70, 126. Death in four hours and three-quarters.

Lesions.—Coronal suture separated and fracture continued into anterior part of middle fossa on both sides; general hyperæmia with well-marked but not excessive œdema, and some punctate extravasations.

CASE LIV. *Symptoms.*—Consciousness lost, but partially restored on arrival of ambulance; large hæmatoma in right posterior occipital region; slight epistaxis; pupils moderately contracted; respiration shallow; right radial pulse after two hours more frequent than the left—84 and 74, 114 and 110; temperature on admission, 96°; in two hours, 95°; in six hours normal, rising to 100.4° before death in nine hours.

Lesions.—Separation of coronal suture on left side and fracture continued through middle fossa, sella turcica, right middle fossa, right petrous portion, and posterior

fossa, to foramen magnum; large epidural clot in left temporal region; slight cerebral œdema; old meningeal adhesions, and small white nodules in the pia mater.

CASE LV. *Symptoms.*—Consciousness retained for fifteen minutes after admission; then delirious four hours; afterward consciousness lost; contusion of right side of head; hemorrhage from left ear and nose, and hæmatemesis; slight dilatation of right pupil; temperature on admission, 101°, rising to 103°; pulse, 90 to 108; respiration, 22, 24. Death in ten hours.

Lesions.—Linear fracture extended from right squamous portion through body of sphenoid and both middle fossæ into left petrous portion; a second fissure extended from sphenoid into cribriform plate; large epidural clot in left middle fossa; marked general hyperæmia.

CASE LVI. *Symptoms.*—Delirium, which continued till final unconsciousness at close of life; wound in left temporal region; hemorrhage from right ear; second day, paralysis of left arm; fourth day, loss of control of urine and fæces; death in three days and eight hours. Temperature on admission, 99° +; rose to 103.2°, declined to 101°, and rose to 106.6° shortly before death; pulse, 90 to 114; respiration, 18 to 28.

Lesions.—Linear fracture extending from outer part of right petrous portion, through body of sphenoid bone into its left lesser wing; epidural hemorrhage in left middle fossa; large pial hemorrhage over right temporal and parietal lobes, especially profuse near the vertex; general hyperæmia with minute coagula; thrombus in each lateral sinus.

CASE LVII. *Symptoms.*—Consciousness lost, partially recovered after admission; articulation imperfect; alcoholic condition; small wound in right occipital region; active delirium a few hours later; alternations of delirium and stupor till death, sixteen days afterward; temperature, pulse, and respiration normal from second to fourth day; temperature varied from 99.4° to 104.8°, and was 103° at

time of last observation; pulse, 112 to 144; respiration, 26 to 44.

Lesions.—Fracture extending from right of foramen magnum, three inches and a half, into left inferior occipital fossa; laceration of inferior surface of both frontal and left temporo-sphenoidal lobes; pial hemorrhage over right occipital lobe; general subarachnoid serous effusion.

CASE LVIII. *Symptoms.*—Coma, which lasted for a few hours; wound in occipital region; no general symptoms noted till seventh day, when sudden recurrence of coma was followed by death. Temperature second, third, and fourth days, 100.4° to 99.4°; after second coma, 104;° pulse and respiration normal.

Lesions.—Fracture through right middle fossa, involving petrous portion; laceration of inferior surface of right frontal and temporo-sphenoidal lobes; cortical hemorrhage over almost entire surface of right cerebrum; clot in substance of right centrum ovale.

CASE LIX. *Symptoms.*—Momentary unconsciousness; contusion of left eye and wound of left frontal region; epistaxis without perceptible injury of the nose; second day, delirium at intervals, becoming constant through the night; third day, somnolence, restlessness, and delirium characterized by delusions; at close of the fourth day delirium became muttering and respiration stertorous. Death in four days and a half. Temperature on admission, 99.8°; on the second day, 104.8°, 102°, 100°, 103°, 101.8°; on the third day, 103.6°, 103.4°; on the fourth day, 103°+, 106.6°; on the fifth day, 107°, 108.2°. Pulse till end of fourth day, 82, 56, 90, 106; respiration, 19, 34, 24, 40.

Lesions.—Fracture beginning at left external angular process of frontal bone, comminuting orbital plate, extending into body of sphenoid, and, after bifurcation, terminating in cribriform plate and in squamous portion of right temporal bone; two lacerations of inferior surface of left frontal lobe—one near its centre as large as a hickory nut, containing disintegrated clot and brain tissue, the

other smaller and more superficial, encroaching upon middle portion of Sylvian fissure; two other slight lacerations upon inner border of right occipital lobe; slight subarachnoid serous effusion upon upper surface of cerebellum; general hyperæmia with some minute coagula.

CASE LX. *Symptoms.* — Consciousness not lost, but delirium continued from time of injury till final coma; contusion behind left ear; very slight dilatation of pupils; delirium became violent. At the end of two or three hours the patient became aphasic; he could utter single words correctly, or a number of words in succession, each correct in itself, but strung together without sense or logical sequence, as "water — father—when," or "Jesus — now—who." He also connected fragments of words with each other, as "en—is—other," meaning when is mother; or "J—mother," for Jesus, mother; or "J—ter," for Jesus, water; sometimes "ter—J," for water, Jesus. The clew to these fragmentary words and sentences was found in the words he constantly used singly. The aberrations of speech, like the delirium, continued till final coma, and were constant. On the second day his head was extended, but without cervical rigidity; he was restless and irritable; the pupils were still normal; urine was retained; coma and stertor supervened, and death occurred thirty-seven hours and a half after admission. The temperature on admission was 100.2°, rose progressively in twenty hours to 105.2°, remained stationary for twelve hours, and again rose progressively to 108.6°. One hour post mortem it was 110°. The pulse constantly increased in frequency from 90 to 190. The respiration did not exceed 24 for thirty-two hours, after which it was from 40 to 50.

Lesions. — Fracture extending from left superior occipital fossa, through posterior condyloid foramen, into foramen magnum; epidural hemorrhage, slight over occipital lobes and more abundant in inferior occipital fossæ; cortical hemorrhage in central part of anterior fossæ and over sella turcica; thrombi in left lateral

and superior petrosal sinuses; posterior meningeal veins, including those of larger size, greatly distended; some opacity of arachnoid membrane and subarachnoid serous effusion over right occipital lobe. Lacerations confined to base, except in case of left temporo-sphenoidal lobe. The first left temporal convolution was lacerated through the whole thickness of its cortex for a length of one inch and a half, which included the second and part of its third fifths, estimated from its anterior extremity, and its middle portion involved the second convolution. This laceration was limited to the exact width of the two convolutions and was covered by the unruptured arachnoid. A small and deep laceration existed upon the inferior surface of this lobe, and another, small and shallower, was situated at its tip, involving all three of its convolutions. A similar slight laceration occurred at the anterior extremity of the right temporo-sphenoidal lobe, including the second and third convolutions. There was an extensive laceration of the under surface of the left frontal lobe, extending from its anterior border to the optic chiasm and from the median line outward through the first and second into the third orbital convolution; it disintegrated the cortex and the subcortex to a considerable depth, and the resultant hemorrhage had broken through into the arachnoid cavity. There was, finally, a small contusion about the centre of the inferior surface of the right frontal lobe. The brain substance was generally hyperæmic with minute thromboses, and a small amount of reddish serum occupied the lateral ventricles.

CASE LXI. *Symptoms.*—No evidence of brain lesion on admission, twenty-four hours after injury, except right radial pulsation was fuller and stronger than the left; followed by delirium, with delusions, after sixteen hours, which, with the unsymmetrical pulse, persisted for five days. On the sixth day, mind clear, memory restored, general headache; later, delirium at intervals, aimless inclination to get out of bed, increasing difficulty of articu-

lation, progressive mental impairment; control of bladder and rectum lost. On the twenty-fifth day, patient quiet, weaker, picking at the bedclothes. Twenty-sixth and twenty-seventh days, delirium, irritability, great sensitiveness to external disturbances, unconsciousness. Death occurred on the twenty-eighth day. Temperature on admission, 102°; second and third days, 103°, 104.4°; from this time it was usually 99° to 99° +, sometimes normal, occasionally 100°, until the last eighteen hours, when it suddenly rose to 105°, and, with slight recessions, finally reached 108°. Pulse, 84 to 54, till the last four days, when it exceeded 100; but in the last twelve hours, with the highest temperature, it ranged from 70 to 54. Respiration was accelerated on the second and third days, but at other times was normal till within a few hours of death. Right axillary temperature the day before death was from 0.2° to 1.2° higher than the left. Temperature one hour post mortem, 108°.

Lesions.—An open fissure extended from beneath the torcular Herophili, downward and slightly outward, to a point near the left margin of the foramen magnum, where it subdivided to enclose a quadrangular depression of bone three-quarters of an inch by half an inch in its diameters; it was then continued between the posterior border of the petrous portion and the basilar process of the occipital bone, where it terminated. No external evidences of injury; small epidural hemorrhage on either side of median line at commencement of fracture; two thin laminar spots of epidural clot, each about half an inch in diameter, firmly attached to dura over anterior part of left frontal lobe, from indirect violence; corresponding blood stains upon surface of bone, but under surface of dura not discolored; large subarachnoid serous effusion over vertex; meningeal hyperæmia, but none of cerebral surface. Four lacerations of antero-superior surface of left prefrontal lobe, with contusion of intermediate cortex, the whole covering a space one inch and a half in diameter;

another laceration of small size a short distance behind them; small laceration upon anterior part of external surface of right frontal lobe; these lacerations all extended into the subcortical substance and were partially filled with necrotic tissue; the adjacent brain substance was unaltered. Marked general œdema and hyperæmia, with moderate number of punctate extravasations and minute thrombi; brain of normal consistence.

Immediate microscopic examination afforded no evidence of inflammatory action, except in contiguity to the necrotic tissue. The quadrangular osseous depression was firmly fixed, but there was no osseous deposit.

CASE LXII. *Symptoms.*—No history; walking case; semiconsciousness, but without speech or comprehension of speech then or afterward; hemorrhage from left ear, and œdema of left mastoid region; pupils normal; early delirium; sensitiveness to external irritation; retention of urine. Second day, entire unconsciousness; convulsive movements of limbs; Cheyne-Stokes respiration; accumulation of mucus in trachea and bronchi, and death in forty-two hours. Temperature on admission, 101.6°; in twenty-four hours, 103.2°; in twenty-seven hours and till death, 108.6°; one hour post mortem, 108°. Pulse, 64 to 50; second day, 140 to 168. Respiration, normal, 24, 16, 20.

Lesions.—Hæmatoma in left occipital region; linear fracture through left occipital bone, from median line and along groove for lateral sinus, across petrous portion by a wide fissure, and separating dorsum ephippii from sphenoid bone; thrombus in left lateral sinus; complete disintegration of right frontal lobe to within half an inch of fissure of Sylvius and quite to anterior border of corpus striatum; deep laceration of greater part of inferior surface of left temporo-sphenoidal and a smaller laceration in centre of inferior surface of right temporo-sphenoidal lobe; cortical hemorrhage from the frontal laceration filled all the

basic fossæ except the outer part of the left anterior, and one clot in the median line anteriorly was as large as a mandarin orange; it also covered with a thin coagulum the superior and lateral surfaces of the whole right and the greater part of the left hemispheres, and extended over the superior surface of the cerebellum; general hyperæmia, with a few minute thrombi; minute extavasations in centre of pons, the largest of which was of about the size of a robin shot.

CASE LXIII. *Symptoms.*—Primary unconsciousness, followed by mental hebetude and mild delirium, which continued till death; occasional dysphagia in second week, sometimes extreme. Temperature on admission, 99.2°, rose in two hours to 102°, and was afterward 99° to 100° and 101°. Pulse on admission, 50; below 90 for eight days; afterward exceeded 100. Respiration normal. Death occurred in fourteen days, and was immediately preceded by extreme dyspnœa and dysphagia.

Lesions.—Fracture through left occipital, from median line to petrous portion of temporal bone; extensive laceration of antero-superior and inferior surfaces of left frontal lobe; cortical hemorrhage covered with a thin clot the entire left hemisphere and the posterior half of the right, and filled all the basic fossæ.

CASE LXIV. *Symptoms.*—Contusion in occipital region, and recurrent hemorrhage from left ear; violent delirium after thirty-six hours; right radial pulse fuller and stronger than the left on the third and fourth days. Temperature on admission, 98.4°, rose in twelve hours to 102°, and afterward varied from 98.5° to 100° + in the morning, and from 99.5° to 100.8° in the evening; last observation, six hours ante mortem, 101.6°. Pulse and respiration were practically normal. Death in ten days.

Lesions.—Fracture through posterior part of left parietal, into petrous portion of temporal bone; transverse laceration across inferior surface of right frontal lobe at junc-

tion of its anterior and middle thirds, which was subcortical except at outer extremity, where hemorrhage had broken through the surface; small laceration of anterior fourth of second right temporal convolution, mainly subcortical; cortical hemorrhage in right middle and posterior fossæ, and to a small amount in right anterior fossa; moderate general hyperæmia, with a few minute coagula.

CASE LXV. *Symptoms.*—Consciousness lost and partially restored; persistent occipital pain; admission to hospital four days later; stupor merging in final unconsciousness; loss of control of bladder and rectum; right radial pulse fuller and stronger than the left, but difference not strongly marked; pupils normal. Temperature on admission 100°; normal, with exception of eight hours on the seventh day, when it was from 99.2° to 99.4°, till ten hours ante mortem; final temperatures, 99.2° to 103.8°; pulse, 45 to 80; respiration, 14 to 18. Death in ten days.

Lesions.—Hæmatoma in left occipital region; biparietal and left parieto-occipital sutures loosened but not separated; small laceration on under surface of right frontal lobe anteriorly; cortical hemorrhage covered the whole lateral and superior surfaces of both hemispheres, except in left lower parietal region, extended into median fissure and beneath tentorium over superior surface of cerebellum, and occupied both anterior and both middle fossæ. The effusion was thin, except at the base and over the frontal lobes, where the clot was thick, firm, black, and closely adherent to the cortex, and could be traced into the frontal laceration from which it originated. A still smaller laceration existed upon the inferior surface of the right temporosphenoidal lobe. The brain was moderately hyperæmic and very œdematous in its cerebral portion. There were no punctate extravasations, few minute thrombi, and no inflammatory products.

CASE LXVI. *Symptoms.*—Complete unconsciousness, which continued till death; hemorrhage from nose and mouth; pupils contracted and immovable, but in a few

hours left became dilated; some convulsive movements of right arm; retention of urine; second day, ecchymosis of both eyes and subconjunctival hemorrhage in right; continued dilatation of left pupil; right normal. Temperature on admission 101°; in four hours, 102°; in sixteen hours, 105°, and in twenty-four hours, 106°; pulse and respiration frequent throughout. Death in twenty-six hours.

Lesions.—Extravasation of blood into substance of left temporal muscle disclosed by incision; open fissure extended from squamous portion of right temporal bone across both orbital plates and intervening cribriform plate of ethmoid, broke off left lesser wing of sphenoid, crossed left middle fossa and petrous portion, and terminated in left margin of foramen magnum; epidural clot occupied the whole right anterior fossa, and another of smaller size the left middle fossa; a thrombus filled the posterior part of the superior longitudinal sinus; cortical hemorrhage over superior surface of the cerebellum, derived from a small laceration of its lateral border; small pial hemorrhages over left parietal and temporo-sphenoidal lobes, and a larger one over right parietal lobe; large subcortical laceration of left temporo-sphenoidal lobe, excavating its substance beneath second and third convolutions and anterior portion of the first convolution, which did not reach the surface; moderate general hyperæmia, more marked in pons and cerebellum.

CASE LXVII. *Symptoms.*—Patient walked two miles to the hospital gate and was carried unconscious to the ward; ecchymosis of right eye and wide dilatation of right pupil; slight contraction of the left; no motor or sensory disturbances; left brachial pulsation full and strong, the right very small and weak; same conditions existed in the radial arteries, but the contrast somewhat obscured by contusion of the left wrist. Temperature on admission, 98°; four hours later, 104.6°; immediately after death, 105°; one-half hour post mortem, 105.4°; pulse, 40 to 64; respira-

tion, 32 to 36; cyanosis just before death, at the end of five hours.

Lesions.—Contusion of scalp, disclosed by incision, extending from coronal suture backward above temporal ridge; fracture in right middle fossa, involving both squamous portion of temporal and greater wing of sphenoid bone; firm epidural clot from laceration of anterior branch of arteria meningea media, measuring three fluid ounces, which filled right middle fossa and flattened temporal lobe laterally and inferiorly. When the clot was removed the brain retained its position, widely separated from the base, and leaving the anterior petrous surface and the adjacent middle fossa exposed. The smaller superficial veins and arterioles of the brain were congested, and the surface between them, at first pale, was soon uniformly reddened. There was a small laceration of the posterior part of the third left temporal convolution; another, somewhat smaller than a buckshot, was found in the anterior part of the pons at the apposition of the transverse and longitudinal fibres. The brain substance was generally hyperæmic, especially in the left hemisphere, but without minute extravasations or thrombi. The surfaces of section soon became deeply reddened and bathed in watery effusion.

CASE LXVIII. *Symptoms.* — Partial unconciousness; recurrent hemorrhage from right ear, succeeded by a flow of serous fluid; vomiting; dilatation of both pupils; retention of urine; greater fulness and strength of the left radial pulse than of the right; mental condition normal; intercurrent bronchitis on the third day, which ran its usual course; from the second day a peculiar dusky and swollen appearance of the face, which continued till within two or three days of death; no other indications of cerebral injury till the fourteenth day, when there was occipital pain, which became general headache, and a little later there were somnolence and occasional irritability. On the eighteenth day, the fifth of this epoch, posterior cervical rigidity; delir-

ium; temperature at its maximum; tenderness along the course of the larger nerves of the left lower extremity from the twentieth to the twenty-fifth days; delirium more active, lucid intervals less frequent, somnolence more continuous, and sense of hearing impaired; deafness progressive till complete; power of articulation gradually lost, and finally communication possible only by gesture; dysphagia occurred more suddenly and a little later. The mental condition varied from normal to that of stupor or delirium; emaciation was progressive; paralysis and hyperæsthesia of the left lower extremity were of late occurrence; recurrence of posterior cervical rigidity was once noted, but was transitory; toward the end, control of urine and fæces was lost; during the last twelve hours unconsciousness was complete, and respiration rapid, insufficient, and entirely nasal. Death occurred on the thirty-first day. The temperature on admission was 97°, became normal in four hours, and was afterward 99° till the invasion of bronchitis, on the third day, when it rose to 103°, and subsided with recovery from the complication. On the tenth day it again rose with the recurrence of intracranial symptoms to 103.4°, and afterward varied from 100° to 104°, and was not often less than 101°+. The post-mortem temperature receded in one-half hour from 103.4° to 103°. The axillary temperatures, carefully recorded from the sixth day, were symmetrical in nearly half the observations, and in the others usually varied two-tenths of a degree, and were rather more frequently higher on the right side. The pulse was usually from 64 to 90. The respiration, always frequent, was rarely less than 30 in the minute from the time of admission.

Lesions.—No external injury; linear fracture extending from squamous, through petrous portion of right temporal bone; simple thrombosis of lateral sinuses from torcular Herophili into jugular veins; punctate extravasations in pia mater; large occipital veins distended; no serous effusion at vertex, but patches of false membrane, mainly

upon left frontal lobe, and upon either side of median fissure. Several ounces of turbid serous effusion at base, and a large amount in lateral ventricles; fibrinous exudation covering pons, medulla, and inferior surface of cerebellum, one to two millimetres in thickness, and in Sylvian fissures; limited contusion of posterior part of surface of right temporo-sphenoidal lobe, covering a space one inch square, which was of a yellowish color and studded with hard miliary hemorrhages; fornix much softened, and brain substance generally hyperæmic and œdematous.

Immediate microscopic examination showed the membranous effusion to be crowded with small round cells which extended for some distance in diminishing quantity into the substance of the underlying cerebellum. Other portions of the brain tissue were unchanged. The *Streptococcus pyogenes* was developed from cultures of the exudation.

CASE LXIX. *Symptoms.*—Consciousness lost, but restored at time of admission; hæmatoma over right frontal region; vomiting; severe frontal headache; face flushed; pupils normal; temperature, 95°; pulse, 90; respiration, 20. One hour later, wide dilatation of right pupil, and right cornea more sensitive than left; sudden unconsciousness, followed by rigidity of left side, and convulsive movements of right. At the end of an hour and a half, temperature, 97°; pulse, 85; and Cheyne-Stokes respiration. Death in three hours from time of injury.

Lesions.—Linear fracture in squamous portion of right temporal bone, continued through anterior part of middle fossa and terminating in body of sphenoid bone; large epidural hemorrhage over lateral surface of right hemisphere nearly to median fissure; blood partially coagulated and derived from posterior division of arteria meningea media; surface of right temporal and anterior part of right occipital lobe somewhat flat-

tened; slight contusion of left second temporal convolution; brain moderately hyperæmic and œdematous.

CASE LXX. *Symptoms.*—Patient admitted to the hospital without history, wholly unconscious and with Cheyne-Stokes respiration; scalp wound in right occipital region; pupils equally dilated; right radial pulsations fuller and more compressible than the left; temperature, 97.6°. In thirty minutes the right pupil became normal, and in four hours also the left pupil, and the temperature rose to 98.4°; the respiration was 16, and the pulse, previously 130, was reduced to 92; unconsciousness continued. In eight hours the temperature was 102°, the pulse 128, and the respiration 40; the patient could articulate, and answered "Yes" to all questions. In eleven hours, temperature, 103.2°; pulse, 140; respiration, 42; and in twelve hours death ensued. Temperature, thirty minutes post mortem, 104.6°.

Lesions.—Linear fracture from right occipital tuber, to left petrous portion. Epidural hemorrhage in left posterior fossæ; cortical hemorrhage over both hemispheres; slight lacerations of inferior surface of both frontal and both temporal lobes; brain substance markedly hyperæmic.

CASE LXXI. *Symptoms.*—Coma; stertor; pulse strong and irregular; respiration slow; slight dilatation of both pupils, which were insensitive; slight twitching of both arms; extremities cold; no external evidence of injury; temperature, 94.2° to 101.2°; respiration, 24, 20, 14; pulse, 42 to 52. Death in eleven hours.

Lesions.—Linear fracture extended from just above and behind right ear into posterior inferior fossa; enormous epidural hemorrhage, derived from posterior division of middle meningeal artery, which compressed right hemisphere; slight laceration of the right parietal lobe, posterior to fissure of Rolando.

CASE LXXII. *Symptoms.* — Unconsciousness, which continued till death; contusions and superficial wounds of left side of face and temporal region; dilatation of both

pupils, of the right more than of the left; hemorrhage from mouth, nose, and right ear; relaxed muscles, and imperceptible pulse at wrist. Death occurred five minutes after admission, and in about an hour after reception of injury.

Lesions.—Hæmatoma over left temporal, both parietal, and right occipital regions, from rupture of intracranial vessels; calvarium crushed on left side anteriorly, and its fragments deeply depressed and distorted; zygoma and both orbital plates comminuted; body of sphenoid bone disintegrated, and base of skull extensively fissured; thin pial hemorrhage covered entire brain, possibly augmented by some cortical effusion at base; limited contusions confined to cortex about right parieto-frontal junction and along right side of median fissure; cortical lacerations upon inferior surface of left frontal lobe and at tip of left temporo-sphenoidal lobe; brain substance generally hyperæmic and œdematous, with a few punctate extravasations.

CASE LXXIII. *Symptoms.*—Patient was found in the early morning, sitting in a chair, in which he was said to have passed the night. He would not reply to questions, from seeming lack of comprehension. He could walk, though he had little control over his limbs; his face was pale and showed traces of vomiting. On admission, there were partial consciousness, right hemiplegia, and hemianæsthesia; dilatation of left pupil and contraction of the right; loss of control of urine and fæces; profuse serous discharge from both ears, and slight œdema of lungs. Two hours later coma was complete and œdema of the lungs had increased. Death occurred in ten hours. Temperature on admission, 99.2°; in two hours, 101.2°; in four hours, 103°; in six hours, 103.4°; in nine hours, 103.8°; in ten hours, when *in articulo mortis*, 104°; thirty minutes post mortem, 106°. The right axillary temperature was 0.2° higher than the left at each observation. Pulse, 90 to 108; respiration, 36, 30, 38.

Lesions.—Slight hæmatoma over right parietal region disclosed by incision; fracture extending from right of occipital tuber, across petrous portion, into greater wing of sphenoid; opacity of arachnoid in right frontal and anterior parietal regions; small cortical hemorrhage over frontal lobes; extensive laceration of frontal, temporal, and inferior portion of parietal lobes on left side; these parts were excavated and filled with a dark solid clot, which was extruded in large quantity through a long tear made in the process of removal of the brain from the cranial cavity; slight ante-mortem cortical rupture through which a little blood had escaped into the middle fossa and ascended upon the frontal region, and another into the posterior cornu of the lateral ventricle, through which the choroid plexus was infiltrated; small, deep laceration upon the anterior border of the left cerebellum; moderate general hyperæmia and marked œdema, with a few punctate extravasations; thrombi in the superior longitudinal and lateral sinuses.

CASE LXXIV. *Symptoms.*—Patient received a scalp wound two days previously, and was found unconscious. On admission to the hospital, mental condition dazed but rational; temperature, 100°; pulse, 68; respiration, 20. Temperature rose on second day to 102° and receded on the third to 98.8°, with normal pulse and respiration. On the fourth day a general convulsion occurred, rather suddenly, and was followed by four others between morning and night. Temperature remained from 99° to 98° —, and on the fifth and sixth days was from 98.4° to 97° —. On the seventh day stupor with loss of fæcal and urinary control, and on the eighth day coma. Temperature, 97° to 98.8° in the morning, and 101.2° to 100.2° in the evening. Pulse, 66, 138, 66, 102. Respiration, 18, 36, 21. On the ninth day, coma continued with contracted pupils and progressive anæmia. Temperature, 100.6° to 101°; pulse, 152 to 146; respiration, 48, 54. Death occurred on the tenth day. Temperature then, 101°; and one hour post mortem, 100.8°.

Lesions.—Slight separation of anterior portion of biparietal suture, continued as an open fissure through median line to centre of frontal bone, and thence as a fine closed fissure through supra-orbital ridge into left orbital plate. Slight epidural hemorrhage beneath the biparietal suture. Large pial hemorrhage over left hemisphere, with thick clot in posterior parietal region, and extending over right frontal lobe into anterior and middle fossæ; slight cortical contusion upon inferior surface of right temporal lobe. Arachnoid opacity along margin of superior median fissure. Brain substance hyperæmic and œdematous.

CASE LXXV. *Symptoms.*—Fell down a flight of stairs; still unconscious on admission; wound in left occipito-parietal region; hemorrhage from left ear; right pupil irresponsive and widely dilated, left pupil moderately dilated; muscular system relaxed; temperature on admission, 95°, and in one hour normal; rose progressively to 104.2°; right axillary temperature uniformly from 0.2° to 0.4° higher than the left till the last observation, when the difference was 2°; respiration, 22 to 24; pulse on admission, 72, irregular and intermittent, and afterward 78 to 86 till immediately before death, which occurred in eight and one-half hours.

Lesions.—Fracture, which extended from left inferior occipital curved line through petrous portion into sella turcica; laceration, two inches long by an inch wide, of inferior surface of left temporo-sphenoidal lobe; another, half an inch in diameter, at anterior extremity of first left temporal convolution; and a third upon inferior surface of right frontal lobe, which involved its anterior half; cortical hemorrhage filled right anterior and both middle fossæ, covered right hemisphere laterally, and extended as a thick clot over right frontal lobe and along corpus callosum quite to cerebellum; some small extravasations in substance of pons; general hyperæmia and punctate extravasations in anterior and posterior portions of brain.

CASE LXXVI. *Symptoms.*—Coma; stertor; left pupil dilated; small wound and larger hæmatoma in left parietal region; sensation diminished in both lower extremities and muscular twitching in right; vomiting; pulse, 52. After trephination a soft epidural clot was discovered and a considerable loss of blood ensued. Using as a guide a fissure which extended through the squamous and petrous portions into the middle fossa, the bone was chiselled and the posterior division of the middle meningeal artery, which was found to be the source of hemorrhage, was clamped. The pulse increased in frequency from 72 to 104; the pupils became normal, but consciousness was not restored, and death occurred a few hours later.

Lesions as above.

CASE LXXVII. *Symptoms.* — Unconsciousness and death immediately after admission.

Lesions.—Skull crushed and flattened on right side; fragments very movable; comminuted on left side; extensive laceration of brain posteriorly in left hemisphere; only small superficial wounds of scalp.

CASE LXXVIII. *Symptoms.*—Coma; stertor; hemorrhage from left ear; contusion of left parietal region; pupils dilated; pulse full and slow; temperature on admission, 98°, and rising progressively to 103.6° at time of death in four hours; no decrease for one hour post mortem; respiration, 18 to 26; pulse on admission, 70, rising to 90.

Lesions.—Fissure extended from left parietal eminence, through squamous and petrous portions into middle fossa; deep laceration of inferior surface of right temporo-sphenoidal lobe and of lateral border of right cerebellum; cortical hemorrhage filled right middle fossa; hyperæmia of right side of brain.

CASE LXXIX. *Symptoms.* — Consciousness lost and not regained; coma grew more profound; slight œdema of scalp in right temporal region; pupils slightly dilated; great restlessness and irritability; lack of urinary control;

temperature on admission, 100.4°, and rising to 108°, with only two or three brief fractional recessions; pulse, 94, 58, 80; respiration, 28 to 24. Death in forty-three hours.

Lesions.—Hæmatoma over whole right side of head; linear fracture from right frontal through parietal bone into inferior occipital fossa; large epidural clot over whole base on right side, extending upward over lateral surface of brain; laceration of inferior surface of both temporo-sphenoidal and both occipital lobes; laceration of inferior surface of both frontal lobes in their anterior portion, very extensive on left side; cortical hemorrhage over posterior border of cerebellum; extensive general hyperæmia with punctate extravasations.

CASE LXXX. *Symptoms.*—Immediate unconsciousness. On admission to the hospital pupils unequal, left dilated, right contracted, neither sensitive to light; urine retained. Temperature, 102.8°; pulse, 96; respiration, 20; eighteen hours later, temperature, 103°; pulse, 80; respiration 24; no change in general symptoms. Operation done and an epidural clot of five ounces removed from temporo-parietal region, and clear fluid from arachnoid cavity. Temperature rose in four hours to 104.8°, pulse to 145, and respiration to 32; after sponge bath, temperature, 102.4°; pulse, 120; respiration, 32. No change in pupils at any time previous to death. On the following day delirium, continued retention of urine, and convulsive movements of both eyes. Temperature, 102.4°, 103°, 101.8°; pulse, 145, 128; respiration, 30 to 32. On the third day, temperature, 103.6°, 102.6°, 104.4°, reduced by sponge bath to 102.4°; pulse, 148 to 140; respiration, 36 to 28. Urinary control lost. On the fourth day temperature was again reduced from 104.4° to 102° + by sponge bath. Patient restless and delirious at times, and complained much of pain in his head. The pupils were responsive to light; clot protruded from cranial opening. The temperature subsequently varied from 102.6° to 100.2° on the sixth day, when it rose progressively to 106°, and was again reduced to 102.2° by the

sponge bath. Death occurred two and one-half hours later, or five days and fourteen hours from time of admission. Temperature thirty minutes post mortem, 105°. Delirium increased during the last day.

Lesions.—Hæmatoma in left parietal region. Linear fracture beginning in anterior and inferior part of left frontal, running upward to middle of parietal, and then downward to anterior border of petrous bone in middle fossa. A second fissure extended from the first, at the fronto-parietal junction to the sella turcica, crossing the groove for the anterior branch of the middle meningeal artery. Large epidural clots compressed the left hemisphere; one weighed three and one-half ounces. Laceration, one-half by one-fourth inch in diameters, of inferior surface of left temporal lobe anteriorly, and one still smaller of inferior surface of left frontal lobe. Cortical hemorrhage over left fissure of Rolando. Lateral ventricles distended with serous fluid; also third ventricle; *iter e tertio ad quartum ventriculum* as large as a goose quill; and small hemorrhage in floor of fourth ventricle, clot one-eighth inch in diameter at base of calamus scriptorius. Moderate general cerebral hyperæmia.

CASE LXXXI. *Symptoms.* — Large hæmatoma over left frontal region; epistaxis and hæmatemesis; simple fissure from left frontal eminence into orbital plate, disclosed by incision. On the sixth day muscular twitching of whole right side, including extremities, but not the face, which ceased entirely in fourteen hours and was followed by left hemiplegia and hemianæsthesia. On the seventh day a convulsion, confined for thirty minutes to the right side but afterward becoming general, occurred two hours before death. Temperature on admission was 100.2°, rose to 104.4° on the same day, and to 105.6° on the next, with recessions, and afterward varied from 102° to 105.2°, with no observation for six hours ante mortem. Pulse on admission was 120, and subsequently 130 to 152. Respiration, 26 on admission, and later 44 to 58.

Lesions.—Fracture extended from the orbit through posterior part of ethmoid, and the body and right lesser wing of sphenoid into floor of right middle fossa; general subarachnoid purulent effusion, most marked in left frontal region below site of fracture.

CASE LXXXII. *Symptoms.*—Conscious on admission: Cheyne-Stokes respiration; dilatation of left pupil; right radial pulse fuller and stronger than the left; hæmatoma on right side of the head anterior to occipital junction, and small lacerated wounds over both frontal eminences; muscular contractions of left side, and later of both sides of body. On admission, temperature, 99.3°; pulse, 104; respiration, 19.

Lesions.—Multiple fracture; fissure across frontal bone above orbits, extending on either side through parietal bone to median line of vertex on both sides, thence to occiput, and on right side behind ear to within an inch of foramen magnum; another fissure on left side extended through orbital plate of frontal and lesser wing of sphenoid into middle fossa. Dura and pia mater were lacerated from right mastoid region to a point just beyond median line. Right motor area extensively lacerated, and right optic thalamus and corpus striatum to lesser extent. Left hemisphere was uninjured.

CASE LXXXIII. *Symptoms.*—Patient came home in a dazed as well as intoxicated condition, and said he had been assaulted and robbed. He was afterward weak and his mind wandered; three days later he was found unconscious and sent to the hospital. On admission he was unconscious, muttered incoherently when roused, and the right eye was contused and the pupil contracted; right arm and leg slightly rigid. Death occurred in fourteen hours. Temperature rose progessively from 104° to 106°, pulse from 108 to 204, respiration from 22 to 68.

Lesions.—Hæmatoma of right temporo-occipital region; stellate fracture above right ear with fissures running through sella turcica into left middle fossa; trivial epi-

dural hemorrhage from diploic vessels at point of fracture; slight pial hemorrhage upon under surface of right frontal lobe; limited subarachnoid sero-purulent effusion upon posterior border of left cerebellum in an area not more than one inch in diameter. Excessive hyperæmia and moderate œdema of brain.

CASE LXXXIV. *Symptoms.*—Patient found unconscious in the street. On admission to the hospital, pupils symmetrical but irresponsive to light. Temperature, 98°; pulse, 100; respiration, 30. Death occurred suddenly in one hour. Respiration had dropped to 4 or 5 per minute.

Lesions.—Wound in median line of occiput; linear fracture extending from a point just to right of occipital median line, forward and upward into right squamous portion and downward through both occipital fossæ nearly to foramen magnum; slight epidural hemorrhage at vertex along line of fracture; cortical hemorrhage over left temporal and parietal lobes laterally, and in somewhat larger amount over inferior surface of left frontal lobe anteriorly; pial hemorrhage over whole left side of base of brain, covering pons at its posterior border, and forming a large clot upon posterior surface of medulla; superficial lacerations of inferior surface of left frontal lobe, one situated along median fissure and another near external border; right cerebellar lobe completely excavated by subcortical laceration, and filled with clot; both lateral ventricles, and the fourth ventricle, distended with clot and serum derived from contusion of choroid plexuses; brain substance moderately hyperæmic and excessively œdematous.

Some subarachnoid effusion and opacity of arachnoid membrane over posterior parietal and anterior occipital regions probably preceded injury.

CASE LXXXV. *Symptoms.*—Primary and permanent unconsciousness; wound above right superciliary ridge; ecchymosis of both eyes; stertor; hemorrhage from mouth, nose, and both ears; left pupil dilated, right con-

tracted, and both insensitive; fibrillar twitching of right chest muscles. No paralysis or muscular rigidity. The temperature on admission was 99.4°; pulse, 120, full and strong; respiration, 13; the temperature rose to 99.6°, and the respiration was reduced to 4. Death occurred in twenty minutes; immediate post-mortem decline in temperature.

Lesions.—An extensive comminuted fracture of frontal bone and both frontal plates extended through the middle fossæ into the petrous portions; the left optic nerve was crushed by a fragment of bone in the optic foramen. The inferior surface of both frontal lobes was deeply lacerated over its whole extent, and a cortical hemorrhage, still fluid, occupied all the basic fossæ, and covered the pons and medulla.

CASE LXXXVI. *Symptoms.*—Primary and permanent complete unconsciousness; hemorrhage from left nostril; dilatation of both pupils; no convulsions or muscular rigidity; respiration not more than four to five in the minute at any time after the receipt of injury and finally not more than one; pulse continued full, strong, and of normal frequency for some moments after respiration ceased. Death in forty-five minutes.

Lesions.—Fracture extending through left side of base into middle fossa; moderate pial hemorrhage covering whole surface of brain, vertex, and base, and also medulla; marked general hyperæmia and œdema; contusion of under surface of left temporo-sphenoidal and frontal lobes.

CASE LXXXVII. *Symptoms.*—Primary and permanent unconsciousness; stertor; dilatation of pupils; loss of urinary and fæcal control, and pulmonary œdema; left radial pulsation fuller and stronger than right; no external injury. Temperature, 104° to 104.8°; pulse, 120 to 166; respiration, 24 to 52. Death in four hours and a half.

Lesions.—Fracture extending into both occipital fossæ,

and a fissure from indirect violence in right middle fossa; large indirect epidural hemorrhage over right frontal region; complete excavation of right frontal lobe with rupture of inferior cortex and consequent cortical hemorrhage over superior surface of whole right hemisphere and left frontal lobe; contusion of third left temporosphenoidal convolution and small extravasation into centre of pons; general hyperæmia.

CASE LXXXVIII. *Symptoms.*—Patient found unconscious in the street. Pupils slightly contracted, urine retained; ecchymosis in left mastoid region, which increased. Temperature, 105°, and pulse frequent. Condition remained unchanged and death occurred in fourteen hours.

Lesions.—Hæmatoma covering whole occipital region. Linear fracture extending through both inferior occipital fossæ into petrous portions of temporal bones. Thick epidural clot in the course of the fracture. Cortical hemorrhage; clot over both frontal lobes, more complete on left side, and extending into all basic fossæ. Laceration of inferior surface of left frontal lobe, extending subcortically into anterior cornu of left lateral ventricle, also crossing median line superficially and then extending subcortically backward to a point opposite to posterior part of the right corpus striatum. This laceration largely excavated both frontal lobes. A small laceration existed upon the inferior surface of the left temporal lobe anteriorly. The brain substance was generally hyperæmic, with many patches in which the vessels were filled with minute coagula.

CASE LXXXIX. *Symptoms.*—Patient found in deep coma; stertor; left pupil slightly dilated. On admission to the hospital scalp wound in right parietal region with linear fracture; hemorrhage from both nostrils; and both pupils slightly dilated and irresponsive. Temperature, 97.4°; pulse, 96; respiration, 20. Coma continued, with Cheyne-Stokes respiration. Temperature, 99.8°; pulse,

110; respiration, 24. Death forty-five minutes later and six hours after admission.

Lesions.—Linear fracture extended from middle portion of right parietal bone through groove for middle meningeal artery into middle fossa. Large epidural hemorrhage greatly compressed right hemisphere.

CASE XC. *Symptoms.*—Patient, after having fallen into the hold of a vessel, walked about a block and then fell, but though stupid was able to rise and to walk a little farther; then became slightly delirious. On admission to the hospital, mental condition irritable and speech incoherent, right pupil dilated and irresponsive to light. Temperature, 98.4°; pulse, 64; respiration, 16. Two hours later there was a unilateral convulsion, beginning in the left leg and extending to the arm, which was followed by coma continuing till death four hours after admission. In the interval there were six similar convulsions. Temperature at time of first convulsive seizure, 99°; pulse, 86; respiration, 20; temperature just before death, 99.2°; pulse, 122; respiration, 22.

Lesions.—Contusion of scalp about left parieto-occipital junction; linear fracture extending from this point to within one-half inch of foramen magnum; superficial laceration of inferior surface of left occipital lobe, one inch in length and corresponding cortical clot not larger than a half-dollar; very moderate cerebral hyperæmia. The previous history of this patient was unknown.

CASE XCI. *Symptoms.*—Patient while in an alcoholic condition fell a distance of five stories, striking upon his head; primary and permanent unconsciousness; severe hemorrhage from left ear, nose, and mouth, which continued till death thirty minutes afterward.

Lesions.—Ecchymosis of both eyes and extensive hæmatoma of scalp; depressed fracture of right parietal bone near median line with multiple fissures extending to base and involving middle and posterior fossæ on both sides and left petrous portion. Two fissures completely in-

cluded the calvarium, and another passed through the body of the sphenoid bone. An independent fissure from indirect violence ran backward from the foramen magnum. Small epidural hemorrhage beneath depression at vertex; pial hemorrhage from meningeal contusion over right hemisphere; superficial laceration of inferior surface of left temporal lobe with a small consequent cortical hemorrhage in middle fossa; both lateral ventricles blood stained, and the left communicating with a small laceration in occipital lobe. The ventricular hemorrhage was apparently from contusion of the choroid plexuses. The brain substance was moderately hyperæmic, with thrombi in the minute vessels.

CASE XCII. *Symptoms.*—Patient found unconscious in the street, but delirious when admitted to the hospital one hour later; pupils slightly dilated, and afterward irregular; urine, at first voided naturally, was afterward retained. Temperature on admission, 98°; rose to 100.4°, and on the third day to 103°, and receded to 102.6° before death, at the end of three and one-half days; pulse, 100 to 130; respiration, 20 to 26.

Lesions.—Linear fracture extending from right occipital region to petrous portion on either side. Laceration of inferior surface of left temporal lobe, and of left frontal lobe near inner border. Extensive contusion of posterior border of left occipital lobe, involving cortex and subcortex to a depth of one inch, and the tissue softened, grayish, and filled with dark punctate extravasations. Cortical hemorrhage over left hemisphere at both base and vertex.

CASE XCIII. *Symptoms.* — Patient after a fall of thirty-two feet found unconscious with profuse hemorrhage from the right ear; on admission to the hospital, stupid; unable to give any account of his accident then or afterward; profuse hemorrhage from the ear continued; deviation of eyes to the right; vomiting, restlessness, and general muscular twitchings through the day; no other

symptoms except some frontal headache. On the third day the hemorrhage from the ear was replaced by a profuse serous discharge which continued till death. The mental condition was dull, but rational, with frontal headache and occasional restlessness; no disturbance of speech. On the fourth day slight delirium, which was afterward continuous and became muttering, and was later active in character. On the fifth day there were dry tongue and picking at the bedclothes, and on the sixth day the skin was clammy and there were large bronchial râles. On the seventh day the pupils, which had been normal, were very slightly dilated, the conjunctival reflex was absent in the right eye, and the lids did not respond to irritation; the left lid and conjunctiva were very sensitive. Restlessness continued till death. The temperature on admission was 98°, rising to 102.8° on the second day, to 103.8° on the third, to 104° on the fourth, to 105° on the fifth, to 106° on the sixth and seventh, with unimportant recessions. The pulse did not exceed 108 in frequency, and the respiration was from 20 to 28 till death on the seventh day.

Lesions.—No injury of the scalp; linear fracture beginning in the right squamous portion of the temporal bone at a point just above the petrous portion, to which it extended in two fissures, one running along its anterior surface, and the other crossing its superior border and posterior surface and extending to foramen magnum. The posterior petrous surface was comminuted, and one small fragment was quite detached and clinging to the dura. There were moderate subarachnoid serous effusion and arachnoid opacity in the right parietal region. Purulent effusion existed in moderate amount upon the anterior border of the pons and upon the posterior border and contiguous portion of the inferior surface of the cerebellum. There was also a full drachm of laudable yellow pus in the median line between the reflections of the arachnoid membrane upon the cerebellar lobes. No effusion upon the

medulla or cervical portion of the spinal cord. There were a slight cortical contusion of the right parietal lobe and a large cortical contusion, three by two and a half inches in diameters, involving the middle portion of the first left temporal convolution and the contiguous parietal surface, marked by dark discoloration and punctate extravasations; no laceration. The brain substance was excessively hyperæmic and œdematous, but without thrombi. The right lateral ventricle was filled with clear serous effusion, and the left contained a lesser amount.

CASE XCIV. *Symptoms.*—Patient found unconscious; pupils slightly contracted; hemorrhage from the nose. On admission to the hospital, pupils normal, small hæmatoma in left posterior temporal region, and a cessation of nasal hemorrhage. Eight hours later pupils dilated, muscular twitchings in both arms, and ecchymosis of left anterior frontal region. Profound unconsciousness without change in symptoms continued till death fifteen hours after admission. Temperature, 97.6°; rose progressively to 103°, and immediately receded post mortem. Pulse, 70 to 100; respiration, 24 to 27.

Lesions.—Three fissures radiated from the occipital tuberosity; one extended forward above the right petrous portion into the middle fossa, another to the right side of the foramen magnum, and a third ended in the left inferior occipital fossa. Cortical hemorrhage, in moderate amount, covered the inferior surface of both frontal lobes, filled both Sylvian fissures, and extended backward in the central region of the brain from a point just in front of the optic chiasm across the crura cerebri to the anterior border of the pons, and also reached the lateral surface of each temporal lobe. A small pial hemorrhage was found upon the superior surface of the cerebellum, and in the median fissure. Laceration of inferior surface of left frontal lobe, upon its anterior and external border, and excavating its subcortical substance to a moderate extent. Subcortical contusion of anterior part of right optic thalamus, with

punctate extravasations. Subcortical laceration of pons involving its transverse fibres, filled with clot, one-half inch in diameter. Very moderate hyperæmia of the brain with no œdema.

CASE XCV. *Symptoms.*—Patient transferred from alcoholic ward without history; general convulsions, stupor, and loss of urinary control; right radial pulsations weaker than the left; subconjunctival hemorrhage in both eyes, right pupil dilated; both pupils irresponsive to light, and both eyes protruding. On the second day occasional restlessness, picking at the bedclothes; other conditions unchanged. On the third day loss of fæcal control, want of symmetry in radial pulsations less noticeable but obvious, restlessness and efforts to get out of bed; pupils as before. On the fourth day coma and death, which occurred in three days and six hours. Temperature, 99° on admission to ward, rising progressively with slight recessions to 105.2°; pulse, 120 to 140; respiration, 24 to 48.

Lesions.—Slight hæmatoma in left temporal muscle. Linear fracture extending across both lesser wings of sphenoid bone into middle fossæ. Slight epidural hemorrhage, about one and one-half drachms. Cortical hemorrhage over right temporal and parietal lobes. Laceration of right temporal lobe, one by one and a half inches in diameter, and confined to cortex; beneath it punctate extravasations. Brain exceedingly hyperæmic and œdematous. Serous fluid to amount of two drachms in each lateral ventricle. Basic arteries atheromatous.

CASE XCVI. *Symptoms.*—Patient fell eight or ten steps, striking upon his head. On immediate admission to the hospital: surface cold and moist; semi-consciousness; pain in the head; hemorrhage from both nostrils; respiration rapid and irregular, becoming deeper and slower upon disturbance; pupils moderately dilated and irresponsive to light, and facial paralysis with ptosis, which was ascertained to have existed previous to the injury. Incision through a hæmatoma on the right side of the head, anterior to the

occipital tuberosity, disclosed a depressed and fissured fracture; and a loose fragment of bone, two inches by one inch in diameters, was removed. Through the day the pupils were symmetrically contracted, the pulse was intermittent, respiration irregular, and patient very restless and irrational, with loss of urinary control. On the second day restlessness continued, with muscular twitchings in both upper and lower extremities. Death occurred at the beginning of the third day without change in symptoms. Temperature on admission, 97.2°, rising progressively through the day to 105.2°. In the morning of the second day, temperature, 102.6°; rose progressively to 106.8°, and with one recession to 105.2° again rose to 106.8° at the time of death, with an immediate post-mortem decline. Pulse, 96, 148, 120, 180; respiration, 26, 48, 24, 44.

Lesions.—Hæmatoma over right side of head and occiput; skull crushed and flattened with radiating fissures involving base; epidural hemorrhage over left occipital and posterior part of left parietal lobes; pial hemorrhage over both occipital regions. The hemorrhages were of moderate amount. Laceration of inferior surface of both frontal lobes anteriorly, confined to cortex, and of left temporal lobe; slight contusion of inner border of left parietal lobe; slight cortical hemorrhage at base; brain substance throughout very hyperæmic and œdematous.

CASE XCVII. *Symptoms.*—Loss of consciousness, dilatation of left pupil and contusion of left palpebral region, hemorrhage from both nostrils, and clammy skin. Temperature, 98°; pulse, 148; and respiration, 63. Hemorrhage from left nostril continued after admission to the hospital, and temperature rose progressively to 103.2° at death six hours afterward, with post-mortem increase to 103.4°.

Lesions.—Slight contusion of scalp in left parietal region; fracture of sphenoid bone, extending from crista

galli through sella turcica into its left lesser wing; laceration of inferior surface of left frontal lobe, two and one-half inches long and one-half inch in depth; slight general hyperæmia of brain; no hemorrhages.

CASE XCVIII. *Symptoms.*—Patient thrown from a cable car and struck upon the back of his head; conscious and rational, with hemorrhage from left ear and nose, when reached by ambulance surgeon. Pupils and muscular action normal, and radial pulsations symmetrical. On admission to the hospital pain in left occipital region and continued hemorrhage from ear with hæmatemesis, which was frequently repeated during the day and night. The pain in the head was continued till stupor supervened (ten hours), which lapsed into coma (fifteen hours), with loss of urinary control, slight muscular twitchings upon the right side, and slight dilatation of the pupils. Death occurred in twenty-seven hours. Temperature on admission, 98°; rose progressively to 104°, with a single recession of 0.7°, and one hour post mortem was 105°. Pulse, 64 to 80; respiration, 20 to 38.

Lesions.—Linear fracture extending from left parieto-squamous suture anteriorly to eminence for semicircular canal upon anterior surface of petrous portion. Slight hemorrhage into substance of temporal muscle, but none upon surface of dura mater. Cortical hemorrhage over whole superior surface of left hemisphere, and in large amount, in both posterior and both middle fossæ. Deep laceration crossing posterior part of superior surface of left occipital lobe. Entire disintegration of whole inferior surface of right frontal, and of anterior half of left frontal lobe, including cortex and subcortex, to a depth of three-fourths of an inch. On the right side the laceration reached subcortically quite to the anterior border of the corpus striatum, and on the left to within one-half inch of the same plane. Hemorrhage into centre of pons with clot one-half by three-fourths of an inch in diameters. Moderate general hyperæmia and œdema of brain.

CASE XCIX. *Symptoms.* — Primary and permanent unconsciousness after a fall of six feet. Right pupil dilated, left contracted, both irresponsive to light; pulse full and slow, and radial pulsations symmetrical at the wrists; rigidity of entire body, which continued till death; hemorrhage from left ear, and in slight amount from nose. Small scalp wound in left occipital region. Later, stertor, Cheyne-Stokes respiration, and lack of urinary control. Death occurred in nine hours. Temperature on admission, 98.4°; in three hours, 103.2°; in six hours, 106.2°, and at death, 109.2°; thirty minutes post mortem, 109.2°. Pulse, 60 to 108, six hours after admission; respiration, 34 to 37.

Lesions.—Linear fracture extending from a point one inch above left petrous portion of temporal, through its anterior surface into sphenoid bone; some extravasation of blood into temporal muscle. Cortical hemorrhage, in considerable amount and partially fluid, covering right hemisphere superiorly, and right temporal and occipital lobes inferiorly, derived from superficial laceration of whole lateral surface of right temporal lobe. General hyperæmia and œdema of brain not very marked.

CASE C. *Symptoms.*—Primary and permanent unconsciousness from a fall of fifteen feet upon left side of head; hæmatoma over left fronto-parietal region; no hemorrhages; stertor; right pupil slightly dilated; rigidity of both sides of body, more marked upon left. On admission to the hospital, temperature, 101°; pulse, 86; respiration, 20; right side very rigid till death two hours later. Temperature then 101°, and one-half hour post mortem, 102.1°.

Lesions.—Linear fracture extending from frontal eminence to middle of left petrous portion. Epidural hemorrhage over an area of three inches about fronto-parietal junction; laceration of first and second left temporal convolutions, one and one-fourth inches long, three-fourths of

an inch wide, and three-eighths of an inch deep; cortical hemorrhage over lateral surface of lobe.

CASE CI. *Symptoms.*—Primary unconsciousness from a fall of twenty feet; slight wounds of face and a fracture of femur; pupils symmetrically dilated; hemorrhage from left nostril; and twitching of right side. After admission to the hospital, patient remained in a semiconscious, restless condition, with loss of urinary control. Second day, same conditions continued, with dysphagia, slight twitching of the right side, great weakness, and profuse perspiration, till death at the end of thirty-seven hours. Temperature on admission, 98°; later, 102°+, 101°+ for ten hours, and then progressive rise to 107.2° with immediate post-mortem recession; pulse, 104 to 160; respiration, 24, 20, 60.

Lesions.—Open fissure in left inferior occipital fossa running into groove for lateral sinus; no epidural hemorrhage; opacity of arachnoid on left side; slight cortical hemorrhage over left temporal lobe posteriorly; laceration of inferior surface of same lobe, one inch by three-eighths of an inch in size, confined to cortex; another laceration of the same dimensions upon inferior surface of left occipital lobe; marked general hyperæmia and œdema of brain substance.

CASE CII. *Symptoms.*—Patient admitted to the hospital after having fallen to the ground in a convulsion; wound in right parietal region, with a diffuse hæmatoma; no hemorrhages; pupils symmetrically dilated; primary and permanent unconsciousness; no muscular symptoms; several convulsions occurred before death six hours later. Temperature, 100.6° to 107°, and one hour post mortem, 108°; pulse, 110; respiration, 30.

Lesions.—An open fissure extended from squamous suture into petrous portion; laceration of inferior surface of right temporal lobe, one inch in length; cortical hemorrhage over fissure of Sylvius and island of Reil; pia mater intensely congested with subarachnoid serous effusion;

hyperæmia and œdema of the brain substance. A small gumma, one-half by one-fourth inch in size, was situated in the left frontal region.

CASE CIII. *Symptoms.*—Patient, aged four years, fell one story, striking his head upon the pavement. Hæmatoma over right parietal eminence; hemorrhage from right ear; primary and permanent unconsciousness; vomiting; no muscular symptoms, except loss of reflexes on the right side. On admission to the hospital, temperature, 97.6°; pulse, 144; respiration, 28. A series of right unilateral convulsions, each beginning in the forehead and involving the intercostal muscles, occurred soon afterward; each paroxysm was violent and lasted five minutes, followed by repeated attacks of vomiting, and by paroxysms of hiccough which alternated with stertor; loss of fæcal and urinary control. The right leg remained in tonic spasm. Four hours after admission, temperature was 103.4°; pulse, 120; respiration, 40; convulsions upon the right side had ceased, and were followed by constant twitchings of the left side of the mouth and of the left leg; pulmonary œdema supervened, and death occurred at the end of eighteen hours. The temperature fell in four hours from 103.4° to 100°, and then rose progressively to 109°, with immediate post-mortem recession. The pulse rose from 110 to 150, and the respiration declined from 40 to 30.

Lesions.—Subperiosteal hæmatoma; simple depressed fracture involving central portion of right squamous suture, from which extended two fissures, both open and filled with blood clot—one through petrous portion to foramen ovale, and the other through posterior part of squamous portion to within one-half inch of parietal angle; cortical hemorrhage in middle and posterior fossæ from an extensive direct laceration of lateral surface of temporal lobe involving both dura and pia mater.

CASE CIV. *Symptoms.*—The patient's head was struck in the occipital region by a descending elevator and forced

forward upon a railing; scalp wound of the occiput eight inches long; fracture of nasal bones and contusion of both eyes; hemorrhage from both nostrils; no loss of consciousness; no muscular symptoms; pupils slightly dilated, afterward unchanged. On admission to the hospital, vomiting of blood and partly digested food, followed by chill, and a little later by delirium; loss of urinary control, which was permanent; and restlessness through the night. Second day, patient rational, soon becoming stupid, restless, and at night suffering severe pain in the head but quiet and sleepless. Third day, delirious, restless, and sleepless, with some post-cervical rigidity, and twitching of fingers of both hands. There were at one time alternating convulsive movements of the lower limbs, flexion of one at the knee and hip being coincident with extension of the other. These movements were about twenty in the minute. Death occurred at the end of the third day. The temperature on admission was 100°, rose in four hours to 104.4°, fell two hours later to 102.4°, ranged from 102° to 102° + till end of second day, and afterward from 104° to 105.4°, with post-mortem elevation to 105.6°. The pulse varied from 75 to 116, and the respiration from 18 to 32.

Lesions.—Fracture, confined to anterior fossæ and extending from posterior border of cribriform plate on the right side by a wide curve forward and outward, and then inward through both orbital plates to a corresponding point on the left side. The roof of the orbits was elevated and tilted forward, and the frontal sinuses were made continuous with the cranial cavity. Blood clots extended from a moderate epidural hemorrhage upon the floor of the anterior fossæ into the orbits. Laceration of central portion of right frontal lobe, one and one-half inches by three-eighths of an inch, confined to the cortex, and caused by a ragged projection in the displaced orbital fragment. The membranes upon the posterior half of the vertex on either side were excessively hyperæmic,

while upon the anterior half they were of a dirty yellow color, œdematous, and elevated by a sero-purulent subarachnoid exudation; the subjacent convolutions were flattened, and their sulci obliterated. The line of demarcation was well defined. In the posterior segment was a pial hemorrhage. The whole base of the brain was covered with a purulent effusion. The brain substance was excessively hyperæmic and œdematous.

CASE CV. *Symptoms.*—Primary and permanent unconsciousness; manner of injury unknown; wound in right occipito-parietal region, right pupil dilated, transient left hemiplegia. Temperature, 100°; pulse, 90; respiration slightly increased in frequency and stertorous. Ecchymosis over right mastoid process after three days. Right unilateral convulsions began on the fifth day, and continued with increasing severity and frequency till death on the ninth day. Final temperature, 103°.

Lesions.—Fracture of right occipital bone, extending from point of external injury into foramen magnum; no epidural hemorrhage; laceration of right parietal lobe at vertex with consequent cortical hemorrhage.

CASE CVI. *Symptoms.*—Patient was knocked down and struck the back of his head upon the sidewalk. On admission to the hospital thirty minutes later, contusion of scalp above and to the left of the occipital tuber, stupor from which patient could be roused to answer simple questions, nearly normal pupils, and no hemorrhages or muscular symptoms; profound coma, with pupils contracted to a pin's point and entirely irresponsive, at the end of twenty-four hours. In thirty-five hours, slight general convulsion; pupils became widely dilated; pulse rose from 60 to 160, temperature unchanged; thirty minutes later respiration suddenly dropped to four in the minute, and death occurred thirty-five minutes afterward. Temperature on admission was 98°, and did not at any time exceed 102.4°; pulse, 60 to 80, till second day; respiration, 18 to 28.

Lesions.—Linear fracture extended from site of external injury through right parietal and temporal bones to floor of middle fossa; also small independent fracture in right orbital plate; epidural hemorrhage on the right side extending to the base; pial hyperæmia with minute hemorrhages over same area; laceration of right temporal lobe one and three-fourths inches long, by one inch wide, and three-fourths of an inch deep, and filled with clot, involving posterior part of first and second convolutions; superficial laceration of outer half of inferior surface of right frontal lobe; laceration in centre of right optic thalamus, of the size of a hazelnut, with punctate extravasations near its margin; several minute hemorrhages in floor of fourth ventricle; cortical hemorrhage, covering right parietal region and base, extended over medulla. General hyperæmia of brain substance.

CASE CVII. *Symptoms.* — Patient, aged three years, fell forty feet, striking the right side of his head upon the pavement; primary and permanent unconsciousness; hæmatoma over whole lateral parieto-occipital region; subconjunctival hemorrhage in right eye; pupils normal; left radial pulse stronger than the right; several convulsions while in the ambulance. On admission to the hospital the convulsions continued, being confined to the right side, and involving pectoralis major, deltoid, and supraspinatus and infraspinatus muscles of the shoulder, and the adductors of the hip and extensors, causing rotatory movements of the arm and pounding of the heel at every contraction; each paroxysm began in the arm. Loss of urinary control, and Cheyne-Stokes respiration for two hours before death, which occurred in twenty-four hours. Temperature on admission, 97.6°; rose to 105.2°, with immediate post-mortem recession; pulse, 102 to 150; respiration, 64, 44, 60.

Lesions.—Compound, comminuted, depressed fracture of right parietal bone, with fissures radiating to coronal and lambdoid sutures, and separation of sagittal and lamb-

doid sutures; a fissure extending into middle fossa; rupture of dura mater; epidural hemorrhage over right vertex; laceration of parietal and temporal lobes, three inches by one-half inch in extent, filled with clot, and crossing fissure of Rolando; moderate cerebral hyperæmia, most marked in the left hemisphere.

CASE CVIII. *Symptoms.* — Patient fell from a mail wagon to the ground, striking upon his head; primary and permanent unconsciousness; wound and hæmatoma in right occipito-parietal region; hemorrhage from right ear and nostril; right pupil dilated, left contracted; radial pulsations symmetrical; muscular twitching of both arms and to a slight extent in left leg. Temperature, 99°; pulse, 68; respiration, 15. No change in symptoms. Death in forty minutes. Temperature, 98.4°, with immediate post-mortem recession.

Lesions.—Linear fracture extending from right occipital bone through petrous portion; epidural hemorrhage covering right hemisphere and forming a thick clot; no lacerations; contusion of inferior surface of right temporal lobe. General cerebral hyperæmia and œdema; some fluid in lateral ventricles.

CASE CIX. *Symptoms.* — Patient fell from his chair, and was said to have been in a convulsion; primary and permanent unconsciousness; profuse hemorrhage from the right ear; right pupil markedly contracted, the left dilated; rigidity of left arm followed by twitching of the muscles. On admission to the hospital, temperature, 97.2°; pulse, 60; respiration, 22; four general convulsions occurred at considerable intervals, in the last of which the patient died, twelve hours after admission. Both pupils had become equally dilated. Temperature rose to 106.8°, with immediate post-mortem recession. Pulse, 60 to 96; respiration, 22 to 40.

Lesions.—No external injury, except small effusion of blood over right mastoid process. Linear fracture extended from occipital tuber through junction of middle

and anterior thirds of the right petrous portion into middle fossa; an independent fracture, linear in the outer table, extended from the anterior inferior angle of the left parietal bone to a point in the squamous portion opposite the petrous junction; a small triangular bit of the inner table was raised upward and by its sharp point lacerated the middle meningeal artery at its bifurcation; a consequent epidural hemorrhage compressed the left hemisphere laterally, and filled all the basic fossæ upon that side; no pial hemorrhage; small cortical hemorrhage, derived from a small and deep laceration of the external border of the right frontal lobe, covered both frontal and the left parietal lobes; contusion, one inch square, of left occipital lobe about the angular gyrus; contusion of whole inferior surface of left temporal lobe, and another of the anterior two-thirds of the inferior surface of left frontal lobe; punctate extravasations in the pons; moderate general hyperæmia and œdema.

CASE CX. *Symptoms.*—Patient during a street altercation was jabbed in the right eye with the end of an umbrella; in an alcoholic condition when admitted to the hospital on the following day. Cornea opaque and pupil immovable, subconjunctival hemorrhage, and constant pain in the eye. Temperature, 98.6°; pulse, 80; respiration, 20. He became delirious on the third day, and from that time some grade of delirium, with restlessness and occasional pain in the head, persisted till his death on the forty-fifth day. On the forty-second day he became stupid, and there was a discharge of pus from the orbit, followed by final coma and loss of urinary control. There were at no time localizing symptoms. The eye was removed by Dr. Callan on the eighteenth day. The temperature on the third day was 100° to 102°; on the fourth day 101° to 104°; and till the forty-first day was usually from 98°+ to 102°, and once on the twenty-second day again rose to 104°. From the forty-first to the forty-fifth day it was from 104° to 107.2°, and was without immediate post-

mortem change. The pulse usually ranged from 68 to 100, and the respiration was only moderately increased in frequency, till near the end of life.

Lesions.—Only a fine fissure of orbital wall; purulent subarachnoid effusion at base, most marked on left side and upon cerebellum, and extending over whole lateral aspect of left hemisphere; a moderate amount of muddy-looking fluid in right lateral ventricle and a somewhat smaller amount in left; left choroid plexus infiltrated with pus and lymph. No other lesions. Simple general hyperæmia.

CASE CXI. *Symptoms.* — Patient struck upon the head by a piece of chalk, weighing twenty pounds, which had fallen twenty feet; loss of consciousness for five minutes. Hæmatoma in left supra-orbital region, extending into the eyelid; profuse hemorrhage from left ear and from both nostrils; free hæmatemesis; right radial pulsations stronger than left; pupils normal. On admission to the hospital, temperature, 98°; pulse, 68; respiration, 24; parietal fracture disclosed by incision; restlessness and irritability after restoration to consciousness. Second day, restlessness and twitching of the right arm alternating with somnolence; the left radial pulsations had become fuller than the right, and this condition was afterward unchanged. Third to fifth days, profuse serous discharge from the left ear; severe pain in the left side of the head; delirium and struggling to get out of bed at night; delusions; loss of consciousness; and finally progressive asthenia, irregular and labored respiration, dilatation of the left pupil and contraction of the right. Death in four days and fourteen hours. The temperature did not exceed 100° till within the last twenty-four hours, when it rose to 106.6°, and receded to 104.4°, with immediate further post-mortem recession. The pulse did not exceed 84 till a few hours before death; respiration, 24 to 42.

Lesions.—Linear and open fissures, which were confined to left side, of which two were parallel and extended

from orbital plate through vertex; coronal suture opened; three other fissures intersected these at right angles. An independent fracture (indirect) extended from left foramen ovale to tympanic cavity. Laceration, one and one-half inches by three-fourths of an inch in extent, filled with clot, upon inferior surface of left frontal lobe, due to angular elevation of orbital plate; contiguous subjacent brain substance yellow and slightly indurated; adjacent cortex the seat of punctate extravasations, and of small hemorrhages; slight epidural hemorrhage over left frontal lobe; cortical hemorrhage at base of brain, about four ounces of a brownish-red fluid; purulent subarachnoid effusion at base and extending into spinal canal; convolutions at base flattened, œdematous, and yellow in color; lateral ventricles filled with a sanious fluid.

CASE CXII. *Symptoms.*—Patient fell down one flight of stairs. On admission to the hospital hemorrhage from mouth, nose, and left ear, and subconjunctival in both eyes; partial loss of consciousness, which became complete; temperature, 99.6° to 103°; pulse, 78; respiration, 20; became stertorous. Death occurred in seventeen hours.

Lesions.—Fracture involving both orbital plates of frontal, left greater wing of sphenoid, left petrous portion, and basilar process of occipital bone; skull thin and brittle; patient, aged fifty-five years; laceration of inferior surface of cerebellar lobes.

CASE CXIII. *Symptoms.*—Patient found unconscious in the street. On admission to the hospital, profound coma; large hæmatoma in right occipito-parietal region; no hemorrhages; no muscular disorders, but marked relaxation; retention of urine and loss of fæcal control; pupils symmetrical and moderately dilated; temperature 97.6°, with progressive increase to 107° at time of death fifteen hours after admission, and no immediate post-mortem change; pulse, 49 to 160; respiration, 38 to 60.

Lesions.—Fracture extending from right of occipital tuber into occipito-temporal suture; laceration, one and one-

half by two and one-half inches in extent, of inferior surface of right occipital lobe, filled with clot and débris of brain tissue; contusion of both frontal lobes.

CASE CXIV. *Symptoms.* — Patient fell twelve feet, striking upon the left side of his head; three scalp wounds; hemorrhage from left ear; primary and permanent unconsciousness; slight dilatation of right and slight contraction of left pupil. Death in four minutes after admission to the hospital.

Lesions.—Compound stellate fracture of left squamous portion and contiguous occipital bone, with open fissures running through middle and posterior fossæ, and left petrous portion; epidural hemorrhage in left occipital region, about two ounces; pial hemorrhage over both hemispheres and cerebellum; blood coagulated; no laceration; independent pial hemorrhage over superior cerebellar surface; clot in right lateral ventricle; not much general hyperæmia and no œdema.

CASE CXV. *Symptoms.*—Patient fell in the street while intoxicated; rather profuse hemorrhage from left ear; no loss of consciousness; pain in the head; stupor; in the opinion of the family mental condition different from that usual to the patient when drunk; restlessness, headache, and stiffness of the neck; and after two days admission to the hospital. There was then no external injury of the head, but there were stupor, somnolence, and a disposition to resist every disturbance; a few hours later mechanical restraint became necessary and delirium was accompanied by delusions; hemorrhage from left ear recurred; temperature, which on admission was 99.2°, rose to 102°; pulse, 50; respiration, 30. The hemorrhage from the ear and the delirium continued through the next day, and temperature rose progressively to 105°, and was then reduced by an alcohol bath. The hemorrhage from the ear ceased, delirium diminished, and the temperature did not exceed 103°+, on the following day. Stupor afterward alternated with delirium, the temperature of five

days ranged from 102° to 102°+, and the pulse from 60 to 112; coma supervened and death resulted from asthenia on the ninth day. The final temperature was 103.6°, with post-mortem increase to 106.8°.

Lesions.—Separation of lambdoid suture for about one inch, and linear fracture extending from it through left posterior fossa and petrous portion; laceration of inferior surfaces of both frontal and both temporal lobes; extensive and deep in the left frontal and left temporal lobe; large cortical hemorrhage in all the basic fossæ, especially in the left anterior and middle; moderate subarachnoid purulent effusion, stained with blood, mainly at the base. General cerebral hyperæmia.

CASE CXVI. *Symptoms.*—Patient fell down stairs two days previous to admission to the hospital; ecchymosis of right eye; stupor and restlessness; retention of urine; right pupil dilated and only partially responsive to light; plantar, patellar, and cremasteric reflexes absent. Second day, stupor increased progressively, right radial pulsations stronger than the left, loss of urinary control, respiration irregular; and before death, which occurred in forty-seven hours, the pupils became more nearly symmetrical, the eyes were turned to the right, the head was somewhat extended, and there was commencing pulmonary œdema. The temperature was in the first twenty-four hours, 103°, 100°, 104°; and in the second, 104.2° to 107.2°, with no immediate post-mortem change. The pulse was 100 to 138, and the respiration, 18 to 60.

Lesions.—Linear fracture extending from anterior part of right temporal ridge through middle fossa into horizontal plate of ethmoid bone; small epidural clot in middle fossa, and a corresponding pial hemorrhage of not m larger size; moderately large subarachnoid serous sion; general cerebral hyperæmia and œdema; no lace tion or evidence of arachnitis.

CASE CXVII. *Symptoms.* — The patient in a colli was thrown from his bicycle, and was primarily u

scious. He was taken to his house, where he had a convulsion, and was then removed to a hospital, where he remained forty days; no record of his condition during this time is obtainable. He was afterward treated by an oculist for exophthalmos; he resumed his professional occupation, and was said to have been in good physical health, but a distinct mental change was observed by his family. His temper was irritable and his conversation, which had been hitherto irreproachable, became remarkably obscene without any apparent appreciation on his part of its impropriety. One week before his admission to St. Vincent's Hospital, and six months after the reception of the injury, he became suddenly apathetic, and soon fell into a stupor, with loss of fæcal and urinary control and the accession of a febrile movement. When admitted to the hospital he gave no response to questions and lay motionless without indication of intelligence; a faint cicatrix was visible across the forehead; the odor of the breath was peculiar; the left pupil was much dilated and entirely irresponsive, and the right eye protruded; there were no muscular symptoms, and the radial pulsations were symmetrical. The temperature was 102°; pulse, 120; respiration, 20. Second day, low delirium, incoherence, and at times deep flushing of the face. Third day, general condition unchanged. Fourth day, more restless and actively delirious; enema given and bowels moved for the first time. An examination of the eyes showed a descending neuritis of right optic nerve; and an exophthalmos of the right eye, increase of tension, and œdema of the retinoid area, probably the result of venous obstruction in the optic foramen (Callon). Nourishment and medication were at all times difficult. Fifth day, restlessness and delirium increased; the pulse grew weaker and the respiration more frequent; the face became dusky, and death occurred. The temperature was increased on the third day from 101°+ to 103°–105°, on the fourth day reached 106°, and on the fifth day was held at 101.8°

to 103.8° by alcohol baths; final temperature 105.4°. The pulse ranged from 130 to 146, and respiration from 24 to 42.

Lesions.—The line of a consolidated fracture extended from the left temporal fossa across the forehead, three-fourths of an inch above the supra-orbital ridges, to a point three-fourths of an inch internal to the right external angular process, and then with a curve passed upward and inward to the median point of the coronal suture. The line of former fracture was very faint and showed no displacement of the fragments; on the inner surface of the bone it was rather more distinct; no evidence of fissures leading to the base. The inner half of the left orbital process of the frontal and the left lesser wing of the sphenoid had disappeared; the free edge of bone was rounded, and the remainder of the process was white and of natural appearance. The horizontal plate of the ethmoid, and superior surface of the sphenoid body, had also disappeared from the crista galli to the dorsum ephippii; the exposed cellular spaces below were blackened and infiltrated with pus. A cyst projecting from the right frontal lobe with the investing cerebral membranes rested in this central cavity of bone. Both frontal lobes were much softened, yellowish in color, and adherent to the dura mater. The anterior inferior portion of these lobes was too much softened for examination; their superior surfaces were of normal character. The cyst contained from three to four ounces of greenish-yellow pus, which was subsequently found to contain the *Staphylococcus pyogenes aureus;* it was confined to the right lobe but projected across the median line. There was no evidence of former hemorrhages and no general hyperæmia; but there was much subarachnoid fluid beneath the cerebellum, and the brain substance was very œdematous.

Case CXVIII. *Symptoms.*—Patient fell eight feet and was found unconscious; he was transferred to Bellevue from another hospital ten days later, and was then in violent delirium. Traces of hemorrhage from the left ear

and of a wound of the left side of the head were still visible; the mouth was drawn to the right, the reflexes were generally absent, the pupils were widely dilated and insensitive, and the radial pulsations were symmetrical. He died thirty-three hours afterward. The temperature on admission was 104.2°, fell to 102.8°, and at death was 107°, with immediate post-mortem recession; pulse, 110, 84, 150; respiration, 34, 30, 46.

Lesions.—Three fissures originated in the left squamous portion, one of which was open and traversed the whole length of the anterior surface of the petrous portion, dividing in the middle portion into two branches, one terminating in the sphenoidal fissure, and the other in the posterior fossa; skull thin; epidural clot in temporal region; moderate pial hemorrhage over lateral aspect and base of left temporal region; laceration of second right temporal convolution; small cloudy subarachnoid serous effusion; general hyperæmia of the brain substance with minute thrombi, and excessive œdema, which involved the pons, medulla, and basal ganglia; two or three punctate extravasations in the centrum ovale.

CASE CXIX. *Symptoms.* — Patient fell six stories through an elevator shaft; extreme shock. Primary and permanent unconsciousness; hemorrhage from right nostril and mouth; large hæmatoma in right frontal region; pupils contracted, the left more completely than the right. Temperature on admission to the hospital, 97.2°, and rose progressively to 102.2° with immediate post-mortem increase to 102.5°. Death occurred soon after examination and dressing of the wounds.

Lesions.—Wound of elbow-joint and compound fracture of leg; open fissure of right frontal, extending through orbital process into body of sphenoid bone; no epidural hemorrhage; no laceration; general pial hyperæmia and œdema, and pial hemorrhage posteriorly; limited contusion, in an area of one and one-half inches in diameter, of right frontal lobe laterally.

CASE CXX. *Symptoms.*—Patient fell thirty-five feet to the ground; extreme shock. Transient unconsciousness; pupils contracted; respiration frequent, and became stertorous and flagging in the ambulance. On admission to the hospital consciousness again lost; large hæmatoma in each parieto-occipital region; no hemorrhages; right facial paralysis; right forearm strongly flexed, rigid, and fingers twitching; left forearm slightly rigid and flexed; within the first hour convulsive movements every ten minutes, in which the left arm was drawn in toward the chest, and both legs were rigid and extended; patellar reflexes increased; right pupil dilated, and the left concontracted; face cyanotic; respiration became of the Cheyne-Stokes character; stertor and moist bronchial râles. Temperature, 96.4°, rising progressively to 100° at time of death twelve hours after admission; pulse, 62, 60; respiration, 32, 20, 28; one large unconscious urinary evacuation.

Lesions.—Linear fracture ran from posterior part of right parietal bone downward and forward through petrous portion to groove for middle meningeal artery; a second linear fracture extended from the middle of superior curved line of the occipital bone through posterior fossa to jugular foramen; epidural hemorrhage from rupture of posterior branch of right middle meningeal artery; three ounces of fluid blood and a clot one inch in thickness at point of rupture; laceration of right temporal lobe, small; cortical hemorrhage upon lateral aspect of parietal and temporal lobes; general contusion confined to right lobe.

CASE CXXI. *Symptoms.*—Patient found unconscious beside his truck. On admission to the hospital, thirty minutes later, pulse, 80, respiration irregular, and temperature, 97.4°; right pulse fuller than left; no hemorrhages; no muscular symptoms; large hæmatoma just above left ear; left pupil widely dilated, right moderately contracted, and both insensible to light. Incision

disclosed depressed fracture of left squamous portion, with free hemorrhage from open fissures. At the end of thirty minutes the right pupil began to dilate and left facial paralysis was appreciable; fifteen minutes later there were abduction and internal rotation of both thighs with extension of the legs, and in ten minutes more there was flexion of forearms with adduction of the arms. The right pupil became fully dilated, the breathing very irregular, and death occurred one and one-half hours after admission. The final temperature was 98.6°, and thirty minutes post mortem had risen to 109°. This observation was carefully verified by Dr. M. W. O'Gorman, House Surgeon.

Lesions.—Multiple linear fracture of left squamous portion; one fissure ran forward through floor of middle fossa to border of sphenoid body, rupturing anterior branch of left middle meningeal artery; epidural clot compressed lateral surface of left temporal and parietal lobes, making them concave, and also inferior temporal surface. The clot, which was one and one-fourth inches in thickness and very firm, extended nearly to the median line at the vertex and upon the lateral surface of the occipital lobe; no other hemorrhage, and no laceration or limited contusion of the brain; pial vessels moderately injected, and no subarachnoid effusion or pial œdema. All parts of the brain were moderately and equably hyperæmic, without punctate extravasations or minute thrombi. The whole brain, inclusive of the cerebellum and basal ganglia, was excessively œdematous; the ventricles were dry when first exposed, but became in part filled with serum by exudation from the cut cerebral surfaces.

CASE CXXII. *Symptoms.*—Patient fell three stories; primary and permanent unconsciousness; hæmatoma in left parietal region and at vertex; hemorrhage from left ear and nose; right radial pulsations fuller and stronger than left; right pupil dilated; no muscular symptoms;

skin cold and moist. Temperature, 98.2°; pulse, 68; respiration, 14. Death in one and one-half hours.

Lesions.—Separation of coronal suture through its whole length, with fissure in continuity running through right orbital plate, body of sphenoid bone, and floor of middle fossa, and separating the last from petrous portion, which was also involved; multiple fissures of right greater wing of sphenoid; small epidural hemorrhage on right side; pial hemorrhage over whole of right and anterior half of left hemisphere; multiple limited contusions of superior surface of both frontal lobes, and of left occipital lobe; laceration of whole inferior surface of right temporal lobe; small laceration of inferior surface of right frontal lobe. Brain excessively hyperæmic, with numerous punctate extravasations.

CASE CXXIII. *Symptoms.*—Patient struck by a falling wall; both nasal and superior maxillary bones fractured; hemorrhage from mouth and both nostrils; face emphysematous; semiconsciousness; left pupil slightly dilated and irresponsive to light; no muscular symptoms, no loss of fæcal or urinary control, and radial pulsations symmetrical. Temperature, 100.6°, rose progressively to 105.4°, with post-mortem elevation to 105.6°; pulse, 100, 74, 138; respiration, 20 to 34.

Lesions.—Cribriform plate and crista galli detached from the ethmoid body and pushed upward by the violent displacement of the nasal bones, lacerating the anterior perforated space in the median line to a depth of three-eighths of an inch; small cortical hemorrhage; no other laceration or hemorrhage; general hyperæmia, without much œdema, of the brain substance.

CASE CXXIV. *Symptoms.*—Primary and permanent unconsciousness; hemorrhage from right ear, and profuse from mouth; hæmatemesis; right pupil dilated but responsive to light; left radial pulsations stronger than the right; no muscular symptoms. Temperature, 96.8°; pulse, 94; respiration, 40.

Lesions.—Separation of coronal suture and an open fissure in continuation, crossing the groove for the right middle meningeal artery and the middle of the petrous portion into the posterior fossa; large epidural hemorrhage, flattening the right hemisphere, from rupture of the trunk of that vessel; slight pial hemorrhage on the right side posteriorly; excessive hyperæmia and œdema of all parts of the brain.

CASE CXXV. *Symptoms.*—Patient struck upon the head with a piece of board; conscious and walking about when first seen by the ambulance surgeon; condition alcoholic. Wound in the left temporal region then sutured, and consciousness suddenly lost immediately afterward and not regained; both pupils contracted; general muscular twitching. On admission to the hospital, complete coma; stertor; temperature, 97°; pulse, 50; respiration, 8, and subsequently of the Cheyne-Stokes character; left pupil dilated, and at a later period contracted. Two hours later twitching of the muscles recurred in the right arm, and was followed by general paralysis, including that of both sides of the face with divergent strabismus; urine ret ined. Death in eleven hours. Temperature three hours after admission, 99.8°; pulse, 54; respiration, 22; seven hours after admission, temperature, 101°; pulse, 56; respiration, 26; in ten hours, temperature, 102°; pulse, 58; respiration, 26; and in eleven hours, temperature, 104°; pulse, 68; respiration, 22. Temperature thirty minutes post mortem, 106°.

Lesions.—Fine fissure beginning at a point one-half inch in front of the middle portion of the left half of the coronal suture, crossing the groove for the middle meningeal artery, and terminating in the floor of the left middle fossa; short indirect fissures in both orbital plates, punctate extravasations in the left petrous portion, and general hyperæmia of the left middle fossa; no epidural or cortical hemorrhage, and no cerebral laceration; pial hemorrhage covering the left hemisphere, the clot very thick in the

midparietal region, and a separate pial extravasation thinly covering the inferior surface of the cerebellum; no hemorrhage upon the inferior cerebral surface; cortical contusion of the third right temporal convolution in its middle

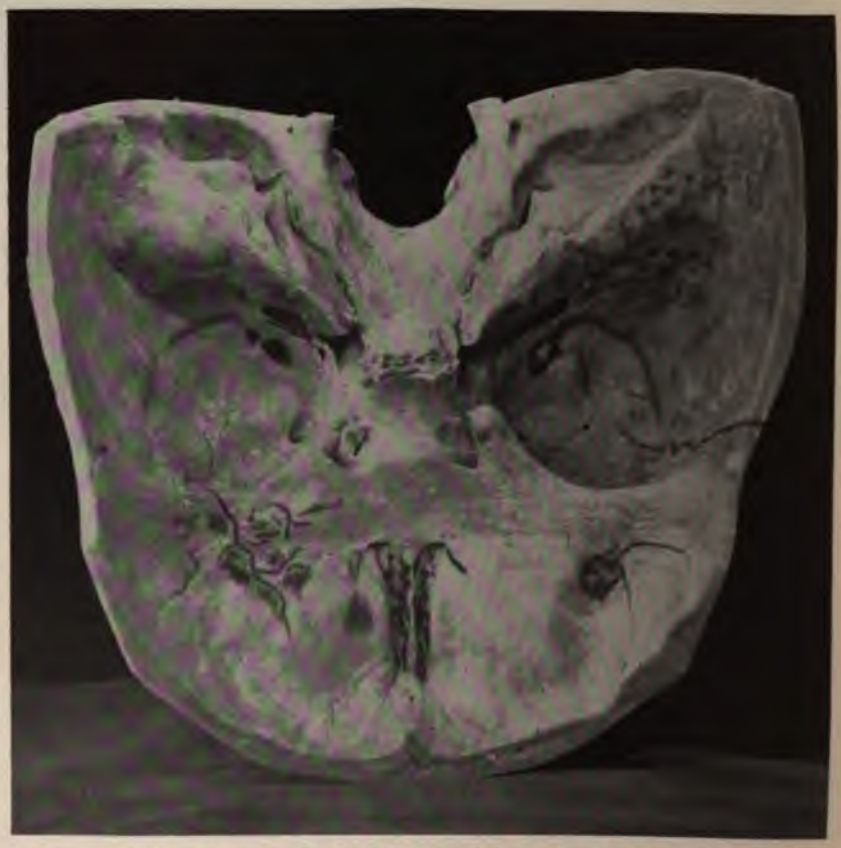

FIG. 45.—Indirect Fractures of Orbital Plates, and Contusion of Petrous Portion and Middle Fossa, with Direct Fracture of Base and Vertex.

part; minute contusions of inferior surface of the left temporal lobe and of the first right orbital convolution; moderate hyperæmia and excessive œdema of all parts of the brain.

CASE CXXVI. *Symptoms.*—Patient struck by an unknown instrument just below the left ear, inflicting two

wounds, which had bled profusely. On admission to the hospital he was not wholly conscious, but could be aroused sufficiently to recognize and curse his wife. Temperature, 97.6°; pulse, 78; respiration, 28; deep lacerated wound below left ear, and superficial wound over left mastoid process; no paralysis; loss of fæcal and urinary control. In fourteen hours restlessness and muttering delirium, and in eighteen hours paralysis of the whole right upper extremity, which on the second day extended to the right side and lower extremity, and at the end of forty-eight hours to the right side of the face; pupils insensitive to light. Death occurred at the end of four days; consciousness entirely lost on the second day; right patellar reflex increased; left normal; abdominal and cremasteric reflexes lost; lack of fæcal and urinary control continued. Temperature, 97.6° on admission; declined to 96.8° in two hours, and rose to 98.8° in five hours; then remained at 101°+ till the last day, when it rose to 103.4°, 104.2°, with immediate post-mortem recession; pulse, 78 to 136; respiration, 20 to 56.

Lesions.—Fracture and partial dislocation of second cervical vertebra; no lesion of spinal cord. No fracture of skull; no epidural hemorrhage; no laceration of brain. Large pial hemorrhage covering left hemisphere; limited central contusion of left occipital lobe, oval, well defined, and markedly softened; some punctate extravasations in posterior part of same lobe; moderate general hyperæmia and œdema.

CASE CXXVII. *Symptoms.*—Patient struck upon the head by a falling timber; primary and permanent unconsciousness. On immediate admission to the hospital, hemorrhage from left ear and nostril and from mouth; pupils moderately dilated, and radial pulsations symmetrical; no muscular symptoms. Temperature, 98.2°; pulse, 58; later, 52; respiration, 5. Death in thirty minutes from time of injury. Respiration was five in the minute from first observation made by the ambulance sur-

geon before admission, and was not more than three *in articulo mortis;* each act was of an explosive character.

Lesions.—Necropsy four hours post mortem. Large scalp wound above left ear, and flap raised from temporal fascia; right half of coronal suture separated, with continuous open fissure beginning at median line and extending through left middle fossa and middle of petrous portion into foramen magnum; a branch of this fissure ran from the middle fossa through the sphenoid body; thick clot covered the whole vertex; no epidural hemorrhage; well marked contusion, with softening and punctate extravasations, of the middle portion of the second left temporal convolution; no cerebral laceration; fluid blood covered the whole brain surface and was in large quantity in the middle and posterior basic fossæ; general hyperæmia of the brain and excessive œdema, with punctate extravasations in both corpora striata and in the optic thalamus.

CASE CXXVIII. *Symptoms.*—Primary and permanent unconsciousness following a fall of twenty feet; stertor, left subconjunctival hemorrhage with œdema of the lids, slightly dilated pupils, hæmatoma in left parieto-occipital region, radial pulsations symmetrical, and no muscular derangements. On admission to hospital, face very cyanotic with occurrence of severe paroxysms of coughing and choking; thirty minutes later, temperature, 94.2°; pulse, 76; respiration, 24; moderate hemorrhage from left nostril, breathing very noisy, and vomiting which endangered life by reason of paralysis of the pharyngeal muscles; five hours later still, left radial pulse small and rapid, right full and slow; right pupil dilated, left contracted; breathing still noisy; no change in condition till death at end of twelve hours. The temperature rose progressively to 105.4°, with post-mortem recession in thirty minutes to 105°; pulse, 64 to 94; and respiration, 28 to 30.

Lesions.—Linear fracture extending from left posterior parietal region through middle fossa into orbital plate;

large epidural hemorrhage covering cerebral vertex and base in left parietal and frontal regions; laceration of both temporal lobes inferiorly and laterally; cortical and pial hemorrhages over whole vertex and extending into middle and posterior fossæ; excessive general hyperæmia and œdema of the brain substance.

Fractures of the Cranial Base from Pistol-Shot Wound.

Case CXXIX. *Symptoms.*—Consciousness lost but regained before admission after suicidal pistol-shot wound of the head; total loss of vision; exophthalmia of both eyes; dilatation of both pupils, which were irresponsive to light; temperature, 100.2°; pulse, 60; respiration, 20. Ophthalmic examination by Dr. P. A. Callan on the second day disclosed only patches of retinal hemorrhage; mental condition unimpaired; sense of smell entirely lost. On the fourth day an unsuccessful attempt was made to extract the ball, and a drainage-tube was carried from the foyer of entrance through both frontal lobes to a cranial opening made upon the opposite side; followed for five days by discharge of brain tissue, and then till death by pus in increasing quantity. Mental condition normal till the fifth day, sluggish till the ninth day, and afterward marked by increasing delirium, which lapsed into a muttering stupor at the end of life on the thirteenth day. Temperature at time of operation, 99°; rose to 103.6° in ensuing twenty-four hours, and then varied from 102.4° to 104.5° on the last day; pulse and respiration nearly normal till just before death.

Lesions.—Ball penetrated external wall of right orbit, just behind external angular process; passed beneath optic nerve, comminuted inner wall of orbit, crista galli, cribriform plate, and lesser wing of sphenoid; entered left orbit through inner wall, and was found beneath left optic nerve. In the cranial cavity its course was

beneath both optic nerves. Subarachnoid purulent effusion covered both frontal lobes, more copious on left side and at base; left frontal lobe excavated, and filled with pus and brain detritus. Pus also existed in the track of the drainage tube through the right frontal lobe.

CASE CXXX. *Symptoms.*—Pistol-shot wound; immediate unconsciousness: rapid and feeble pulse; sighing respiration; profuse hemorrhage from wounds of entrance and exit. Death within an hour.

Lesions.—Pistol-shot fracture of right frontal bone through temporal fossa; ball grazed the outer and posterior part of the orbital plate and fractured the right lesser wing of the sphenoid, grooved the inferior surface of both frontal lobes just anterior to the fissures of Sylvius, destroying the cortex and subcortex for a space three-fourths of an inch in width, and emerged through the left temporal fossa at a little higher level than the point of entrance. The vertex and base were fissured from the point of exit, and the coronal and biparietal sutures divulsed and widely separated. The whole surface of the brain was covered by a thin subarachnoid hemorrhage, which was partly cortical and partly pial. The brain substance generally was markedly hyperæmic and its minute vessels were filled with coagula. The corpora striata and optic thalami, especially the striata, were much contused, their substance studded with punctate extravasations, and their vessels distended with thrombi. The pons, medulla, and cerebellum were but slightly altered.

CASE CXXXI. *Symptoms.*—Pistol-shot wound through right temporal fossa; cutaneous opening small and circular; consciousness permanently lost; pupils dilated, the right slightly the larger; left corneal reflex absent; urine retained; some pulmonary œdema; temperature on admission, 96.4°, and from 96.8° to 96° for five hours, then declined to 95.6°; pulse on admission, 85—subsequen from 94 to 80; respiration on admission, 14—for an ho and a half, 12; in two hours and a half, 10; in three ho

8; in four hours and a half, 6; in five hours, 4; and *in articulo mortis*, a few moments later, 2. Cardiac action continued three minutes after respiration ceased.

Lesions.—Ball entered the cranial cavity, severing the trunk of the middle meningeal artery, passed through the third right temporal convolution, and was lodged in the posterior part of the inner border of the right temporo-sphenoidal lobe. A small piece of bone, driven in advance of the ball, was found between the right lateral columns of the medulla. A large arachnoid clot, probably in part epidural and in part cortical, filled the middle fossa, spread over the whole right hemisphere, and thickly covered the pons and medulla. Hyperæmia of the right hemisphere and basic ganglia was of considerable intensity.

CASE CXXXII. *Symptoms.*—None; patient found dead.

Lesions.—Large lacerated pistol-shot wound in right temporal region; temporal muscles burned and disintegrated for some distance from the cutaneous opening. The ball passed through both frontal lobes, comminuted both orbital and intervening cribriform plates, and emerged through left temporal fossa. The calvarium was separated from the supraorbital ridges and broken into large loose fragments in its anterior portion.

CASE CXXXIII. *Symptoms.* — Suicidal pistol-shot wound; ball entered just below the right ear and in front of the mastoid process, and was lodged in the petrous portion of the temporal bone; removed on the following day; delirium and rise of temperature on the sixth day, flexion of the right leg on the thigh on the eighth day, and death on the fourteenth day.

Lesions.—Fracture of anterior surface of the right petrous portion, epidural and cortical hemorrhage at that point, pial hemorrhage over left occipital lobe and left motor area, and laceration of the temporo-sphenoidal lobe at the site of fracture.

CASE CXXXIV. *Symptoms.*—Suicidal wound through the anterior cervical region; ball of 0.38 cal. entered in

the median line over the larynx; no hemorrhage from the wound or mouth; immediate partial aphonia; deglutition of liquids only possible, and with difficulty; hemorrhage from the left ear. On the third day, deglutition impossible and mental condition stupid; followed by delirium requiring mechanical restraint on the fourth day, and on the fifth day by paresis of right arm, hand, and lower extremity, and loss of fæcal and urinary control, with some improvement in voice and power of deglutition. On the sixth day there was added right facial paralysis with ptosis; the right pupil was dilated and the left contracted, and the urine was controlled. The temperature on admission was 100°, rose on the second day to 101°, on the third day to 102.4°, and on the fourth day to 103.6°; later it attained an elevation of 107.6°. The pulse was from 70 to 86 till the fourth day, when it rose to 132. The respiration was normal for four days and became frequent only at a late period. Death occurred on the seventeenth day.

Lesions.—Bullet was lodged in the apex of the left petrous portion; small fragment of bone driven upward about an eighth of an inch; no lacerations; large pial hemorrhage, in greatest amount over left fissure of Rolando; large subarachnoid serous effusion.

CASE CXXXV. *Symptoms.*—Patient found dead.

Lesions.—Right pupil moderately dilated, the left normal. External wound behind the external angular process, one and one-half inches in length, linear, and its lower border retracted three-fourths of an inch and slightly torn, exposing the blackened and lacerated muscular tissue below the temporal fascia, and its edges burned. There was no ingraining of the skin with powder, no burning, and no smoke stain; no free grains upon the surface. The subcutaneous blackened area was one and three-fourths inches in diameter, and was entirely below the temporal fascia. The osseous entrance was large, circular, and finely fissured, and was situated in the temporal fossa at the level of the zygoma. The ball of 0.38 cal. passed

through both temporal lobes in their inferior portion, severing the pons anteriorly, and made exit through the left squamous portion, which with the petrous portion was much comminuted. The ball was found among the bony fragments. The brain substance was hyperæmic and œdematous, and its vessels contained minute thrombi. Unburned grains of powder were found in the right temporal lobe.

CASE CXXXVI. *Symptoms.*—None recorded; patient died in the ambulance.

Lesions.—Both pupils widely dilated. Ball entered through left upper eyelid; brain matter in external wound; widely scattered grains of powder embedded over whole left side of face, from chin to margin of hair, and a few in right cheek and upper eyelid; no burning of the skin; wound contused and edge lead stained; one or two fragments of lead in muscle of eyelid. The osseous entrance involved the supra-orbital ridge and the ball in its course carried away the inner fourth of the orbital plate. The ball passed through the left frontal and parietal lobes to the parieto-occipital junction and was lodged in the cortex at the vertex. No powder grains were discoverable in the brain track, and only two or three fragments of bone, which were found in the prefrontal lobe. The whole surface of the brain was covered with blood, mainly fluid, and a clot one-fourth of an inch in thickness compressed the pons and anterior part of the medulla; brain substance hyperæmic and œdematous; heart contracted; lungs œdematous.

CASE CXXXVII. *Symptoms.* — Bullet of 0.38 cal. entered the forehead a little to the left of the median line, about two inches above the glabella; no superficial lesions; edge of the wound blackened; primary and permanent unconsciousness; stertor; projectile vomiting, which ceased on admission to the hospital; arms flexed and drawn across the chest, and thumbs and fingers clenched; occasional spasmodic movements of the shoulders; eight hours

later two or three general convulsions; pupils symmetrically contracted; final pulmonary œdema and death in sixteen hours. Temperature on admission, 97.8°; pulse, 52; in five hours, temperature, 98°; in eight hours, 98.2°; and in sixteen hours, 101°, with immediate post-mortem increase to 101.4°.

Lesions.—The lower margin of the osseous wound was one and one-half inches above the glabella, and was three-fourths of an inch in diameter in the outer and one inch in the inner table; bone very thick and not fissured; two indirect small stellate fractures in the right orbital plate, one near the ethmoid margin and one near the lesser sphenoidal wing; another indirect stellate fracture in the left orbital plate with a long fissure extending toward its outer part. The bullet entered the superior median fissure of the brain, lacerating both frontal lobes, traversed the right hemisphere just below the cortex, and rested upon the surface of the right occipital lobe near the median line; dura mater and bone uninjured; track filled with blood; six osseous fragments driven into the frontal lobes; fornix contused; cortical hemorrhage thickly covered both hemispheres and filled the frontal sulci; pia mater exceedingly hyperæmic.

CASE CXXXVIII. *Symptoms.*—Patient admitted to hospital immediately after the infliction of a pistol-shot wound three-fourths of an inch above, and one-fourth of an inch behind, right external angular process. The wound was one-fourth of an inch in diameter, circular, patulous, lacerated, and having its margin burned to the width of one-eighth of an inch. The skin was denuded by blistering in an area of one and one-fourth inches by three-fourths of an inch anteriorly, and in another area of three-fourths of an inch inferiorly. There was a smoke stain of two inches antero-posteriorly by one and one-half inches vertically. No free or embedded unburned grains of powder were visible, and there was no brain matter in the wound. The exit was two inches in diameter, and was

two and one-fourth inches above the left ear, and lacerated, everted, and containing brain substance. The temperature was 101°; pulse, 60; and respiration, 5; skin pale but warm and flushing at times; profound unconsciousness, which continued till death; right pupil dilated, left contracted, and both irresponsive to light; ecchymosis of both eyes, and œdema of both conjunctivæ; eyes bulging and pulsating on palpation; pulse slow, full, compressible, and intermittent; respiration deep, stertorous, and its rate five in the minute when quiet, but twenty or more when disturbed; loss of urinary control; convulsions involving upper extremities, and at times general; three in the first hour, and two subsequently; hemorrhage from nose, mouth, right ear, and from wounds of entrance and exit. Both pupils became dilated. The temperature rose progressively in six hours to 106°, and then declined to 103.2° at death two hours later; the pulse increased to 124, and the respiration at the end of the first hour was 36, and did not become less frequent afterward. The heart continued to pulsate for three minutes post mortem.

Lesions.—Both pupils dilated. Superficial fascia separated about wound of entrance from the fibres of a very thick occipito-frontalis muscle, which was blackened over an area of one inch anteriorly, and of one-half inch posteriorly; ball track concealed in the substance of an enormously thick temporal muscle, which contained grains of unburned powder; hæmatoma of the left side of the head, and hemorrhage into both temporal muscles; osseous entrance circular, and not comminuted or fissured; contiguous surfaces of calvarium and dura mater powder stained over an area of one inch; cortical hemorrhage over the whole of left hemisphere, which had reached the arachnoid cavity and filled all the basic fossæ; clot upon the right side of the pons, and detached coagula upon the right side of the medulla. The ball in its passage had fractured both orbital plates and the body of the ethmoid, and the orbital vessels were surrounded by a thick clot, which ex-

tended into the orbital connective tissue. The brain was extensively lacerated in the track of the ball, which was of 38 cal.; the parts involved were the inferior portion of the anterior half of the right temporal and of the posterior half of the right frontal lobes, and the greater portion of both corpora striata, and rather less of the left temporal and frontal lobes. The posterior margin of the laceration on the right side was bordered by an area of localized contusion with punctate extravasations. There was much comminuted bone in the right side of the brain, but disintegration was too complete, and hemorrhage too great, to determine the existence of grains of powder. A cylindrical clot, the size of a goose quill, extended from entrance to exit, which was just above the left fissure of Sylvius, and externally two inches above the ear. The brain substance was moderately hyperæmic, with thrombi in the minute vessels.

CASE CXXXIX. *Symptoms.* — None; subject found dead.

Lesions.—Entrance of ball circular, and one-half inch behind right external angular process; diameter one-eighth of an inch; moderate hemorrhage over side of face and ear, which had remained undisturbed; no trace of smoke or of brain spatter; no unburned grains of powder, either free or embedded; edge of wound burned, and a circular burned area, seven-eighths of an inch in diameter; skin black, smooth, and like parchment; included in a scorched area of one and seven-eighths inches by one inch; pupils symmetrical and slightly contracted; large extravasation of blood in the deeper layers of the scalp over the frontal and parietal regions. The ball entered the cranial cavity through the floor of the right middle fossa just beneath the lesser wing of the sphenoid bone, passed through the left lateral ventricle, and the left parietal lobe just above the horizontal fissure of Sylvius, fractured the parietal bone below the parietal eminence, everted its fragments, and rested in the osseous wound. There was a powder stain

in an area of three-eighths of an inch in diameter below the temporal fascia. The brain track was three-fourths of an inch in width, and contained no visible grains of powder or fragments of bone. There was moderate cortical hemorrhage over the right hemisphere and base of the brain, and moderate general cerebral hyperæmia.

CASE CXL. *Symptoms.*—None recorded; died while being taken to the ambulance.

Lesions.—Cutaneous entrance one-eighth of an inch in diameter, three-fourths of an inch above right external angular process; no smoke stain, no brain spatter, no unburned grains of powder upon the surface; eyebrow and subjacent skin slightly scorched; an area of sparsely embedded powder grains, seven inches by six inches, over the ear, side of the forehead and face, including the nose as far as the line of the nostril; one or two grains in the conjunctiva, and two in the neck; only moderate external hemorrhage, and subcutaneous hemorrhage, in an area of one inch in diameter, above and below the temporal fascia; pupils normal. The ball penetrated the cranial cavity just above the right orbital plate, passed obliquely backward from the anterior extremity of the right fissure of Sylvius, across the frontal lobe and through the tip of the left temporal lobe, making a furrow in the cerebral cortex three-eighths of an inch in depth, which contained no appreciable grains of powder or fragments of bone; no epidural hemorrhage; cortical hemorrhage in moderate amount over right hemisphere, but in greater quantity at the base; pons and medulla covered with clot; moderate cerebral hyperæmia with minute thrombi. The osseous exit was one inch behind the left external angular process of the frontal, and comminuted the squamous portion of the temporal bone in a space one inch in diameter; it also fissured the external portion of the left orbital plate and the floor of the middle fossa. The cutaneous exit was one-fourth of an inch in diameter, and slightly lacerated, with moderate hemorrhage above and below the temporal fascia.

Case CXLII. *Symptoms.*—None; death immediate.

Lesions.—Ball entered the mouth, penetrated the le
palate process of the superior maxilla and body of th
sphenoid bone anteriorly, entered the cranial cavi
through the superior sphenoidal surface without comm
nuting the bone, traversed the left frontal lobe, left later
ventricle, and left parietal lobe, fractured the parietal bo
near the median line, and fell back beneath the cortex.
small triangular piece of the parietal bone was elevate
and covered by a hæmatoma of the scalp. The bra
track was nearly vertical, inclining a little backward, o
half inch in width, and containing no evident unburn
grains of powder or fragments of bone. The brain su
stance was moderately hyperæmic. The ball was of o
cal. The pupils were very slightly dilated.

Case CXLIII. *Symptoms.*—Patient found unconsci
and breathing heavily; death occurred soon afterward.

Lesions.—Both pupils dilated; hemorrhage from mo
and left nostril and from a wound one and one-half inc
behind right external angular process. Cutaneous wo
was circular, one-half inch in diameter, with its ed
burned, and contained brain matter. There was no bu
ing of the skin, smoke stain, or unburned grains of p
der upon the surface. There was a large hæmatoma
the right fronto-parietal, and another in the left pari
region. The temporal fascia was blackened, and also
area one inch in diameter in the temporal muscle.
osseous entrance was circular, and a fissure exten
from it through the frontal bone just above the r
supra-orbital ridge, into the left orbital plate, which
comminuted. The ball passed through both frontal l
and the left parietal lobe, fractured the bone about
parietal eminence, and dropped back to a point just
neath the cortex. An osseous fragment one inch sq
was elevated but not detached, and was covered by the
parietal hæmatoma previously noted. The ball trac
large size, in the right frontal lobe contained some fi

comminuted bone and one or two appreciable grains of powder, and showed a bluish stain. There were only a slight cortical hemorrhage and moderate general hyperæmia. Ball of 0.32 cal.

CASE CXLIII. *Symptoms.*—Homicide; woman, aged twenty-nine years, shot twice in the head at short range; no loss of consciousness. On immediate admission to the hospital, mental condition normal; pain in head and neck; wound one and one-half inches above, and a little behind, left external angular process, with area of finely ingrained powder three-fourths of an inch in diameter; no burn of hair or skin; subcutaneous tissues blackened in area of three-fourths of an inch through temporal muscle; bullet of 0.32 cal. extracted from the surface of temporal bone; second wound two inches below and a little behind left mastoid process, in which the bullet could not be detected by the probe. For four days there were no symptoms of importance. Pain in the head was confined to the neighborhood of injuries, and was attended by stiffness of the neck and some discharge from the posterior wound. Vomiting, which occurred from time to time, was notable only on the fourth night, when it was frequent and the matter vomited contained mucus and a greenish fluid. There was no vomiting later, and the bowels were moved only by enema till just at the end of life. On the fifth day temperature rose from 101°+ to 104.4°, and on the sixth was 103.8°–104°, though the patient felt well. On the seventh day slight delirium was continuous with a throbbing sensation in the head, and the temperature in the early morning fell to 102°–102.8°. The pulse in this time had only twice exceeded 100. From the eighth to the eleventh days inclusive, delirium was constant but not violent, urinary control was lost, and there was but little discharge from the wounds; the temperature varied from 105° to 102.6° and the pulse from 110 to 132. On the twelfth day there was less delirium, and some rational response to questions; temperature fell to 101.4°. On

the thirteenth day, flushing of the face, drowsiness, and continued lack of urinary control, with temperature of 103.8°–104°. On the fourteenth day a bullet was detected in the posterior wound and a fragment removed; temperature, 102°+–102°. On the fifteenth day the patient was semi-conscious and the bowels moved continuously without control; temperature, 103°+. On the sixteenth day

FIG. 46.—Depression of External Table with the Anterior Wound.

complete unconsciousness, muscular twitchings in all the extremities; temperature, 103.8°–104.6°. On the seventeenth day, temperature 108° to 109.4° at the time of death, with post-mortem recession in thirty minutes to 109°.

Lesions.—Ingrained powder had been washed out from the skin about the wound in the temporal region by the use of dressings in the progress of the case; depression in the left temporal bone immediately below the temporal ridge in its anterior portion (Fig. 46), which was filled

with pus; inner table comminuted and depressed in an area of three-fourths of an inch (Fig. 47); skull very thick. The bullet, which entered the posterior cervical region, was found loosely embedded in the bone of the left basic fossa, with its anterior extremity covered by fragments of the inner table projecting into the cranial cavity near the foramen magnum (Figs. 48, 49). No meningeal effusions; cerebral

FIG. 47.—Comminution of the Inner Table with the Anterior Wound.

surface notably dry; no intracranial hemorrhages; contusion of brain in middle of third left frontal convolution, one-half inch in diameter, at site of anterior osseous depression; another contusion of the same diameter in the centre of inferior surface of left cerebellar lobe, corresponding to side of posterior osseous depression; both sharply limited and confined to cortex; moderate general hyperæmia and œdema.

CASE CXLIV. *Symptoms.*—None noted; death in a few moments.

Lesions.—Ball of 0.32 cal. entered one-half inch behind and one-eighth inch below right external angular process; not much external hemorrhage; black area of five-eighths inch diameter in a smoke area of one inch diameter; external wound one-eighth inch diameter; no subcutaneous hemorrhage; funnel-shaped black area in temporal muscle one-half inch diameter at temporal fascia;

FIG. 48.—Direct Fracture of Base with the Posterior Wound. External Table.

osseous wound one-fourth inch diameter in temporal bone just above level of zygoma, circular, and without fissuring or comminution; small osseous fragment lying upon the dura mater; ball passed through fissure of Sylvius, diagonally across basal surface and through posterior part of left temporal lobe nearly to cortex, and then backward through posterior part of lateral ventricle to a lodgement in the posterior and external part of the occipital lobe beneath cortex. The ball in its basilar course de-

tached clinoid processes and dorsum ephippii; osseous fragments in right fissure of Sylvius and in left temporal lobe; large cortical hemorrhage over whole vertex and in central basic region.

CASE CXLV. *Symptoms.* — Patient admitted to hospital two days after reception of injury; semi-conscious without pain, and irritable; he spoke very slowly but cor-

FIG. 49.—Direct Fracture of Base with the Posterior Wound. Inner Table.

rectly, and was without motor symptoms. There was extensive ecchymosis of both eyes, but the pupils were normal, and there was no subconjunctival hemorrhage; increasing stupor and final coma. Temperature, 106.2°. Death in twelve hours.

Lesions.—The ball passed through the right malar bone at the root of the zygomatic process, and transversely through both frontal lobes, fracturing both orbital plates and cutting off the crista galli, and lodged in an osseous depression opposite its point of entrance. Fissures ex-

tended from both orbital plates, converged, joined, and extended to the coronal suture. Both prefrontal lobes were disintegrated; there was no epidural hemorrhage and no burning of the skin. The ball was of 0.32 cal.

CASE CXLVI. *Symptoms.*—Suicidal wound inflicted during a paroxysm of alcoholic mania. Ball of 0.22 cal. entered the right ear at contact; consciousness retained; a single mouthful of blood ejected soon afterward; no ingrained powder; epidermis removed from about one square inch of surface in front of the ear; membrana tympani perforated; no general symptoms. Through a wound in the anterior wall of the meatus a probe could be passed three-fourths of an inch inward and a little forward upon the cranial base; this opening was too small to have been made by the bullet. Three days afterward the right side of the face became inflamed, with the occurrence of frontal headache, a more profuse sanguinolent discharge from the ear, and an elevation of temperature to 102.6°; this was followed by transient delirium of a low grade, and by an early subsidence of symptoms. On the eighth day the discharge from the ear became fœtid and the patient somnolent. An examination of the ear by Dr. Callan disclosed only the discharge of pus from the tympanic wound; an examination of the eye afforded negative results. After this time a considerable swelling over the ramus of the jaw, and a free discharge of pus through the tympanum, were continued without other symptoms until the accidental discharge of the patient from the hospital at the end of a month. It was learned that he was apparently well for some days; that the discharge from the ear then ceased; that he had headache, chills, and rapid deterioration of his general health; and that he died suddenly shortly afterward.

FRACTURES CONFINED TO THE CRANIAL VERTEX.

CASE CXLVII. *Symptoms.*—Delirium on the second, and a convulsion on the fifteenth day after the original injury alone noted and signifiance not recognized. Late symptoms followed an operation for fractured patella with use of anæsthetic six months afterward; general convulsions on the succeeding day, with wild delirium, and temperature of 103°; the temperature and general condition became normal after twenty-four hours. One month later general convulsions recurred after another operative interference, and continued thirty-six hours, preceded by tonic spasm of affected (left) limb, and succeeded by delirium and death at the end of nine hours. Each convulsion was preceded by restlessness and wide dilatation of both pupils, and in about fifteen seconds began in the left face, extended to the right face, to the left extremities, and finally became general. Temperature rose in twenty-four hours from 101.1° to 104.8°, and afterward declined to 104°.

Lesions.—Extensive laceration of the right temporo-sphenoidal lobe, three and a half by one and a half inches in its diameters, involving almost the whole of the second and third, and a little of the first, convolutions; the whole lobe greatly atrophied, indurated, and pigmented. Circular laceration upon the anterior border of the right frontal, and another, an inch and a half in diameter, upon the inferior surface of the left frontal lobe, in the second and third orbital convolutions. These lacerations were all necrotic.

CASE CXLVIII. *Symptoms.*—Hæmatoma and linear fracture of left parietal region; unconsciousness, which was permanent; right facial paralysis, and rigidity of both arms and right leg; and twenty-four hours later paralysis and rigidity of right arm; paralysis of right leg probable. Temperature on admission, 102.6°; pulse, 96;

respiration, 36; later temperature, 105°. Death in thirty hours.

Lesions.—Epidural hemorrhage compressing laterally the whole left cerebrum; general hyperæmia and punctate extravasations.

CASE CXLIX. *Symptoms.* — Consciousness partially lost and soon regained; vomiting frequent; later, somnolence and coma. Temperature on admission, 100.2°; pulse, 48; temperature rose to 105.4°. Death in twenty-seven hours.

Lesions.—Compound comminuted fracture of right frontal bone; corresponding laceration of right frontal lobe, through subcortex nearly to lateral ventricle, with cortical hemorrhage extending over parietal region; slight pial hemorrhage over left occipital lobe; minute vessels filled with coagula in all parts of the brain.

CASE CL. *Symptoms.* — Coma; stertor; pulse and respiration slow; second day—right hemiplegia; eyes deviating to the right; pupils normal; pulse feeble and rapid; respiration inadequate from pulmonary œdema. First temperature, some hours after admission, 101.6°; second day, 103.8° to 105.4°; third day, 106.4°. Death in sixty hours.

Lesions.—Laceration of left temporo-sphenoidal lobe extending into occipital region, with cortical hemorrhage over left motor area, and to base of occipital lobe; general hyperæmia and thrombosis.

CASE CLI. *Symptoms.* — Unconsciousness and irritability, which continued one week. Temperature, 99° to 100°; second and third weeks, delirium and continued irritability; fourth week, apathy, rambling speech, and delusions, after which patient was transferred to another hospital, where he died after operation.

Lesions.—Fracture in left occipito-parietal region; laceration of inferior surface of both frontal lobes.

CASE CLII. *Symptoms.* — Shock, conciousness re-

tained; restlessness and delirium; temperature, 100.2°; rose to 104.6°. Death on the third day.

Lesions.—Compound fracture of left frontal bone with corresponding laceration of brain and meninges; general hyperæmia and thrombosis.

CASE CLIII. *Symptoms.*—Unconsciousness; dilatation of pupils; rapid pulse and respiration; temperature, 100°. Death in four hours.

Lesions.—Deep laceration of inferior surface of right temporo-sphenoidal, and slight laceration of anterior border of left temporo-sphenoidal lobe; pial hemorrhage over superior surface of both hemispheres.

CASE CLIV. *Symptoms.* — Unconsciousness followed by delirium soon after admission; extensive wounds of the scalp; normal pupils, right becoming dilated a little later; temperature, 98.2°; in two hours, 99°; pulse, 76; respiration, 22; delirium increased: pulse and respiration unchanged. Death in four hours.

Lesions.—Compound doubly camerated fracture, involving right parietal eminence; skull very thick and unsymmetrical; posterior fossæ large, middle and anterior fossæ contracted; extensive pial hemorrhage, confined to meshes of pia, forming a thin sheet which covered superior and outer surface of right hemisphere and inferior surface of both occipital lobes; very marked general hyperæmia, especially on right side and in pons and medulla; some minute hemorrhages upon posterior border of right cerebellum and upon the medulla.

CASE CLV. *Symptoms.* — Temporary unconsciousness; no other primary general symptom; temperature on admission, 98.4°; second day, 100.6°; afterward, 99°+. On the tenth day, restlessness and slight delirium; eleventh day, slight chill and increased delirium, which became permanent, but of less active character; fourteenth day, post-cervical rigidity; and on the fifteenth, slight general convulsion; mental condition sluggish; pupils remained normal; respiration, 18 to 22:

pulse, 104 to 112. Temperature on the evening of the tenth day rose to 101° and on the eleventh day to 104.6°; it varied from that point to 103° till the fifteenth day, and then rose progressively and reached 107.4° on the sixteenth day, and death ensued.

Lesions.—Compound fracture with slight depression above right supra-orbital ridge, confined to external table; subarachnoid purulent effusion over both frontal lobes encroaching upon parietal and extending into median fissure.

CASE CLVI. *Symptoms.* — Unconsciousness, which continued till death at the end of three hours; general muscular rigidity. Temperature, 101°; pulse, 98; respiration, 20.

Lesions.—Penetrating wound and fracture of left temporal bone, above the ear, three-eighths of an inch in diameter, from a blow inflicted with a revolving screwdriver. The instrument passed through both hemispheres, wounding the dura mater upon the opposite side, and involving the posterior part of the left corpus striatum and both optic thalami; a thin cortical hemorrhage covered both hemispheres and the superior surface of the cerebellum.

CASE CLVII. *Symptoms.* — Patient, nine days previous to admission, came home with head bleeding, vertigo, nausea, and feeling of weakness, from an injury of unknown origin, and was said to have been afterward treated for pneumonia. On admission, he was found to have compound depressed fracture of right parietal bone, and the wound was foul and suppurating; mental condition stupid; left hemiplegia and right facial paralysis; deviation of tongue to the left; opposite radial pulsations symmetrial; slight dilatation of left pupil; coma supervened an hour later, and convulsive movements of the right face four hours and a half after admission. After elevation of the depressed bone, and escape of a small amount of pus from below the dura mater, the pupils became normal, and there was a single clonic convulsion

of the left side. Death occurred thirteen hours and a half from time of admission. Temperature for twelve hours was 106°+, and afterward 107.2°; one hour post mortem, 107.4°. Pulse, 118, 170, 158; respiration, 44 to 60.

Lesions.—Compound depressed fracture of right parietal bone, just behind coronal suture, and half an inch from median line; purulent subarachnoid effusion over convex surface of right hemisphere, which anteriorly extended to base; superficial laceration of right parietal lobe beneath site of fracture, which was prolonged subcortically, both anteriorly and posteriorly, but did not reach motor area; pus from this laceration had escaped in small quantity into arachnoid cavity; left hemisphere markedly hyperæmic and moderately œdematous.

CASE CLVIII. *Symptoms.* — Consciousness primarily retained; thirty minutes later general convulsions followed by complete unconsciousness and an apparently moribund condition. Elevation of a depressed portion of the left parietal bone restored consciousness and some strength to the circulation. Convulsions recurred next day, and death ensued in twenty-three hours. Temperature, 102.4° to 104.4°; pulse, 108 to 160; respiration, 32 to 60.

Lesions.—Fracture confined to vertex; epidural hemorrhage of small extent, and laceration of inferior surface of right frontal and temporo-sphenoidal lobes. (Infant, aged twenty-two months.)

CASE CLIX. *Symptoms.*—Patient admitted to the hospital semi-conscious, and without evident external injury; both arms rigid and extended; spasmodic movements of arms and feet; reflexes abolished. Pulse and respiration full and slow. Temperature, 99.8°. Pupils slightly dilated. Death in twelve hours.

Lesions.—Fracture of right temporal bone above the ear, laceration of the dura mater, and epidural hemorrhage.

CASE CLX. *Symptoms.*—Consciousness entirely lost, partially regained, and again entirely lost in the ambu-

lance, and not regained; pupils contracted, skin cold and moist; hemorrhage from both nostrils; large hæmatoma in right fronto-parietal region, and linear fracture discovered by incision; loss of urinary control, and vomiting. Some hours later the right pupil was more contracted than the left, there were muscular twitchings, and there was slight delirium. Second day: right radial pulsations were much fuller and stronger than the left; great difficulty in deglutition. Third day: unconsciousness was more profound and the left pupil slightly dilated; the right was still contracted. Death occurred in two and one-half days. Temperature on the first day was 99° to 100.6°; on the second day, 100° to 100.6°; on the third day, 100° to 105.8°, and receded post mortem. Pulse, 60 to 90, and on the third day, 70 to 120. Respiration, 36, 28, 66.

Lesions.—Hæmatoma over whole vertex; separation of coronal suture, and fissure in right parietal bone extending from it, which was discovered during life; large epidural clot over left parietal region, and another over right frontal region, both very black and friable; superior longitudinal sinus filled with very black firm clot; epidural clot in left middle fossa; rupture of longitudinal sinus; large pial hemorrhage over left frontal, temporal, and parietal lobes; no laceration of any part of brain substance; brain exceedingly hyperæmic and œdematous; moderate serous effusion in lateral ventricles.

CASE CLXI. *Symptoms.*—Unconsciousness lasting for a few moments; on admission to hospital, pupils and mental condition normal, contusion of scalp in occipito-parietal region, and vomiting. Temperature, 98.6°; pulse, 60; respiration, 15. Muscular twitchings of face, arms, and legs, which were of brief continuance. Two hours later irritability followed by delirium, and soon after by coma, which continued till death. Twelve hours later still, vomiting, loss of urinary control. Temperature, 101.4°; pulse, 74; and respiration, 20. Temperature rose progressively to 104°, and respiration to 42, at the

time of death in thirty-two hours. Loss of urinary control continued and bowels were not moved. The muscular twitchings recurred and the respiration became of the Cheyne-Stokes variety. Temperature one hour post mortem was 104.2°.

Lesions.—Linear fracture extending from the right parieto-occipital junction through the right squamous portion of the temporal bone; cortical hemorrhage covering the right hemisphere and a portion of the left, and at the base both lobes of the cerebellum and the pons; laceration, one-half inch deep and one-fourth inch wide, extending from a point in the parietal lobe corresponding to the origin of the fracture to the middle of the first right temporal convolution; no marked general cerebral hyperæmia.

CASE CLXII. *Symptoms.*—Transient unconsciousness. On admission to the hospital, compound depressed fracture of right frontal bone; vomiting; depressed fragments elevated, and open fissure discovered running into occipital bone; mental condition normal after recovery from ether. Second day: slight delirium, restlessness, followed by heaviness, somnolence, and loss of urinary control. Third day: restlessness, delirium, and stupor. Death occurred in fifty hours. The temperature on admission was 99°, and was little changed during the first day; on the second day it was 102°, 101°, 102.6°; and on the third day, 103°, 102.2°, 105.5°, with immediate post-mortem recession. The pulse was 98, 112, 93; the respiration was 20, 38, 28.

Lesions.—Open fissure extending from depression in the posterior part of right frontal bone into right superior occipital fossa; epidural hemorrhage over right hemisphere, very thick and firm upon its lateral aspect, originating from the diploic vessels; no other hemorrhage; cortical contusion of right parietal lobe near its lateral border, and another upon inferior surface of left temporal lobe; excessive general hyperæmia and œdema

of brain, and a small amount of clear serum in latera ventricles.

CASE CLXIII. *Symptoms.*—Patient fell upon the side walk; profound unconsciousness; wound in left parieta region; surface pallid, cool, and moist; pupils slightl dilated; respiration labored; left radial pulsations fulle and stronger than the right; no fracture discovered. Con sciousness was sufficiently restored after admission t hospital to permit answer to simple questions, and i fifteen minutes was again lost; head and eyes turned t the right; slight twitching of the right fingers; hemor rhage from the left nostril. Temperature, 102.8°; pulse 80; respiration, 32. Loss of urinary and fæcal contro Consciousness was not again restored; right pupil becam widely dilated and irresponsive to light, and the left con tracted; lower left facial paralysis was developed, and a times there was Cheyne-Stokes respiration; the righ radial pulse became almost imperceptible, while the le remained full and strong. Death occurred in forty-eigh hours. Temperature varied from 100.8° to 102.2°; pulse 128 to 130; respiration, 30 to 28.

Lesions.—Separation of left coronal suture for one an one-half inches, and interval filled with clot; slight epi dural hemorrhage at that point, and slight pial hemor rhage over left fissure of Rolando; extensive laceration o right temporal lobe involving nearly its whole lateral sur face; consequent cortical hemorrhage, which extende through a wound of the dura mater and covered the regio of the right hemisphere.

CASE CLXIV. *Symptoms.* — Primary and permanen unconsciousness. On admission to the hospital, righ hemiplegia; all reflexes exaggerated; loss of urinary an fæcal control; right pupil dilated, left normal, and bot irresponsive to light; large hæmatoma in parieto-occipita region; pulse full and very irregular, and right radia pulsations fuller and stronger than the left. Death oc curred two hours later. Temperature on admission, 98°

receded to 95.6°, and then rose progressively to 104.8°. Pulse, 56, 76, 54, 128. Respiration, 4, 18, 12, 24, 14, 22, 18, 26, 12.

Lesions.—Linear fracture across posterior part of both parietal bones from one squamous portion to the other. Thick cortical clot covering left parietal lobe, in greatest amount over external part of superior surface, and extending to frontal and to occipital lobes from a laceration which excavated and filled with clot the entire parietal lobe. An independent subcortical laceration in the left frontal lobe was one and one-half inches in diameter. A moderate cortical hemorrhage on the right side was derived from a laceration of the right parietal lobe, which was linear in the cortex, and subcortically was three-fourths of an inch wide by one and one-half inches in depth. There was slight cortical hemorrhage in the left middle fossa and upon the superior surface of the cerebellum; slight hyperæmia and no œdema of the brain substance. There was no lesion of the pons or medulla, and no hemorrhage upon their surfaces.

CASE CLXV. *Symptoms.* — Patient fell fifteen feet, striking upon his head; primary and permanent unconsciousness; stertor; pupils normal; no hemorrhage, or loss of fæcal or urinary control; vomiting; all reflexes exaggerated; restlessness, which soon required mechanical restraint; hæmatoma in left parietal region. Death in thirteen hours. Temperature on admission to the hospital, 99.4°, rising progressively with one recession of 0.4°, to 105.2°, and post-mortem elevation to 107.4°. Pulse, 88 to 116; respiration, 22 to 38.

Lesions.—Linear fracture of left parietal bone, four inches in length, parallel to the temporal ridge; extensive laceration of left temporal and parietal lobes, extending into the posterior cornu of the lateral ventricle, with large cortical hemorrhage upon their surfaces; laceration of inferior surface of right frontal lobe, with small cortical hemorrhage.

CASE CLXVI. *Symptoms.*—Patient found unconsciou after having fallen twenty-five feet six hours previously on admission to hospital, skin cold and wet from ex posure to the rain; compound depressed fracture in righ temporal region, with fissure running across coronal su ture; small depressed fragment elevated and remove from parietal bone; right pupil widely dilated and im movable; muscular rigidity of left side, which disappeare after elevation of osseous fragment; compound fractur of left forearm. Ten hours later there were some transien manifestations of consciousness; urinary control was los On the second day, left unilateral convulsions occurre every fifteen minutes during two hours, and two simila paroxysms on the third day; rigidity of the left arm an leg was permanent after the first convulsion. Anæsthesi was indeterminate. Temperature was irregular; it wa 100.2° on admission, rose to 103° in six hours, fell t 100.6° in twenty-eight hours following, then rose pro gressively to 107° in twenty-one hours more, when it wa reduced by alcohol bath to 102.8°; it then again rose pro gressively to 106.4°, at death at the end of sixty-eigh hours. Pulse, 84 to 152; respiration, 24, 40, 28, 52.

Lesions.—Small epidural hemorrhage over left occipita lobe and external border of left cerebellar lobe; moderat general hyperæmia and œdema of the brain; well marke contusion of inner surface of left optic thalamus anteriorly and deep and wide laceration of the superior and inne surfaces of the right optic thalamus; contusion of forni anteriorly with very distinct punctate extravasations; clo one-half inch in diameter in the centre of the left cere bellar lobe.

Fractures Confined to the Cranial Vertex from Pistol-Shot Wound.

Case CLXVII. *Symptoms.* — Coma; stertor; rapid pulse. Temperature fell to 95°. Death in four hours.

Lesions.—Pistol-shot fracture of right frontal bone; ball entered anterior extremity of fissure of Sylvius, traversed right frontal lobe just below cortex, parallel to its curve and a little backward, crossed median fissure into left parietal lobe, impinged upon left parietal bone, which it fractured, and fell back into its track half an inch below the surface, where it rested; little intracranial hemorrhage.

Case CLXVIII. *Symptoms.*—Coma, soon becoming profound; normal pupils; general muscular twitching. Death in twelve hours.

Lesions.—Pistol-shot fracture of right frontal bone; ball traversed right hemisphere nearly in its antero-posterior diameter, just above corpus callosum, impinged upon inner surface of occipital bone, and fell into inferior occipital fossa above dura mater; considerable cortical hemorrhage.

Case CLXIX. *Symptoms.*—Pistol-shot wound of right temporal region; unconsciousness; no other immediate general symptom; pulse, 70; temperature, 99°; consciousness soon restored; mental processes normal but sluggish; some discharge of brain matter followed an unsuccessful attempt to locate and remove the ball on the second day; wound afterward practically healed; mental condition apathetic, rational, but without any manifestation of interest in surrounding persons, things, or circumstances; urine and fæces voided without any indication of consciousness. Temperature, 100°+ to 103.6°, usually 101°+. Death in thirty days.

Lesions.—Pistol-shot fracture of right frontal bone; ball entered middle of right third frontal convolution, passed through central portion of both frontal lobes to a

point just behind ascending arm of fissure of Sylvius in upper portion of island of Reil, and rested in a cavity five-eighths by seven-eighths of an inch in its diameters, surrounded by clot and brain detritus.

CASE CLXX. *Symptoms.*—Pistol-shot wound of right side of the head. Left facial paralysis on second day; hernia cerebri on the third day; mental condition deteriorated and paralysis increased. Patient transferred to Bellevue Hospital on the thirtieth day; then suffering from hysteria and melancholia, which had preceded the infliction of the injury; restlessness; loss of control of urine and fæces; left hemiplegia; slight dilatation of pupils; articulation difficult; sensation normal; pain in right supra-orbital region and at seat of the wound; mental processes slow. Temperature, 100°; pulse, 120 to 140; respiration, 20. At site of injury there was an infected granulating wound through which a probe could be passed into the brain. Four days later, under ether, an attempt was made to locate the ball, and a cavity was found to exist, extending nearly transversely inward two inches and a half, with moderately firm and well-defined wall, and having a small bit of bone at the bottom. The ball was not discovered. Temperature from admission had risen to 102.6° at time of exploration. Death occurred two days later; temperature then, 107.4°.

Lesions.—Pistol-shot fracture of right temporal bone in squamous portion; osseous wound had been enlarged by trephination; slight hemorrhage over right occipital lobe and a few threads of yellow exudate in same region and on the right side of the median fissure; ball passed through lower face area, nearly transversely inward to a point beneath the median surface and just above the calloso-marginal fissure; was then deflected backward at a right angle by the resistance of the falx cerebri, and was lodged an inch behind the cavity recognized at the time of exploration. General cerebral hyeræmia.

CASE CLXXI. *Symptoms.*—Pistol-shot wound of left

side of the head: unconsciousness, which continued till death, five hours later; slight dilatation of left pupil. Temperature one hour after reception of injury, 98.2°; two hours afterward, 97.6°; fifteen minutes before death, 99°. Pulse, 118 to 132; respiration, 28; later, 32 and stertorous; fifteen minutes before death, 7; and finally, 2.

Lesions.—Pistol-shot fracture of squamous portion of left temporal bone in its posterior portion, an inch below temporal ridge; foyer of entrance triangular; each arm half an inch in length; bone comminuted, and the fragments penetrated the cerebral cortex. Ball entered temporal lobe between two large branches of the meningeal artery, passed transversely across the brain immediately below the cortex, and was lodged in the right parietal lobe; cortical hemorrhage from injury of the right parietal lobe by the ball in its course extended under the tentorium and over the pons and medulla, and was apparently the immediate cause of death; cerebral hyperæmia confined to the vicinage of the bullet track.

CASE CLXXII. *Symptoms.* — Suicidal pistol-shot wound. Primary and permanent unconsciousness; loss of urinary and fæcal control. Death in seventeen hours. Temperature one hour after reception of injury, 98.6°, rising progressively to 105.4°; pulse, 44 to 116; respiration, 28 to 34.

Lesions.—Ball of 38 cal. entered one and one-half inches behind right external angular process. External wound circular, patulous, and smaller than the ball. Skin said to have been smoked but no trace remaining; hair singed, but skin not scorched or burnt; right eye ecchymotic; grains of powder closely embedded in the skin over an area of four by three inches, some hundreds in number, and confined to the temporal region. Subcutaneous tissues not blackened; much hemorrhage into the scalp from wound of entrance and of exit. The ball passed through right temporal muscle and through both frontal lobes, and was lodged in the osseous wound of exit nearly

opposite its entrance, lying upon its long axis. The osseous entrance was irregular in form, larger than the ball, and neither comminuted nor fissured; the exit was comminuted in an area one inch in diameter. The skull was thin. The ball severed the middle meningeal artery, but there was no epidural hemorrhage. Thick arachnoid clots covered both frontal and the right parietal lobes, and extended into the median fissure upon the right side of the falx cerebri, and occupied all the basic fossæ. Both frontal lobes were extensively excavated and filled with clot, and some fluid blood was found in the left lateral ventricle.

CASE CLXXIII. *Symptoms.*—Subject found dead with pistol in his hand a moment after suicidal shot was heard.

Lesions.—Ball entered two and three-fourths inches above the right ear; wound smaller than the ball, circular, and inverted; no smoke stain, or grains of powder discernible; brain matter in the hair; skin burned on the posterior aspect of the wound, and hair slightly singed; subcutaneous tissues blackened; right temporal muscle and scalp on right side infiltrated with blood. Osseous entrance large, irregular, and not comminuted or fissured; no powder appreciably carried into the cranial cavity. The ball, of 0.32 cal., passed through the groove for the middle meningeal artery, which was abnormally broad and deep, entered the brain at the posterior border of the right frontal lobe, just in front of the fissure of Sylvius, passed out of its anterior border, crossed the inferior median fissure, re-entered the brain through the inner margin of the left frontal lobe, traversed the left lateral ventricle, leaving a small fragment embedded in the surface of the caudate nucleus without other injury, and was lodged in the posterior part of the left temporal lobe; small fragments of bone were found along its track and one was driven beyond the ball and embedded in the posterior part of the right parietal lobe. The brain was generally hyperæmic. The surface of both hemispheres

was covered with blood, and a great quantity had escaped from the external wound. The subarachnoid spaces at the vertex contained much serous fluid and the arachnoid membrane was opaque. The surface of the right optic thalamus was softened, and of a greenish color and watery appearance. The right lateral ventricle communicated with a small cavity in the parietal lobe, which in its wall was of the same character as the thalamic surface. This substance, examined later, was found to consist of a network of fine neuroglia without cells and with only a few capillaries. The patient was ascertained to have had a cerebral hemorrhage four years previously, and to have since suffered from mental impairment.

CASE CLXXIV. *Symptoms.* — Patient found unconscious with pistol-shot wound two inches behind right external angular process; pulse and respiration slow; unconsciousness not profound; twitchings of lower extremities; hemorrhage free, and pupils both moderately dilated. After admission to hospital, no symptoms noted except continued unconsciousness and loss of fæcal control. The wound was triangular, one-half inch in length upon each border, edges burned, and muscle exposed and blackened; brain matter upon the surface; powder was ingrained over lower part of the ear, ramus of the jaw, posterior cervical triangle, and also in the submaxillary region. The extreme measurements of this space were 3½″ and 4″; no grains were embedded nearer the wound. The osseous entrance was large and the bone depressed; the exit was large and comminuted. Death in two hours.

Lesions.—Ball entered the brain just above the right fissure of Sylvius anteriorly, passed upward, inward, and a little backward, through the falx cerebri, re-entered the brain through the median surface of the left parietal lobe, and made exit just behind the Rolandic fissure. Many minute fragments of bone and scattered grains of powder were discovered in the track of the ball. The right hemisphere was moderately hyperæmic, and the left very hy-

peræmic and œdematous. There was considerable cortical hemorrhage in left middle and posterior basic fossæ and over left vertex, and a large hemorrhage of intracranial origin existed in the scalp over both parietal and both occipital regions. The osseous exit of the ball, which was of 0.38 cal., was through the left parietal bone a little behind its middle portion and near the median line.

CASE CLXXV. *Symptoms.*—Patient fell while in an epileptic convulsion, and was admitted to the hospital in an unconscious condition, with twitching of the right side, frothing at the mouth, and a large scalp wound of the back of the head; and remained unconscious till his death sixteen days afterward.

Lesions.—Two cranial openings made by trephination previous to present injury. Lacerations of left temporal lobe involving anterior extremity of first and second convolutions, and middle portion of the first, all in process of repair, with clean surfaces and rounded edges.

This man was shot in 1881, fourteen years previous to his death, the ball entering the cranial cavity just behind and below the left external angular process. Epilepsy followed, and several months before his death he was trephined and fragments of bone were removed from near the wound of entrance. He was again trephined, then in the occipital region, within the month of his admission to the hospital. At necropsy, a ball of 0.22 cal. was found lodged in the left trunk area, near the median fissure, projecting through the cortex. A canal, lined with a bloodstained membrane, and situated between the ascending frontal and first parietal convolutions, led from the point of entrance nearly to the site of the ball. A fungus cerebri protruded from the occipital opening of trephination.

The membranous canal was apparently formed after the primary operation.

CASE CLXXVI.—Subject found dead.

Lesions.—The face had been cleansed and there were consequently no blood, smoke stain, or free grains of unburned powder. The external wound, which was situated seven-eighths of an inch internal to the right external angular process, was linear, one and one-half inches in length, and its edge was burned in the central portion; there was no other burn and there were no grains of powder embedded in the skin. The temporal muscle was lacerated and blackened in an area of one inch in diameter and the layers of the scalp were infiltrated with blood in both fronto-parietal regions. The osseous entrance was one-half inch above the right supra-orbital ridge, with a fissure extending across the frontal bone into the left squamous region, but was not comminuted. The ball passed through the anterior part of both frontal lobes, lacerating their inferior surfaces, and fell back into its track without penetrating the opposite dural surface; it was then deflected posteriorly, and was lodged deep in the cerebrum about the right parieto-occipital junction. The ball track was filled with clot and contained a fragment of bone in each frontal lobe; no powder grains were appreciable. The ball was of 0.22 cal. Abundant cortical hemorrhage and moderate general hyperæmia.

CASE CLXXVII.—Subject found dead.

Lesions.—External wound, three-sixteenths of an inch in diameter, with edge burned and inverted, was situated two inches behind and one-fourth of an inch below right external angular process; free external hemorrhage; smudge of smoke upon the lobe of the right ear; no unburned grains upon the surface or embedded in the skin; hair burned over an area one-half inch in diameter; subcutaneous hemorrhage above occipito-frontalis muscle, which was scorched over an area of one-half inch. The osseous entrance was one-half inch long and oval, and the eroded surface of the internal table was powder stained; no fissuring or comminution. The ball of 0.32 cal. passed through the anterior extremity of the fissure of Sylvius, and downward

and forward to the median line, where its track was lost; it was probably deflected by striking upon the cranial base, though the dura mater was uninjured, and it was subsequently found in the left centrum ovale in a direction upward and backward from its original course; it was slightly turned from its vertical axis, and lying in a track scarcely larger than itself. There were free cortical hemorrhage and marked but not excessive cerebral hyperæmia.

CASE CLXXVIII.—Death immediate.

Lesions.—External wound circular, one-eighth of an inch in diameter, and situated one and one-half inches behind, and three-fourths of an inch above, the external angular process; a few loose powder grains in the hair; burned area, one-half inch in diameter, black and crisp, moderate external hemorrhage; pupils unsymmetrically dilated; subcutaneous burned area of three-fourths of an inch above the temporal fascia; temporal muscle infiltrated with blood. The osseous entrance was below the temporal ridge, quadrilateral, clean cut, and three-eighths of an inch in its diameter. The ball of 0.32 cal. entered the frontal lobe, furrowed its base, and, passing obliquely inward and backward, perforated the left temporal lobe between the first and second convolutions, penetrated the dura mater, fractured the squamous portion of the temporal bone, slightly elevating and fissuring the external table, and fell back into the cerebral cortex. Cortical hemorrhage was confined to the furrow upon the basal surface, and to the anterior surface of the pons and medulla, extending into the spinal canal.

CASE CLXXIX.—Subject found dead.

Lesions.—Free hemorrhage from mouth and nostrils; pupils symmetrically dilated. External wound one and one-fourth inches behind, and one-half inch above, right external angular process; smoke stain in front of ear; some grains of powder on the surface in front of wound; black area of one inch in diameter over tem-

poral fascia; powder stain in temporal muscle. The osseous entrance was three-eighths of an inch in diameter, in the upper part of the temporal fossa; and a fissure extended posteriorly around the calvarium into the opposite temporal fossa. The contiguous surfaces of the bone and dura mater were powder stained over an area of one inch. The ball, of 0.32 cal., traversed both frontal lobes, in front of and a little above the anterior border of the corpus callosum, wounded the dura mater, and finely fissured the external table of the left parietal bone near its eminence, without injury to the internal table; it then passed backward between the dura mater and the cerebral surface, and lodged in a sulcus between two convolutions upon the inferior surface of the occipital lobe. It was discovered only on section of the brain.

CASE CLXXX. *Symptoms.*—Suicide. Bullet of 0.32 cal. entered right temporal region two and three-eighths inches behind external angular process and one and three-eighths inches above it; diameter of wound, one-eighth of an inch; margin burned, one-sixteenth inch; skin burned in a triangular area below the wound, one and one-fourth inches long, and one inch wide at its base above; unburned grains of powder which were partly embedded in this space were removed by the hemorrhage and by ablution. Complete unconsciousness, stertor, moderately contracted pupils, and free hemorrhage from the wound; no muscular symptoms. Temperature on admission to the hospital two or more hours after injury, 98°; pulse 62. Thirty minutes later both pupils became dilated, the right more so than the left; general muscular twitching at the end of an hour, and in fifteen minutes more death from pulmonary œdema; temperature post mortem, 100.6°.

Lesions.—Hæmatoma in right temporal region infiltrating temporal muscle; thick clot upon left side of vertex, crossing the median line, and extending from coronal to lambdoid suture; fragment of lead in external

wound; osseous entrance three-eighths inch in diameter; no fissuring or comminution. Bullet passed directly through the parietal cortex, fractured the anterior inferior portion of the left parietal bone, and was then deflected downward and a little forward for two and one-half inches, nearly to the cerebral base and near the corpus striatum; track three-eighths inch wide. No powder grains detected within the intracranial cavity; no epidural hemorrhage; moderate cortical hemorrhage at the vertex; moderate general hyperæmia. Left parietal bone comminuted and fragments elevated in space of one and one-fourth inches by five-eighths of an inch.

CASE CLXXX*a*. *Symptoms.*—Profound unconsciousness, profuse hemorrhage, and almost immediate death.

Lesions.—External wound one-half inch above and one-half inch behind the right external angular process, five-eighths of an inch in diameter, edges lacerated, and occluded by a protruding coagulum; smoke stain, three inches in length and one and one-half inches in width, above the supra-orbital ridge; no unburned grains of powder upon the surface or embedded in the skin; no burns; fibres of the occipito-frontalis muscle blackened and infiltrated with blood; osseous wound circular and one-fourth of an inch in diameter, just above the orbital process of the temporal bone; slight staining of the bone and dura mater, and one or two grains of powder lying upon the orbital plate. The bullet, of 0.32 cal., traversed the anterior extremity of the fissure of Sylvius and both lateral ventricles, and, having lacerated the dura mater and comminuted the bone, rested upon the left parietal surface. One osseous fragment was carried into the right frontal lobe, and several others were removed from the ball track near its termination. The laceration of the right frontal lobe and of the ventricles was very great, but the brain track near the parietal exit was not larger than the bullet. The left squamous and inferior parietal portions of bone were comminuted in an area of

nearly two inches, and one fragment was elevated to an angle of 45°; no injury of the scalp.

ENCEPHALIC INJURIES WITHOUT CRANIAL FRACTURE.

CASE CLXXXI. *Symptoms.*—Violent delirium for two days; recurred on the sixth day, followed by unconsciousness and hyperæsthesia. Temperature, 103° to 104°; afterward, 100° to 103°; final temperature, 103°. Death in twelve days.

Lesions.—Pial hemorrhage over left occipital lobe, extending into median fissure; subarachnoid serous effusion.

CASE CLXXXII. *Symptoms.*—None recognized till fourth day, when there were four unilateral convulsions. A single one occurred on the fifth day, and they then continued with increasing frequency till death on the eighth day. Each one began by a twitching of the facial muscles, with head and eyes turned to the left, and extended to the left arm, and finally to the left hand. Temperature on admission, 100°; twelve hours later, 103°; then 103° to 104°, till sixteen hours before death, when it rose to 105°.

Lesions.—Extensive laceration of right temporo-sphenoidal lobe, with cortical hemorrhage over whole right hemisphere.

CASE CLXXXIII. *Symptoms.*—Mental condition clear, but dazed, on admission to the hospital ten hours after reception of injury; extreme muscular tremor, followed in two hours by a general convulsion; from this time periods of general convulsions, with intervals of unconsciousness or delirium, lasting about six hours, alternated with periods of quiescence of equal length; no initial symptom. Death in two days.

Lesions.—Deep laceration of right frontal lobe, anteriorly and externally, extending into parietal region; cortical hemorrhage, covering right frontal lobe, right

parietal lobe anterior to the Rolandic fissure, and the temporo-sphenoidal lobe, both laterally and inferiorly.

CASE CLXXXIV. *Symptoms*—None. Found dead in an upright position, leaning against a fence.

Lesions.—Lacerations and contusions covering greater part of left frontal and temporo-sphenoidal lobes; cortical hemorrhage over the whole left hemisphere.

CASE CLXXXV. *Symptoms.*—Coma; stertor; contraction of pupils; full pulse; rapid respiration. Temperature, 101°+. On the third day coma more profound; dysphagia; continued irritability and restlessness. Temperature, 104.5°. Death in four days; temperature, 107.4°.

Lesions.—Small laceration at left parieto-occipital junction; cortical hemorrhage over posterior part of left parietal lobe; general hyperæmia.

CASE CLXXXVI. *Symptoms.* — Coma, restlessness, and general hyperæsthesia; temperature, 103.4°; pneumonia discovered on the second day. Death on the third day.

Lesions.—General hyperæmia, with some punctate extravasations; organized membranous effusion, studded with calcareous nodules, over left hemisphere.

CASE CLXXXVII. *Symptoms.*—Sudden coma; stertor; double facial paralysis; complete right hemiplegia and hemianæsthesia; temperature, 99° to 103°. Trephination, and drainage of serous effusion from the base by position of the head, were followed within six hours by return of consciousness, mental clearness, power of articulation, and decline of temperature to 98.6°, and this improvement in condition continued fourteen hours; slight chill then preceded a progressive rise of temperature to 104.6°, and death occurred ten hours later.

Lesions.—Interior of left occipital lobe disintegrated by apoplectic clot, which extended into both lateral ventricles; consequent fall from a cab caused a laceration of external border of right cerebellum and cortical hemor-

rhage, which spread over the pons into the transverse fissure.

CASE CLXXXVIII. *Symptoms.*—No primary general symptoms; temperature, 100°. Second day, delirium. Fourth and fifth days, headache. Sixth day, restlessness, irritability, and failing strength; mind clear. Eighth day, general muscular rigidity, most marked in right side and arm, and, a few hours previous to death, perforating ulcer of the cornea. Temperature, second day, 103.2°; third day, 101° to 100.8°; fourth and fifth days, 103.4° to 103°; sixth day, 106.4°; seventh and eighth days, 105° to 105.2°.

Lesions.—General hyperæmia; minute thrombosis and moderate œdema, markedly involving basic ganglia and cerebellum, and most pronounced on left side; thrombi filled both lateral and both inferior petrosal sinuses, and extended into right jugular vein, and were decolorized only near the torcular Herophili.

CASE CLXXXIX. *Symptoms.* — Delirium; normal pupils and respiration; temperature, 101.4°; pulse, 114. Later, excessive sensitiveness and irritability. The delirium continued, though it did not prevent rational reply to questions; temperature rose to 103.2° on the fifth day, and afterward fell very gradually to 100°; on the fourteenth day it was 103.4°; and on the fifteenth, five hours ante mortem, it was 103.8°, and one hour post mortem it was 104.2°.

Lesions.—Pial hemorrhage over both hemispheres and in largest quantity over parieto-occipital junctions; some subarachnoid serous effusion in left frontal region; general hyperæmia with punctate hemorrhages, most marked on left side.

CASE CXC. *Symptoms.*—Primary unconsciousness; on admission, forty-eight hours later, muttering stupor; rigidity of left arm; incomplete right hemiplegia, more marked in upper extremities; pulse, 60; temperature, 101°. Third day, increased rigidity of left arm; complete hemiplegia; profound coma; pulse, 128; temperature,

105°. Trephination was followed by increased freedom of movement and by some power of articulation. Death on the fourth day.

Lesions.—Moderate subarachnoid serous effusion over anterior two-thirds of right hemisphere; laceration of left temporo-sphenoidal lobe, excavating and destroying its whole structure; cortical hemorrhage extending around circle of Willis and upward upon occipital lobe, and in patches upon frontal and parietal lobes.

CASE CXCI. *Symptoms.*—No external evidence of injury; coma; stertor; rigidity of right side; pulse, 120; temperature, 100°. Death on third day; temperature, 103.2°.

Lesions.—Large subarachnoid serous effusion; recent clot in substance of left cerebellum. An old laceration existed upon antero-superior surface of left occipital lobe and another upon its inferior surface.

CASE CXCII. *Symptoms.*—Consciousness lost, and partially restored before admission, twenty-four hours later; mental condition rational, but comprehension slow; slight dilatation of left pupil. Temperature, 99°, followed by some left paresis and by some dysphagia referred to the left side of the throat. The patient from the time of injury often fell out of bed, always on the right side. Subsequently transient facial paralysis occurred; amount of paresis and of dilatation of left pupil varied from day to day; mental condition deteriorated. Temperature for ten days was 99°+; later, 100°+ to 101°; pulse and respiration nearly normal. Trephination on the fifteenth day discovered a small subcortical cavity in the right leg area containing less than a drachm of yellowish fluid, afterward found to contain leucocytes. The temperature was 99°+ till eleventh day after operation, when it rose to 104°; next day, 101° to 104°. Death from asthenia on the twenty-eighth day after admission.

Lesions.—Large subarachnoid serous effusion compressing frontal lobes; general hyperæmia with minute coag-

ula. The brain substance around the small subcortical cavity opened during life was softened and contained punctate extravasations.

CASE CXCIII. *Symptoms.* — Unconsciousness, which still continued upon admission on the second day; slight dilatation of the pupils; complete left hemiplegia and hemianæsthesia; slight left facial paralysis. Temperature, 106°; pulse, 140; respiration, 30; general convulsions beginning soon after admission, and frequently repeated; initial symptom in mouth and lower face. Trephination same day by house surgeon with negative result. Temperature two hours later, 107.4°. Death in a convulsion five hours after operation. Temperature, forty-five minutes post mortem, 109.4°.

Lesions.—General hyperæmia of the brain and membranes; tumor of the size of a pea resting in a small cavity in the left frontal lobe formed by disintegration of surrounding brain tissue.

CASE CXCIV. *Symptoms.* — Condition alcoholic and habit epileptic; fell in an epileptic convulsion; large hæmatoma over left frontal and parietal region; three convulsions within first six hours, the last followed by partial paralysis of left lower face. The temperature on the first day was 101.8°, 102.8°, 100°; second to sixth days inclusive, 100.6° to 102°+; seventh to ninth day, normal; and then for ten days subnormal during the greater part of each twenty-four hours. On the thirteenth day a severe chill was followed by temporary rise of temperature to 101°+; and on the nineteenth day a slighter chill by an elevation of temperature, which progressively increased till death, on the twenty-first day. Until the occurrence of the second chill there were few general symptoms; some remaining paresis and anæsthesia of the right face, more or less mental aberration, and some delusions. After the second chill strength diminished, the mental condition became sluggish, the respiration rapid, and temperature rose to 105.5°.

Lesions.—Subcortical laceration and excavation of left pre-frontal lobe, with a prolongation backward to a point opposite to the middle of the corpus striatum; no hemorrhages; large subarachnoid serous effusion and opacity of the arachnoid membrane over the whole vertex; general hyperæmia and œdema.

CASE CXCV. *Symptoms.* — Consciousness retained; wound in right parietal region; condition alcoholic; heavy sleep during the first night after admission; afterward constant restlessness; some pain in the back of the head; vomiting of everything taken into the stomach; temperature on admission, 102.6°; second day, 105°; and at time of death, which occurred somewhat suddenly at the end of the third day, 103.8°; pulse moderately accelerated, varying from 120 to 88; pupils and respiration normal.

Lesions.—Subarachnoid purulent effusion over both frontal lobes, mainly on the left side, with some general œdema of the pia mater; scanty fibrinous exudation at the base; and fibrinous patches on inner surface of the dura at the convexity.

CASE CXCVI. *Symptoms.*—Absolute unconsciousness till death, one hour and a half after reception of the injury; small wound behind the right ear; dilatation and immobility of both pupils; respiration on admission, 42; an hour later, 21; ceased at death rather suddenly; no cyanosis; pulse feeble and soon became imperceptible; temperature on admission, 98.6°; an hour later, 98.2°.

Lesions.—Force transmitted through the feet and lower extremities; fractures of both tarsi, comminution of both calces and right astragalus, fracture of left leg, and contusion of soles of both feet; pial hemorrhage to extent of several ounces of fluid blood, mainly at the vertex and in larger part on the left side, extending into median fissure, and which had broken through into the arachnoid cavity; also in considerable quantity upon the inferior surface of the cerebellum, about the median line, and covering the pons; no lacerations; excessive general hyperæmia, most

strongly marked on the left side and in the pons, optic thalami, and corpora striata, in the order named; thrombosis of minute vessels generally, but most pronounced in the optic thalami and pons; œdema of the pons.

CASE CXCVII. *Symptoms.* — Primary unconsciousness; and on admission mind confused and speech disconnected; four general convulsions from twelve to twenty-four hours afterward; no control of urine or fæces; second day, semi-consciousness; muscular rigidity in back of the neck and extremities; some irritability; fourth day, mental condition rational, but no remembrance of the manner in which the injury had been received. During the next ten days the urine, but not the fæces, remained uncontrolled; there was noticeable weakness of the muscles of the trunk, inability to rise or sit up in in bed without assistance, dementia and loss of memory, primary union of the wound, and nearly normal pulse and respiration. On the fifteenth day there was somnolence and increase in temperature and infrequency of the pulse and respiration; stupor deepened, and on the seventeenth day unconsciousness was complete. Death occurred in eighteen days. Temperature on admission, 99.4°; fourth day, 99°; till the end of second week, 99° to 100°+; on the seventeenth day, 102.7° to 103.8°; on the eighteenth day, 105.4°. Pulse on admission, 96; normal till fifteenth day; later, 160. Respiration on admission, 26.

Lesions.—Hæmatoma over right parietal eminence; thrombus in superior longitudinal sinus; great fulness of meningeal veins over vertex; convolutions flattened; frontal lobes relatively small, parietal lobes bulging as though from distention; general cerebral hyperæmia and œdema without punctate extravasations and with few minute thrombi; substance of cerebellum nearly normal. By compressing posterior portion of the cerebrum and making vertical sections anteriorly, serous fluid exuded in great quantity; little serum in the ventricles. A clot about the size of a large pea and of elliptical form occu-

pied the exact centre of the anterior third of the left optic thalamus. There were no other lacerations, and no hemorrhages or subarachnoid effusions, and upon microscopical examination no inflammatory changes.

CASE CXCVIII. *Symptoms.* — Walking case; unconsciousness supervened some hours after injury, and continued till death on the third day; wounds in occipital and both parietal regions; slight dilatation of left pupil. Temperature, 103.6° to 106.6°.

Lesions.—Large pial hemorrhage compressing left fronto-parietal region; excessive general hyperæmia with numerous minute thromboses; subcortical laceration just external to anterior part of left corpus striatum, one inch by half an inch in its diameters.

CASE CXCIX. *Symptoms.* — None recognized till admission three days after reception of the injury; partial loss of consciousness; complete right hemiplegia and hemianæsthesia including trunk; complete aphonia; slight dilatation of pupils; bilateral convulsive movements of face and neck with the eyes turned to the right, repeated every five minutes; respiration shallow and hurried; pulse rapid, feeble, and irregular. Temperature, 101° to 104°; radial pulsation fuller and stronger on the left side than on the right. Trephination disclosed arachnoid clot. Death occurred before operation was completed.

Lesions.—Pial hemorrhage with clot covering both frontal and both parietal lobes; right lateral ventricle filled with hemorrhagic serous effusion; general hyperæmia.

CASE CC. *Symptoms.* — Walking case; unconsciousness supervened some hours after apparently trivial injury; no discoverable external lesion; dilatation of pupils; second day, partial restoration of consciousness; fourth day, delusions; ninth day, stupor; eleventh day, complete unconsciousness. Death at end of twelfth day. Temperature on first day, 102.4°; afterward, 101° to 99°;

final observation, 100.8°; pulse, 76°, gradually increasing in frequency; respiration, 24, 20, 28.

Lesions.—Thin layer of pial hemorrhage which covered the opposing surfaces of the superior median fissure, and spread over left occipital and parietal lobes to margin of temporal lobe; some blood, also pial, in left middle fossa; general hyperæmia and moderate œdema.

CASE CCI. *Symptoms.* — Unconsciousness which soon after admission was replaced by delirium; no external injury; loss of urinary control; delirium constant, of a quiet sort by day a d violent by night till the seventh day, when for some hours before death it was muttering, or typhoid, in character; mental condition stupid from the beginning; patient was at no time able to give any account of himself, to respond to a question, or to show any appreciation of his surroundings. Death from asthenia on the seventh day. Temperature on admission, 96.2°; rose progressively in three days to 103.2°; on the fourth day was 101.8°; on the fifth day, 103°; on the sixth day, 104.6°; and on the seventh day, 101.2° to 107.2°; post mortem, 107.8°. The pulse did not exceed 100 till late in the week.

Lesions.—Small laceration in the substance of the posterior part of the left frontal lobe; laceration of under part of the corpus callosum in its anterior third, and of left lateral edge of the fornix anteriorly; small hemorrhage in left lateral ventricle derived from the laceration of the fornix; pial hemorrhage over posterior part of right occipital lobe, upon its border, beneath tentorium, and upon the posterior border of the cerebellum; blood fluid and moderate in amount; moderate general hyperæmia with minute thromboses.

CASE CCII. *Symptoms.*—Walking case; unconsciousness after some hours' interval; stertor; loss of urinary control; vomiting. Temperature, 101.8°; rose progressively to 107.8°; pulse, 70 to 162; respiration, 24 to 46. Death in eleven hours.

Lesions.—Laceration of superior surface of right parietal lobe; cortical hemorrhage covering whole right hemisphere; general hyperæmia.

CASE CCIII. *Symptoms.* — Unconsciousness, which soon became profound; normal pupils; pulse in a few moments rose from 90 to 140; right side of body and right extremities rigid; bilateral convulsive movements; right radial pulse fuller and stronger than the left. Death in eight hours and a half. Temperature on admission, 97°; in three hours, 101°; in six hours, 102.2°; pulse 90 to 140 to 136; respiration, 20, 18, 21; and just before death, 12 and then 7 in the minute, very full and deep, with cyanosis.

Lesions.—Small contusion of scalp in left middle parietal region discovered only after post-mortem incision; thin pial hemorrhage, mostly fluid, covered whole superior and external surfaces of both hemispheres as far forward as the middle of the frontal lobes, extended in larger quantity over both surfaces and both borders of the cerebellum, and spread over the pons and medulla; pia mater intensely hyperæmic; small contusion on inner border of right temporo-sphenoidal lobe, and a larger one at left parieto-occipital junction; brain substance generally excessively hyperæmic and œdematous, with many small areas of local contusion filled with small hemorrhages as large as a robin-shot.

The essential lesion was laceration of the basic ganglia. The right corpus striatum was entirely disintegrated and destroyed; its ventricular surface only remained, as a ragged membranous capsule, of which much had altogether disappeared. The laceration extended antero-laterally into the substance of the right frontal and parietal lobes; it was continued posteriorly through the tænia semicircularis into the anterior part of the optic thalamus. The ventricular surface of the left corpus striatum was contused and marked by small linear lacerations. The fornix and under surface of the corpus callosum were softened and disintegrated. Fluid blood

partly filled both lateral ventricles, and in the left had broken through the posterior cornu into the occipital lobe in considerable quantity.

CASE CCIV. *Symptoms.*—Immediate unconsciousness with some response to external irritations, which continued till final coma; continued dilatation of both pupils, which were sensitive; temporary rigidity of left side; right hemiplegia and hemianæsthesia, and right facial paralysis; restlessness, which was confined to the left side; retention of urine; coma and stertor for five hours before death, which occurred in fifty-three hours. Six hours before death the left hand became icy cold and the left arm and foot cool, while other parts of the body retained a normal surface temperature. At this time the rectal temperature was 102.6°; the left axillary, 100.4°; and the right axillary, 103.2°. In fifteen minutes the temperature in the left axilla rose to 101.4°, and in thirty minutes to 102.8°, while the rectal and right axillary temperatures remained stationary. The axillary temperatures were at other times symmetrical. Temperature on admission was 98.5°, and in two hours, 102.2°; in eleven hours it receded to 101°, in the next twelve hours rose to 105°, on the second day receded to 100.4°, and a few moments before death was 106°; one hour post mortem, 106.2°. The pulse gradually increased in frequency from 110 to 158. The respiration was never below 30, and was finally 56 in the minute.

Lesions.—Contused wound of the scalp over right parietal eminence; slight pial hemorrhage over inferior surface of cerebellum and posterior left occipital border; copious subarachnoid effusion and arachnoid opacity in posterior parietal regions most marked on the left side; small hemorrhagic serous effusion in left lateral ventricle; limited contusion and slight laceration in the substance of the fornix posteriorly; excessive general hyperæmia and œdema, with a few minute thrombi in all parts of the brain.

CASE CCV. *Symptoms.* — The patient walked home after a fall of ten feet, had a single convulsion a few hours later, and was stupid or dazed for five days afterward; he then became violently delirious, and was admitted to the hospital. At that time, no visible external injury; pupils moderately dilated; opposite radial pulsations symmetrical; posterior cervical muscular rigidity, and loss of urinary control. On the following (seventh) day pupils contracted, and muscular rigidity increased; one convulsion after admission; mental condition marked by alternations of stupor, with wild delirium. No change till the eleventh day, when the patient became quieter, and could answer a limited number of questions intelligently. On the fifteenth day the pupils became normal, muscular rigidity diminished, and urinary control was temporarily regained. From the sixteenth day unconsciousness was complete. On the seventeenth day the pupils were again contracted, the respiration was stertorous, and the face cyanotic; the lungs became œdematous, and death occurred on the morning of the nineteenth day. The temperature on admission was 102°, and varied from 99° to 101°+ with occasional elevations to 102°+ till the last thirty-six hours, when it was constant at 105.6°; and half an hour post mortem was 106°. The pulse on admission was 132, and afterward was usually from 96 to 112. The respiration was moderately increased in frequency. Both pulse and respiration were finally greatly accelerated.

Lesions.—Cortical hemorrhage, compressing outer and anterior aspect of right frontal lobe, and filling right anterior fossa. This was derived from a laceration of the inferior surface of the right frontal lobe, mainly subcortical, which excavated its inferior and outer portion; cavity as large as a pigeon's egg and lined by a thin, chocolate-colored, and pultaceous substance. Small linear laceration upon inner border of left frontal lobe and slight contusion of anterior portion of right temporo-sphenoidal lobe, both upon inferior surface; opacity of arachnoid

membrane; no subarachnoid serous effusion, and only very moderate hyperæmia of the brain substance.

CASE CCVI. *Symptoms.* — Primary and permanent unconsciousness; restlessness; general muscular rigidity; stertor; irregular pupils. Temperature on admission, 100°, and at death 99.8°; pulse varied from 108 to 160; respiration, 32 to 58. Death in an hour and a half.

Lesions.—No fracture or lacerations; large general subarachnoid and ventricular serous effusion; general hyperæmia and excessive œdema.

CASE CCVII. *Symptoms.*—Patient in an alcoholic condition; said to have been injured two days previously; stupid, but could walk and answer questions. On admission to the hospital temperature 98.5°; rose progressively to 102°+ at time of death. On second day, deep coma, pupils normal, pulse began to grow weaker; no other symptoms till sixth day, when, just before death, respiration became of the Cheyne-Stokes variety.

Lesions.—No injury of scalp or skull. Pia mater cloudy and much injected; pial hemorrhage on the right side, over posterior third of first and second frontal, and upper third of ascending frontal convolutions; on the left side it involved only posterior third of first frontal; a clot about the size of a pea in the substance of the left gyrus fornicatus, about its middle portion; brain substance very hyperæmic; no lesions of thoracic or abdominal viscera except commencing pericarditis.

CASE CCVIII. *Symptoms.* — Temporary unconsciousness, followed by coma and stertor two hours later, and in another hour by a convulsion, beginning with tonic spasm of the arms and legs, and succeeded by others at short intervals till admission to the hospital nine hours after receipt of injury. Twenty-two convulsions occurred from this time till death at the end of twelve hours. Each began upon the right side of the face and extended to the extremities of the left side; eyes, with the head and neck, turned to the left; sometimes the right pupil only, and

sometimes both pupils, dilated. Consciousness was never regained. Temperature on admission, 101°; fell to 100.2°, and rose to 101° at death; thirty minutes post mortem, 100.6°; pulse, 120, 96, 128; respiration, 20, 16, 28, 15.

Lesions.—No injury of scalp or cranium; dura mater congested; pial hemorrhage over whole left hemisphere, and in left posterior and middle basic fossæ; clot thickest over left motor area; actual weight of clot, three ounces; brain substance hyperæmic; serous effusion in each lateral ventricle; basic arteries atheromatous.

CASE CCIX. *Symptoms.* — Patient said to have had attacks of faintness or vertigo for a length of time, in one of which he fell down a flight of stairs and fractured a cervix femoris. He became momentarily unconscious, and after a little interval was again unconscious for one or two hours. On admission to the hospital three days later no intracranial lesion was recognized. His temperature but once exceeded 99°. Seven weeks afterward while crossing the ward he fell, striking upon the back of his head. Both pupils were moderately contracted but unsymmetrical. After an interval of thirty minutes he became temporarily unconscious; pulse remained weak and frequent; temperature did not exceed 101°; left arm was raised more slowly than the right; and death occurred in twenty hours.

Lesions.—Recent: meningeal and cortical vessels much injected; arachnoid opacity and turbid yellowish subarachnoid serous effusion at the vertex; some serous effusion in both lateral ventricles; brain substance hyperæmic. The heart was fatty, its right side dilated, and its coronary arteries thickened and rigid. The liver and kidneys were cirrhotic, and there were points of pulmonary hemorrhage. Old: a cavity, one inch by one-half inch in diameter, and nearly filled with a pinkish pultaceous material, and in process of contraction, was found just beneath the cortex and just above the horizontal arm of

the right fissure of Sylvius. A similar cavity of half the size was situated a little anterior to the first.

CASE CCX. *Symptoms.*—No loss of consciousness followed injury; one convulsion occurred five or six hours later. On admission to the hospital on the following day, mental condition stupid, speech incoherent, pupils contracted, radial pulsations symmetrical, and a scalp wound in the parieto-occipital region. Temperature, 98.2°; pulse, 86; respiration, 32. Stupor continued with slight general convulsions and loss of urinary and fæcal control. Temperature rose to 102°, and on the second day to 104°; no further convulsions. On the third day the stupor was replaced by restlessness and delirium, which were not constant but continued afterward the greater part of each day and night. After the first week the neck and shoulders were quite stiff and sometimes painful. The pupils were normal or slightly contracted; fæcal and urinary control was not regained. Strength failed rather suddenly a few hours before death, which occurred on the fourteenth day. The temperature, from 104° on the second, subsided to 100.6° on the third, and to 98.8° on the fourth day, and subsequently ranged from 99° to 101°. At death, it rose to 102°, and thirty minutes post mortem to 103°. The pulse varied from 60 to 90, and the respiration, after the third day, from 20 to 28.

Lesions.—Scalp wound as noted; no fracture. At a point beneath the scalp wound, the dura mater, arachnoid membrane, and pia mater were adherent over an area of one inch by one-half inch, mainly on the right side but extending across the median line. There was considerable subarachnoid serous effusion with slight arachnoid opacity, and the cortical vessels were injected. A cortical laceration of the posterior inferior border of the right occipital lobe, not larger than a pea, was surrounded by an area, one inch in diameter, of dusky and greenish-colored cortex; a subcortical laceration beneath this extended across the whole posterior border of the lobe, and

forward into the right lateral ventricle, and was filled with disintegrated coagulum; the cavity of the ventricle was bloodstained throughout and contained fragments of dark-colored clot. There was a second dull, dusky, and greenish-colored area, one and a half by three-fourths of an inch in its diameters, about the centre of the posterior inferior border of the left occipital lobe, and beneath this another subcortical hemorrhage which excavated a large part of the lobe and opened into the lateral ventricle; the appearances of this cavity and ventricle were similar to those upon the opposite side. There was no communication between the two cavities of laceration. There was a little cortical hemorrhage about the laceration upon the right side and a little upon the superior surface of the left cerebellum, coming from a slight laceration of its external border. The brain substance was moderately hyperæmic, with minute thrombi of the vessels.

CASE CCXI. *Symptoms.*—Patient found in the street in an epileptiform convulsion. On admission to the hospital, unconscious tossing about and frothing at the mouth, with some rigidity of the limbs, and dilated immovable pupils; skin reflexes absent. Death on the following day without material change in symptoms having occurred. Temperature on admission, 100°, rose in four hours to 106° and in sixteen hours to 106.2°, and in the following sixteen hours receded to 104°; no temperature taken in the four hours immediately preceding death. Pulse 100, 160, 94. Respiration, 20, 50, 46.

Lesions.—No injury of scalp or skull; no laceration or contusion of the brain. Slight subarachnoid serous effusion over both posterior parietal regions. About one drachm of thin purulent effusion between the cerebellar lobes and upon their inferior surfaces anteriorly. Excessive hyperæmia and œdema of the brain, with venous distention.

CASE CCXII. *Symptoms.*—Patient had been knocked down by a wagon, and was semi-conscious when admitted

to the hospital. Lacerated and contused wound of the scalp in left temporal region; pupils normal; no muscular or sensory symptoms. Temperature, 100.5°; pulse, 90°; respiration, 24. On the second day, fæcal and urinary control lost; slight increase of temperature, and apparent unconsciousness, only broken by monosyllabic cries when disturbed. On the third day, temperature 102.8°, 104°, 102°; pulse, 110; respiration, 36; urine retained, continued lack of fæcal control, and mental condition sluggish. Trephination and incision of dura mater in front of coronal suture with negative result; a second trephination, a little above and behind the right ear, disclosed a larger subdural clot, much of which was removed, and a laceration of the brain. No material change in the patient's condition for eighteen hours, when the temperature began to rise from 102.4°, with progressive increase to 107.2° at death ten hours later; pulse, 106, 128; respiration, 26, 20.

Lesions.—No fracture; laceration of the right temporal lobe and a remnant of blood clot extending to base in the middle fossa.

CASE CCXIII. *Symptoms.*—Patient said to have fallen in the street. On admission to the hospital, stupor, wounds in the right temporal and posterior parietal regions, and vertigo. Temperature, 101.2°; pulse, 76; respiration, 26. On the second day, vomiting, slight dilatation of the pupils, and headache; mental confusion, and inability of comprehension; answers to questions were sometimes intelligent, but mainly ejaculatory; mechanical restraint required for retention in bed; temperature, 102°, 101.4°; retention of urine. At the end of the first week the temperature, which had ranged for three days from 98.8° to 101°, suddenly rose to 104.6°, with an access of delirium, and three days later again became normal, and for the ensuing four days varied from 99°+ to 100°+; on the fifteenth day it rose to 103.2°, and from that time was marked by great irregularities until death. Fifteenth day, 103.2°, 100°, 105.6°; sixteenth day,

104.8°, 105.6°, 98.4° (chill), 105.6°, 101.2°; seventeenth day, 99.8°, 102.4°, 100°, 103.2°; eighteenth day, 102°, 106°, final.

The pulse and respiration were also variable, but frequent. Ten minutes before death there were left unilateral convulsions.

Lesions.—No fracture; large subcortical laceration of the anterior part of the left frontal lobe, which formed an excavation, one and a half inches by three-fourths of an inch in its diameters, filled with dark-colored clot; it was brownish-yellow, soft and ragged; the cortex was broken through at the tip of the lobe. A cortical superficial laceration existed in the centre of the inferior surface of the left cerebellar lobe, of a chocolate color, soft, with ill-defined margin, and no apparent loss of tissue. At this point the meninges were adherent to the bone. There were no hemorrhages; there was marked general hyperæmia and œdema. There was an opaque subarachnoid effusion all over both hemispheres, which was copious at the base posteriorly. The basilar arteries were somewhat atheromatous and the heart was thickened, as were the aortic valves.

CASE CCXIV. *Symptoms.*—Patient fell five stories to the pavement. Primary and permanent unconsciousness, wound in right temporal region, hemorrhage from both nostrils, slight twitchings of left arm, pupils normal; temperature, 99.8°; pulse, 130; respiration, 27. Restlessness and unconsciousness continued till death thirty-four hours later; temperature rose progressively to 108°, with no immediate post-mortem change.

Lesions.—No fracture; small pial hemorrhage over lateral aspect of right temporal lobe, and moderate general hyperæmia and œdema; no limited lesion.

There was a laceration of the left kidney which had been recognized during life.

CASE CCXV. *Symptoms.* — Patient fell fifteen feet, was dazed but walked about, conversed with his associates,

and was not thought to be seriously injured. Half an hour later he became somnolent, and was taken to the hospital, which he reached in an entirely unconscious condition; temperature, 96°; pulse, 68; respiration, 12; right pupil dilated; slight rigidity of left arm and leg; wound in right frontal region, and hæmatoma. Death in three hours. Temperature, 97°; pulse, 100°; respiration, 10.

Lesions.—No fracture; wound of anterior branch of right middle meningeal artery, and consequent epidural hemorrhage, forming clot three and one-half by three inches in diameters, and one and one-half inches in thickness; brain moderately hyperæmic and œdematous; no laceration.

CASE CCXVI. *Symptoms.* — Primary and permanent unconsciousness, pupils slightly contracted, right pulse fuller than the left, hemiplegia of the left side, reflexes absent, head and eyes turned to the left. Death in four hours.

Lesions.—No fracture; laceration of the right parietal lobe, and hemorrhage into the lateral ventricle and at the base of the brain.

CASE CCXVII. *Symptoms.*—The patient was knocked down by a cable car. Temperature, 96.2°; pulse, 92; respiration, 20; loss of consciousness not absolute; restlessness, no external injuries, and no other pathic indications. During the day temperature rose to 101.6°, and during the night patient was restless, noisy, got up and then urinated in bed, and mechanical restraint was employed. Death occurred on the twenty-third day. He was usually quiet and stupid by day, and restless, noisy, and striving to get out of bed at night; on the fourth day there was stiffness of the neck, and on the fourteenth day of the arms and legs; fæcal and urinary control was lost on the seventh day, and on the twentieth the voice was thick, the head extended, and the condition typhoid. The temperature on the sixth, seventh, eighth, and ninth days was subnormal, 97.8°, 97.2°, 97.6°, and was afterward variable,

usually 101–102°+, occasionally rising to 103°–105°. The final temperature was 109.2°, with no immediate post-mortem change. The pulse, when the temperature was subnormal, was from 76 to 100, and the respiration normal; and in the last five days both were frequent.

Lesions.—No fracture; deep laceration, three-fourths of an inch in length, upon inferior surface of left frontal lobe, and another of the same extent upon the inferior surface of the left temporal lobe, both with excavated edges and of a dirty brown color; large cortical hemorrhage in middle and anterior fossæ; area of pial hemorrhage two inches in diameter over the right motor area; moderate subarachnoid serous effusion confined to the vertex.

CASE CCXVIII. *Symptoms.*—Patient thrown from his truck, his head striking the pavement. Primary and permanent unconsciousness; respiration slow and stertorous; face intensely cyanotic, pupils normal, no muscular symptoms; wound in right occipital region; temperature, 97°; pulse, 108 and weak; respiration 13. Coma deepened, surface grew cold, pupils dilated, temperature was unchanged, and death occurred in fifty minutes.

Lesions.—No fracture; skull thick. Epidural hemorrhage in middle fossæ extending over occipital lobes. Brain œdematous. The liver was ruptured with much abdominal hemorrhage.

CASE CCXIX. *Symptoms.* — Primary and permanent unconsciousness; wound in left frontal region and compound fracture of left leg; pupils normal but irresponsive, head and eyes turned to the right, twitching of the left corner of the mouth, abdominal reflexes absent, no hemorrhages, and radial pulsations symmetrical. Death occurred in thirty-six hours with no change in symptoms but progressive asthenia. Temperature rose progressively from 96.8° to 105°; pulse, 108–190; respiration, 20–70.

Lesions.—No fracture; skull very thick. Large pial hemorrhage covering whole brain, except left frontal

lobe; clot thickest in right parieto-occipital region; no laceration; general hyperæmia and œdema.

CASE CCXX. *Symptoms.* — Patient jumped from a second-story window; primary and permanent loss of consciousness, which was complete; hemorrhage from both nostrils; dilatation of both pupils; no muscular symptoms. On arrival of ambulance, respiration was four to five in the minute, and was said not to have been more frequent from the moment of injury; it became more infrequent before reaching the hospital, and was finally not more than one in the minute. Death occurred a few moments after admission and in from forty-five to fifty minutes after the injury was received. The pulse was full and strong and of normal frequency for a little time after the cessation of respiration.

Lesions.—No fracture; wound in left occipital region with large hæmatoma; no epidural hemorrhage; pial hemorrhage covering whole surface of brain, vertex and base, and extending over pons and medulla. No laceration; contusion of inferior surface of left temporal and frontal lobes; general hyperæmia and œdema of the brain.

CASE CCXXI. *Symptoms.* — Patient fell during a brawl and struck his head upon the pavement; was taken home unconscious; hemorrhage from nose and mouth and hæmatemesis; admitted to hospital fifteen hours afterward; still unconscious, stertor, general muscular rigidity, dilatation of right pupil, and contraction of the left, both irresponsive to light; œdema of left conjunctiva, ecchymosis of left eye, fracture of nose, and patellar reflex increased. The respiration became sighing, the patellar reflexes were lost, and the urine was retained. Two hours and more after admission, respiration suddenly ceased, the face became cyanotic, and the pulse was full, regular, and bounding. The patient had an emission of semen and a gradually developed priapism; artificial respiration was continued four hours. When artificial respiration was interrupted, the abdominal muscles be-

culty, and suddenly sank to the floor unconscious. He had not fallen or been knocked down, but had been hard hit. On admission to the hospital, coma, stertor, Cheyne-Stokes respiration, dilatation of right pupil with no reaction to light, sluggishness of left pupil, no hemorrhages or external injuries, and twitching of the left arm and leg, which increased and was followed by spasmodic movements of both sides, with the head occasionally carried toward the left shoulder. Trephination disclosed subdural hemorrhage, and much fluid blood was evacuated. Tremors of the arms and legs increased during the operation, and afterward ceased; the respiration became regular, and the pulse increased in frequency; a little later there were several general convulsions; urinary control was lost, and slight left facial paralysis was apparent; convulsions occurred at intervals, the respiration became again of the Cheyne-Stokes character, and death occurred at the end of twenty-four hours. The temperature on admission was 98°, rose to 107.2° after the operation and was reduced to 103.4° by the ice pack, rose again in an hour to 107.2°, and remained persistent to that degree except as it was from time to time reduced by the ice application, until the last hours of life, when it fell to 106°. The pulse was 54 on admission, and after operation was 120 to 140, and respiration 30–42. The temperature increased post mortem from 106.2° to 106.4°.

Lesions.—No injuries of the scalp or cranium; no epidural hemorrhage; slight pial hemorrhage over the posterior part of the hemispheres and in moderately large amount upon the tentorium and in the posterior fossæ; central laceration in the posterior part of the left optic thalamus, five-eighths by three-eighths of an inch in its diameters, and mainly a disintegration, not much clot; general contusion of the brain substance, well-marked hyperæmia and œdema. The pial hemorrhage was larger upon the right side and the blood was fluid. The cardiac walls were moderately thickened.

CASE CCXXIV. *Symptoms.*—Patient fell down a flight of stairs; on admission to hospital, semi-conscious and irritable when aroused. Hæmatoma of right frontal region, and ecchymosis of right eye; slight hemorrhage from nose; dilatation of right pupil, which was irresponsive to light; no muscular symptoms. He remained in a restless, delirious, or stupid condition till his death on the seventh day. There was loss of urinary control on the fourth day, and coma, with picking at the bedclothes and subsultus tendinum during the last twenty-four hours. The temperature, which was 98.2° on admission, rose slowly and progressively to 102° on the fifth day, to 104.2° on the sixth day, and to 105.2° one hour before death, and thirty minutes post mortem to 106.4°. The pulse was 50–100 for five days, and afterward 120–130; the respiration was 20–24 for five days, and then 30–50.

Lesions.—No fracture of skull, and no epidural hemorrhage; no superficial laceration; pia mater and cortical vessels very much congested; some opacity of arachnoid membrane, and moderate subarachnoid effusion; no pial hemorrhage; limited cortical contusion, area of one inch in diameter, at bottom of left fissure of Sylvius; laceration of left optic thalamus in its central portion, at junction of middle and posterior thirds, one-fourth of an inch in diameter and filled with clot. Subcortical lacerations of the left side of the pons, one-third of an inch in diameter, in the transverse fibres; a few punctate extravasations in different parts of the brain; general hyperæmia, and well-marked œdema.

CASE CCXXV. *Symptoms.*—Primary and permanent unconsciousness following a fall of twelve feet; on arrival of ambulance, pupils normal, and left radial pulse fuller and stronger than the right. On admission to hospital, hæmatoma in right parietal region; temperature, 97.4°; pulse, 70; respiration, 28; left hemiplegia, and loss of fæcal and urinary control; incision of hæmatoma disclosed no fracture. Temperature in six hours, 97.6°; in

eight hours, 99°; in ten hours, 99.4°; and in thirteen hours, 109°. Death occurred fifteen minutes later, and temperature one hour post mortem was 109.4°; pulse, 74–150; respiration, 30–60.

Lesions.—No fracture; no epidural hemorrhage; laceration of right parieto-occipital region, and large cortical hemorrhage covering the whole vertex; excessive general cerebral hyperæmia and œdema.

II.

CASES UNVERIFIED BY NECROPSY.

CASE CCXXVI.—Male, aged forty years, fell down five steps of a stairway; had hemorrhage from the right ear, but walked home; two convulsions next day, and patient then taken to hospital, stupid, muttering, and with continued hemorrhage from the ear. Two other convulsions followed, most marked upon the right side. On the third day he remained in a stupid condition, incoherent, and irrational, getting out of bed to urinate and using another patient's shoe or the floor of the ward indifferently, and was transferred from St. Vincent's to Bellevue Hospital. The temperature on admission to St. Vincent's was 101.2° and declined to 100.6°, with a pulse of 60. He became violently delirious at Bellevue two days later, and afterward his mental condition was normal. It was said by his family that he had not been drinking at the time of the accident.

CASE CCXXVII.—Male, aged twenty-two years, fell three stories; primary loss of consciousness; contusions of right side of head and face, hemorrhage from right ear and mouth; pulse full, slow, and sixty per minute; breathing labored, and pupils normal; consciousness regained on the sixth day; patient restless, and when disturbed irritable from the first day. During the second week, mental condition variable and articulation somewhat in-

distinct. In the third week, the temperature became normal, the mind clear, and a swelling of the left side of the face which had been observed from time of admission to the hospital increased and later disappeared; right lower facial paralysis became evident. In the fourth week, articulation was again indistinct, and the mental condition weak. The patient when asked about the manner of his injury talked of taking a basket of clams from Koster and Bial's, whom he called "Kosher and Beel" or "Kosher and Clams"; his laugh was silly, his manner indicated dementia, and he had delusions. In the fifth week his mind suddenly became clear, he conversed rationally, and he remembered all the circumstances attending his accident. At this time he was removed from the hospital. The temperature became normal on the fifth day and did not afterward exceed 99°; it was oftener 98°.

CASE CCXXVIII.—Male, aged thirty years, fell from elevated railway track, striking upon left side of his head and face; slight hemorrhage from right ear; consciousness not wholly lost; pulse and respiration slow. On the following day he sufficiently recovered consciousness to discover loss of vision in the left eye; he responded slowly to questions, and was somnolent. Examination of the eye made by Dr. Callan on the fourth day: Left pupil not responsive to light on direct exposure, but contracted with its fellow when both were simultaneously exposed; retinal examination negative; optic nerve believed to be implicated in a fracture passing through optic foramen. Ninth day, pain in the head behind the right ear and above the left eye, and incomplete left facial paralysis involving the tongue. Sixteenth day, sero-sanguinolent discharge from both ears since the tenth day; mind clearer, with loss of memory; commencing atrophy of the left optic nerve. The discharge from the ears ceased on the eighteenth day. The temperature on admission was 99°, immediately rose to 100°, and afterward ranged from 98° to 99°.

The patient, a man of unusual intelligence, said when discharged from the hospital at the end of the second month that in the sixth week he began to recollect the circumstances which had attended his accident, and that since then the mental confusion from which he suffered had gradually disappeared.

CASE CCXXIX.—Male, aged thirty years, struck by a falling ladder; hemorrhage from mouth and nose, and blood and brain matter exuded from right ear; both eyes protruded, and both pupils were contracted and irresponsive to light; right facial paralysis; respiration stridulous. Right pupil soon began to dilate slowly. Temperature, 100°; pulse, 93; patient remained unconscious till death two hours after injury.

CASE CCXXX. — Male, aged twenty-three years, walked out of a window while sleeping and fell three stories to a stone pavement below, striking an iron fence on the way. He remained unconscious from fifteen to twenty minutes. On admission to hospital, a very profuse serous discharge began from the right ear and continued for several days. Pupils and respiration normal; severe vertigo, aggravated on attempting to arise or on opening his eyes; several attacks of vomiting; temperature, 99°; pulse, 90. On the fourth day he had incomplete upper and lower facial paralysis, which continued for a week's time. On the eighth day he had three general convulsions, and one on the next day. On the twentieth day he began to have severe pain in the right ear, and as later the mastoid region became swollen and inflamed it was trephined for exploration, with negative result. The temperature but once exceeded 99°. The mastoid inflammation disappeared at once after trephination. Recovery was complete.

CASE CCXXXI.—Female, aged forty-seven, fell on the street in a convulsion during a debauch; had other convulsions before admission to hospital; left side of head and eyelid much contused; mental condition stupid; pupils nor-

mal; breathing stertorous; pulse, 108; convulsions continued during the day and night; no interval of consciousness. During the morning a severe hemorrhage occurred from the mouth without previous warning. In the afternoon pulse and respiration became frequent. The blood which came from the mouth was bright in color, non-aerated, and said to be more than eight ounces in amount. The next day the convulsions were diminished in frequency and were general, but more severe in the right arm. No initial symptom noted. Both arms were rigid and head constantly turned to the right. There were in all twenty-three convulsions. Death occurred in thirty-eight hours. Temperature, one hour after admission, 102.4°; morning of next day, 105.6°; later, 107.4°, 106.2°, 107.8°—the last observation one hour before death.

CASE CCXXXII.—Male, aged twenty-four, fell down stairs; wound over right eye; hemorrhage from right nostril, coma, stertor, pupils contracted; temperature, 98.5°; pulse, 120; no paralysis or muscular rigidity; reflexes normal; fracture of left thigh. Clonic spasm of left side five hours after admission. Death in ten hours after reception of injury. Hourly temperature, 100°, 101°, 102.4°, 102.4°, 103°, 104.4°, 105°, 106.4°. Thirty minutes post mortem, 108.8°.

CASE CCXXXIII.—Male, aged sixty, knocked down by a truck; scalp wound in right posterior occipital region. A linear fracture running backward and downward was discovered by incision. Patient unconscious and restless. Pupils contracted; pulse, 66; very slight movements of right side of body; no facial paralysis; speech only in monosyllables. In a short time right hemiplegia became complete, pulse weaker, temperature lower, and there was a slight general convulsion lasting about ten seconds. Four hours later, coma was profound, pupils small and irresponsive, pulse and respiration very irregular, and restlessness ceased. The patient was trephined over left motor area. The fissure was found to extend

downward behind the mastoid. Epidural hemorrhage was disclosed, and, after incision of dura, subdural hemorrhage. He died three hours later, and eleven hours after reception of injury.

CASE CCXXXIV.—Male, aged forty years; cause of injury unknown; contusions behind both ears; free hemorrhage from right ear, and during the night from both ears and mouth; pupils contracted; pulse full and slow; breathing labored; temperature, 99.2°; became 105°. He did not regain consciousness, and died six hours after admission.

CASE CCXXXV.—Male, aged twenty years; fell thirteen feet; large hæmatoma in left posterior parietal region; unconscious; oozing from left ear and nose; pupils contracted, and eyes turned persistently to the right; mouth drawn slightly to the right; breathing irregular; vomiting free; extremities cold and muscles relaxed; urine incontinent; temperature, 99.5°. Soon after admission hemorrhage from nose ceased, but continued from ear. Patient could be roused partially but with difficulty, became restless, and moved his right side rather less freely than the left. Temperature, 101°. Two hours after admission to the hospital breathing became stertorous and tonic spasms, beginning in the right arm, became general. Two attacks of opisthotonos followed, and ceased after thirty minutes. Left pupil became the larger, while the right eye still turned to the right on exposure. Temperature, 105°; pulse, 96; respiration, 32, and of the Cheyne-Stokes variety. An hour later, coma was profound, with slow and stertorous respiration. Temperature, 106.6°. Respiration became insufficient, four to the minute, and face cyanotic. Death occurred in four hours. Pupils post mortem were widely dilated.

CASE CCXXXVI.—Male, aged forty years, fell two stories and struck his head upon the pavement; no loss of consciousness, but primary delirium; wound in the left temporal region; hemorrhage from mouth and nose;

normal pupils. The delirium, which continued four days, was succeeded by indications of mental disorder; confusion of ideas, loss of memory, delusions, and at a later period slowness of comprehension. The patient at the time of his discharge from the hospital, in the second month, when questioned, would long remain buried in thought, and his answer when made would be slow and halting though coherent. He never had knowledge of the manner of his injury, and only at the last recognized his surroundings. There were no other than mental symptoms after the first week. On the second day, the surface of the right side, which was in much more active motion than the left, was warm, while that of the left was cold, and the right axillary temperature was 0.6° higher than the left. There was also dysphagia. On the third day, there was post-cervical rigidity; and on the third and fourth days lack of fæcal and urinary control. The temperature only once exceeded 100°+, and was then 102.2°. The right axillary temperature was 0.4° to 0.6° higher than the left during the first week, and at a later period the left was usually 0.2° higher than the right, but not with uniformity. The pulse was 66–98, and the respiration 20–26.

CASE CCXXXVII.—Female, aged thirty years, was struck upon the head by a piece of board which had fallen thirty feet; primary unconsciousness; compound fracture of right parietal bone in its anterior and superior portion; trephination; longitudinal sinus had been wounded by an osseous fragment. Examination made fourteen months later: Loss of bone substance in an area one and one-fourth inches by three-fourths of an inch, just to the right of the median line at the fronto-parietal junction; open fissure felt through the skin extending from this point through the median line into the right orbital plate; loss of sense of smell, and deficient sense of taste, on the right side.

CASE CCXXXVIII.—Male, aged forty years, fell from

a truck and struck upon his head; partial loss of consciousness; profuse hemorrhage from right ear; wide dilatation of left pupil; temperature, 99.8°; pulse, 92; and respiration, 23. Second day, slight delirium, mental stupor, no response to questions; temperature, 100.8°. Third day, severe general convulsion, beginning in left arm and hand; both pupils afterward widely dilated; temperature, 100.2° to 100.6°. Fourth day, similar convulsion, but less severe; temperature, 99.8° to 100°. Eighth day, mind clear, but torpid; no recollection of an accident having occurred; speech slow and somewhat aphasic; headache and continued dilatation of pupils. Twelfth day, mental condition normal; temperature, 99°+. Discharged without further symptoms on the twenty-ninth day.

CASE CCXXXIX.—Male, aged fifty-five years, fell unconscious in the street. On admission, profound shock and entire unconsciousness; wound of scalp in right posterior parietal region; free hemorrhage from right ear and uniform contraction of pupils One hour later, rigidity of left arm and, to a less extent, of left leg. Consciousness restored in twenty-four hours, and a little later the pupils became normal and the mind clear. Temperature on admission, 98°, declined to 97.4°, and rose in twenty-four hours to 99.4°; pulse and respiration normal. On the third day, temperature, 99.6°, and only psychic symptoms; mental processes a little less slow than on the previous day, but memory defective. No recollection of anything which happened after leaving home in the early morning, some hours pevious to the accident; memory of words and facts equally deficient. Upon questioning, the patient said that he lived at "No. 4 in the Ninth Ward;" then remembered that it was opposite a school, which he called "skull," and finally that it was in Grove Street. On the following day he had again forgotten the name of the street, and its mention awakened no remembrance; he misplaced many words, and could not be brought to recognize his errors. A week later he had much general head-

ache, realized that his mind had been greatly confused, and was still ignorant of all that had happened since leaving his house. He was discharged on the eighteenth day, his temperature and mental condition having been normal for several days.

CASE CCXL. — Male, aged forty-five years, thrown from a truck in collision; admitted to hospital in shock and still unconscious; pupils contracted; temperature, 97.5°; pulse, 52; respiration, 18; twelve hours later, temperature, 97.5°; pulse, 50; respiration, 12; in fourteen hours consciousness restored; temperature, 98°. Second day, no recollection of injury, previous occupation, or married condition. Third day, ecchymosis over right mastoid process and extending upon the back of the ear, not previously apparent. Fourth day, the patient, after much questioning and trouble, was enabled to remember his residence and occupation; temperature, 102°. During the rest of the week his temperature declined and mental condition improved, though he was still irrational and at night required mechanical restraint. In the second week he was rational at times; he was capable of expressing the generalization that a man's mind is clearer by day than at night, and described correctly the manner in which he received his hurt, though he again forgot the circumstances and denied that he had said anything about it; he was irritable and forgetful, even of the outrage to which he considered himself subjected in the taking of his temperatures; he had delusions, saw imaginary persons, and heard unreal voices, made contradictory statements about the injury which he had suffered, and was much annoyed at the attempts which were made to get from him some coherent and consistent history. Early in the third week his temperature became normal, his memory and other mental faculties were restored, and he was discharged from the hospital.

CASE CCXLI. — Male, aged forty-five years, mind impaired by alcoholic excess, fell one flight of stairs; con-

sciousness retained, hæmatoma in left temporal region, profuse hemorrhage from left ear, and slight epistaxis. Temperature, 98°; pulse, 90; respiration, 24. Second day, a little delirium, rigidity of both arms, and left facial paralysis both upper and lower; temperature, 100.2°; pulse, 100; respiration, 24. Incision made through hæmatoma revealed linear fracture of left squamous portion extending into the base. In the three days following, the temperature and mental condition became normal and facial paralysis nearly disappeared. Two days later temperature rose to 100.5°, facial paralysis increased, left side of face and neck became swollen, and delirium supervened. From this time there were recurrent maniacal attacks, lasting less than twenty-four hours, in one of which he was transferred to Bellevue Hospital and soon afterward escaped. He was at a subsequent period sent to an asylum for the insane, and sixteen months later was still of unsound mind.

CASE CCXLII.—Male, aged thirty-five years, fell one story; brief unconsciouness followed at once by delirium; extensive lacerated wound in left parietal region; hemorrhage from left ear caused by wounds of external meatus. Temperature on admission to hospital, 101.5°; pulse, 80; respiration, 18. Delirium continued three weeks, gradually diminishing in degree and constancy; no subsequent recollection of the manner of injury. Loss of urinary control lasted one week; no headache at any time, and no later symptoms. Patient recognized his family and surroundings after three or four days.

CASE CCXLIII.—Female, aged five years, struck by a falling box which seemed to have crushed her head laterally against the floor. Still unconscious at time of admission to hospital, but very sensitive to external irritations; slight twitching of right side of the face, slight epistaxis, slightly accelerated respiration, slow and irregular pulse; temperature, 95°; pupils sometimes normal, sometimes widely dilated, with conjugate deviation which was some-

times upward and sometimes to the left; vomiting after reception of the injury; hæmatoma over entire tex, and contusion of both eyes. Incision disclosed sures on either side of the calvarium; one extended the left temporal fossa posteriorly across the vertex t right occiptal region, and anteriorly into the ant fossa; another, apparently beginning in the right ant fossa, crossed the right parietal bone and terminate the first. The bone was depressed posteriorly and th sures were open; after elevation and removal of small fragments considerable epidural hemorrhage wa parent. Consciousness was fully restored within tw four hours, and was marked by restlessness and deli which continued for two or three days, after which mental condition was normal. On the fifth day parap occurred, which was almost complete from the first, absolute on the next day, with partial anæsthesia paralysis of the bladder or rectum. The paraplegic dition began to improve at the end of a week's time very slowly; a few steps could be taken without assist six weeks later. The température soon after admi rose from 95° to 98.5°, on the next day to 100.2°, and the third day varied from 98.4° to 99.8°; usually no in the morning. The respiration was accelerated fo first ten days, and the pulse frequent for three days.

Case CCXLIV. — Female, aged thirty years; thrown from a wagon while driving, striking the bac her head upon an asphalt pavement; shock, loss of sciousness for twenty minutes, and severe vomi which persisted during the day; temperature, 100°; taken afterward; hæmatoma in right occipital region, ecchymosis behind the right ear, followed by severe l ized pain in the right side of the head posteriorly. later symptoms were a muffled feeling in the right with diminished hearing and blunted perceptions of and smell which had been noted from the time of the dent. The disorders of hearing did not continue

the fourth week, but the senses of taste and smell have been permanently impaired.

CASE CCXLV. — Male, aged thirty-six years; fell ten feet from a vessel to a raft alongside and then into the water; brief period of unconsciousness, profuse hemorrhage from left ear, slight epistaxis from left nostril, and hæmatoma in left mastoid region; single general convulsion in the ambulance followed by stertor; consciousness regained at time of admission; both pupils widely dilated; hemorrhage from the ear recurred during the night; urine retained; temperature, 98.8°. Frontal headache continued for several days, and on the third day there was transient photophobia with contracted pupils. The bladder and rectum were controlled. Dilatation of the pupils was perceptible till the end of the second week and of the right pupil even longer. The prominent symptoms were mental; nocturnal restlessness and delirium, and a rather stupid condition during the day, were succeeded in the second week by continued delirium of a mild type with delusions. In the third week active delirium ceased, though restlessness at night persisted; the facial expression was more intelligent and speech was coherent; there was perfect recollection of the manner in which the injury had been received, and also of a similar accident which had occurred on the same day and aboard the same ship, but delusions were numerous and constant. At the beginning of the fourth week the patient was restless, excitable, talkative, and had again forgotten the manner and even fact of his injury. Ophthalmic examination was made by Dr. Callan with negative result. At the end of the fourth week delusions finally ceased, and when discharged from the hospital in the eighth week there were no symptoms remaining. The sense of smell was entirely lost.

The maximum temperature was on the fourteenth day, from 101° to 102.2°; the usual temperature was 99°+ till after the fourth week, and then varied from normal to

99°. The axillary temperatures were observed from th fourth to the eighth weeks; the left was habitually, b irregularly, higher than the right. The pulse and resp ration presented no notable changes.

CASE CCXLVI. — Female, aged seventeen years, fe from second-floor window; found in coma with profu hemorrhage from left ear and some hemorrhage from th mouth; left side of face, eye, and parietal region muc contused. Two hours later consciousness was partial restored and sensitiveness to external impressions reco ered; hæmatemesis occurred, and at a later period, aft subsidence of ecchymosis of the lids, subconjunctival her orrhage in the left eye was discovered; the right pup was dilated. Six hours after admission to hospital, tem perature, 97.4°; pulse, 70; respiration, 38; lack of urina control. The hemorrhage from the left ear continued f thirty-six hours, and was followed by a discharge bloody serum. During the first three or four days th patient was at times noisy and restless and at times qui She then became rational and learned for the first tim that she had met with an accident and was in a hospita but she never knew, then or afterward, of her own rec lection what had happened to her. At about the sam time a protrusion of the left eye became marked, and was discovered that vision was lost on that side. The were no additional symptoms. The temperature on th second day was 100.2°; pulse, 68; respiration, 18; a temperature afterward varied from 99° to 100°+.

At the end of the fourth week ophthalmic examinati was made by Dr. Callan. The right eye was in respects normal. The left eye was on a slightly anteri plane to that of the right; its movements were unim paired; there was a slight remaining trace of hemorrha near the limbus corneæ; the pupil was moderately dilat and not responsive to direct rays of light, but acted co sensually with the right; there was commencing atrop of the optic nerve and total loss of vision. From th

clinical history Dr. Callan was of opinion that a line of fracture had implicated the left optic foramen.

CASE CCXLVII.—Male, aged forty years, found in the street in an alcoholic condition; could walk with assistance; profuse hemorrhage from left ear; slight œdema of scalp in left occipital region; no general symptoms. The recollection of having been brought to the hospital and of previous wanderings, but not of the manner of injury, returned with sobriety. Ecchymosis of both lids of right eye appeared on the following day; vertigo and occipital headache and some pain behind the left ear existed for ten days. Temperature on admission, 98.4°; rose to 101° in the course of eighteen hours, and was afterward 99° to 100°+ during the three weeks the patient remained under observation. The axillary temperatures were usually symmetrical, and when any difference was noted it was higher on the left side. The pulse more frequently exceeded 90 or 100 than is usual in similar cases. The respiration was normal.

CASE CCXLVIII.—Male, aged fifty years, fell twelve to fifteen feet from a loft and struck upon the back of his head, six hours previous to admission to hospital; unconscious fifteen minutes; contusion of the vertex in the median line; wound in right occipito-mastoid region; hemorrhage from right ear; delirium from time consciousness was restored, often requiring mechanical restraint; dilated pupils, and right radial pulse fuller and stronger than the left; the urine was retained and the right hand and wrist were paretic. There was marked aphasia—*e.g.*, the patient said "talp that" for stop that, "guth Got" for good God, and "15 Avenue B" when asked his name. The difference in the fulness and strength of the radial pulses continued to be strongly marked at all times till death on the eighteenth day. The dilatation of the pupils, which remained sensitive till the seventeenth day, was also permanent. Delirium persisted, and speech was infrequent and unintelligible till the close of the first week; the mental condition

then became brighter and speech distinct and coherent, but delusions were constant and the patient was at no time able to recognize his family or friends. There were subsequent alternations of restlessness and excitability with somnolence or lethargy, but no cessation of delirium, delusions, and more or less incoherent and unintelligible speech, till final unconsciousness, which occurred three days before death. Sensitiveness to external irritations was marked throughout this later stage. The control of urine and fæces was permanently lost during the first few days. The paresis of the right hand was much diminished during the first week. On the sixth day, and on the seventh, there was a short, severe, convulsive attack, followed by a transient high temperature. These were succeeded on the morning of the eleventh day by a general convulsion, which was at first confined to the upper extremities, and continued twenty minutes; the right arm was less rigid than the left. Another attack in the afternoon of the same day, of twenty-five minutes' duration, began with a twitching of the facial muscles, and was extended to the trunk; all the extremities remained rigid; the face was of a natural color, though subsequently much flushed, but the hands were blue. The morning convulsion was followed by prolonged unconsciousness, that of the afternoon by an apparently natural sleep after a short interval in which the mind was unusually clear and alert. There was another very brief general convulsion five days later. Posterior cervical muscular rigidity existed from the ninth to the fourteenth days. The temperature on admission was 101.8°, and varied from 100°+ to 101°+ till the fourth day, when, without other change in symptoms, it rose to 104°, and in the twelve hours following declined to 101°+, and was continuous at about that degree till the tenth day, except at the time of the first and second convulsive attacks, when it rose for a short time to 106° and 106.6°; on the morning of the tenth day it rose to 105°, again declined to 101°, and with the occurrence of

the third and fourth paroxysms on the eleventh day it rose to 105.4°; on the twelfth day it declined for a brief interval to normal, and was subsequently uniformly high from 103° to 106°, and at death was 108°. In fifty-two observations the right axillary temperature was higher than the left in thirty-two, the left higher than the right in seven, and in thirteen the two were uniform; the variation was from two-tenths of a degree to a degree and eight-tenths. The pulse on admission was 112, and then, for the first ten days, 65 to 100; never afterward below 120. The respiration on admission was 36, and after the first four days rarely below 32.

CASE CCXLIX.—Male, aged thirty-eight years, admitted to hospital in an alcoholic condition without a history; profuse hemorrhage from the left ear. The patient never afterward remembered having been hurt. During the first week hearing was greatly impaired in both ears, and there was much mental confusion, with sensory aphasia and general loss of memory. General headache was severe and vertigo marked. The patient was enabled to recollect with great difficulty the place of his employment, and could only suggest his occupation as a waiter by using an imaginary corkscrew in dumb show. The right radial pulse on the second day was fuller and stronger than the left. In the second week hearing was quite restored in the right ear and was nearly recovered in the left. The mental condition became normal, and there were no further symptoms. The temperature on admission was 99.2°, and did not subsequently exceed 100°+. The left axillary temperature was two-tenths of a degree higher than the right when there was a lack of symmetry. The pulse on admission was 80, and was only once above 100. The respiration was from 18 to 24.

CASE CCL.—Male, aged forty years, fell six feet into an area way; consciousness lost, and not restored at time of admission to hospital, but sensitiveness to external impressions retained; profuse hemorrhage from right ear; left

radial pulse fuller and stronger than the right; pupils contracted, but responsive to light; right corneal reflex diminished; right side and right face paretic, and urine retained. The pupils became normal on the second day, and the radial pulses symmetrical on the third, with some signs of returning consciousness. Convulsive movements of the extremities occurred on the fourth day, and there was some dysphagia. The patient gave little evidence of intelligence till the end of the fourth week; he had no power of speech beyond the utterance of an occasional single word, and when his attention could be attracted, which was not often, replied only in inarticulate sounds; he rarely recognized his immediate family, and had no apparent comprehension of what was said to him. The right facial paralysis continued, with added ptosis of the left eye, and both pupils became dilated. His mind then became clearer, but intelligence was very limited; he articulated several words with moderate distinctness, and a little later used several short phrases with propriety; a little later still his attention could be momentarily fixed to comprehend, and answer monosyllabically, a simple question. An ophthalmic examination made by Dr. Callan disclosed no retinal changes. At the end of the sixth week he began to notice what went on about him, recognized his mother, and developed destructive tendencies. Early in the seventh week he first gave attention to the natural offices of the body, and his increasing range of words accentuated his aphasia. After the second month there was only a trace of facial paralysis, and no other paretic condition. He could dress himself, and went about the ward; he could remember, and could write his name and address correctly, and seemed readily to understand such questions as were asked him, but replied in an endless tirade which was incoherent and largely made up of inarticulate sounds interspersed with recognizable words, and apparently as devoid of meaning to himself as to the listener. He was unable to write from dictation more than a few words be-

fore the written characters became incomprehensible, and he repeated words. He had no knowledge of his occupation, manner of injury, or local surroundings. He was discharged at the end of the third month, and had then upon cursory examination no symptoms of mental disorder remaining, except some hesitancy in collating words, and in long sentences a little confusion in expression. If an attempt was made, however, to engage him in a sustained conversation, his thoughts became more and more entangled; he talked rapidly and excitedly, and his words were inextricably jumbled together. On examination, four months later, his mental condition was that of dementia.

The temperature on admission was 98.4°, and reached its maximum, 102.6°, on the second and third days. It then gradually but irregularly declined. It was occasionally normal after the first week, but ordinarily 99°+ or 100°, quite up to the time of the patient's discharge from the hospital. The right axillary temperature was the higher twenty-two times, and the left twelve times, and the two were uniform once, in thirty-five observations made during the first nine weeks. The left was afterward usually two-tenths to four-tenths of a degree the higher. The pulse did not exceed 90 after the fourth day, and the respiration was at no time more than 22.

CASE CCLI.—Male, aged forty years, fell ten feet to a ship's deck; consciousness lost for twenty minutes and both pupils dilated. On admission to hospital, hemorrhage from the right ear and nostril, right pupil dilated, stupor, and temperature of 97.6°. The right radial pulse at this time was 92, and the left 100, in the minute. The temperature and pulse became normal in three hours; no further symptoms except frontal headache; no memory at any time of having been injured.

CASE CCLII.—Female, aged thirty-two years, fell down a companionway on board ship, was found unconscious, and on admission to hospital thirty minutes later

was in stupor, with profuse hemorrhage from left ear an moderate hemorrhage from both nostrils; pupils norma radial pulsations symmetrical, and no muscular disorder temperature, 98.4°: pulse, 60; and respiration, 20; th right axillary temperature was 96°, and the left 97.8 Later symptoms were somnolence, recurrence of hemo rhage from the ear, frontal headache, left facial paralysi and intermittent active delirium, which became constan The temperature gradually increased to 101°+, the puls was 58–82, and the respiration 20, 18, 26. On the fift day, delirium increased with continued pain in the hea and the temperature rose from 101.6° to 105.2°: on th seventh day the left pupil was contracted, and a few hou later active delirium was succeeded by stupor, wide dilat tion of right pupil and slight dilatation of the left; th temperature, which had receded to 103.4°–103°, rose 106°, and the pulse, which had ranged from 59 to 68, w accelerated to 160, and the respiration to 60. Death o curred at the end of the eighth day; temperature, 107.8 with immediate post-mortem recession.

CASE CCLIII.—Male, aged fourteen years, fell twel feet, striking upon his head; primary loss of consciou ness; no other general symptoms. On admission to ho pital, sensitive to pain, with protrusion of both eye rigidity of left upper extremity, and paralysis of the righ and compound fracture of left parietal bone, depresse and extending into occipital inferior fossa; osseous fra ments elevated. Temperature on admission, 97.6°, ro in two hours to 101°; pulse 76–80; respiration, 2 Later, rigidity of left arm disappeared, paralysis of le continued; eyes turned to left; loss of urinary contro restlessness and unconsciousness; temperature rose pr gressively to 108° at the time of death in fifty hours, wi immediate post-mortem recession; the pulse and respir tion were also progressively accelerated.

CASE CCLIV.—Male, aged thirty-five years, found u conscious at the foot of a flight of stairs. On admissi

to hospital, complete loss of consciousness, hæmatoma above and behind right ear, free hemorrhage from right ear which continued five hours, left pupil dilated and immovable, right pupil contracted but responsive to light, respiration very irregular, right radial pulsations fuller and stronger than the left, retention of urine, breath alcoholic; and a little later, hemorrhage from the right nostril. Temperature, 96.4°; pulse, 66. On the second day, sanguinolent discharge followed by brain matter, which continued through the day and was seen to ooze through a perforation in the tympanum; radial pulsations symmetrical in the evening. On the third day, discharge from the ear was serous, left pupil was contracted, and restlessness continued. During the week following, the right and left radial pulsations were alternately the fuller and stronger, except as at times they were symmetrical; there was slight left internal strabismus, the mental condition was normal except for occasional delusions, and the left pupil was appreciably dilated. There were no later symptoms save occasional diplopia, and a persistent delusion that he was a workingman and anxious to return to his work. The man was evidently sincere, but a typical tramp, who never worked, and in his right mind entirely incapable of associating such an idea with himself. The temperature became normal three hours after admission, and rose to 102° on the second day; it varied from 99°+ to 103°+ on the third and fourth days, from 102.8° to 100.8° on the fifth, sixth, and seventh days, from 101.6° to 99.6° till the twelfth day, from 100.2° to 99.8° till the eighteenth day, and afterward from 99.8° to 99.6°; pulse, 112 to normal; respiration, 12 to 40—ordinarily, 20–24.

CASE CCLV.—Male, fell one flight of stairs while intoxicated. On admission to hospital next day, no external injuries, hemorrhage from right ear, somnolence, pupils normal; temperature, 100.4°; pulse, 100; respiration, 22. On the second day, vomiting, restlessness, and severe headache; on the fourth day, watery discharge from the

right ear; on the fifth and sixth days, delirium following restlessness and headache and becoming violent; pulse and temperature not increased; from seventh to tenth days, restlessness, delirium at times, and somnolence; from eleventh to sixteenth days occasional delusions, and daily periods of restlessness and active delirium; on seventeenth and eighteenth days, headache unusually severe; nineteenth day, temperature became and continued normal, and the memory of circumstances attending the injury was restored, but not that of subsequent events. Afterward there were some deafness and indistinctness of vision, and a slightly staggering gait with an inclination toward the left. The temperature rose on the second day to 104.2°, on the third and fourth days to 103°+, and on the fifth, sixth, and seventh days to 102°, with moderate recessions; it afterward gradually declined. The highest pulse was 112, on the fifth day, and did not exceed 70 after the ninth day. The respiration was only slightly accelerated.

CASE CCLVI.—Male, aged forty years, found unconscious at the foot of a flight of stairs, with hemorrhage from mouth and nose. On admission to hospital, loss of consciousness not complete; stertor; temperature, 97.4°; pulse, 64; respiration, 24; condition probably alcoholic; pupils sluggish and somewhat contracted; contusions of face and head, ecchymosis of both eyes and hemorrhage from mouth and nose; mental condition normal in twelve hours. Through the first week nocturnal delirium, mental confusion by day, limited frontal pain with some frontal œdema, which was evident on the first day; and at the end of the week exophthalmos of the left eye and contraction of the left pupil; temperature, 99°–100°; pulse, 60–52; respiration, 16–14. During the second week inequality of pupils persisted; an examination of the eyes by Dr. John E. Weeks showed that the ocular movements were limited except in a downward direction, that the pupils reacted to light, that the retinal arteries were apparently reduced in size, that the temporal half of

the retina was pale, and that vision was good; temporary disturbance of vision and exophthalmos were probably due to effusion into orbital tissue. An examination by Dr. Callan two weeks later showed pronounced pallor of the left optic nerve most marked on the outer side, retinal arteries decidedly reduced in size, nasal field restricted, and vision much diminished.

The temperature from the twelfth to the twenty-third day declined each day to 97°— or 97°+, usually from seven to nine o'clock in the morning, but occasionally in the evening. On the thirty-fourth day it fell to 96.6°; it exceeded 98.5° on but two or three occasions. The pulse was from 54 to 60, and the respiration 12–14.

The patient left the hospital with no symptoms but those of failing sight.

CASE CCLVII.—Male, adult, fell backward, striking upon the back of his head; walked to two other hospitals and afterward to Bellevue; when asked his name, he constantly reiterated, "four times;" he soon became incoherent, very restless, and required mechanical restraint; hemorrhage from left ear, and for a short time contraction of left pupil. Temperature, 102.4°, 104.8°, 103.6°; pulse, 68–120; respiration, 20–24. On the second day, coma, loss of urinary control, and death. Temperature, 104.4°, 108.2°, with immediate post-mortem recession; pulse and respiration frequent.

CASE CCLVIII.— Male, aged thirty-one years, fell twenty feet into ship's hold; primary unconsciousness. On admission to hospital, somnolence, vomiting, and hemorrhage from the left ear, which continued twenty-four hours; pupils slightly dilated. Temperature, 100.2°; pulse, 120; respiration, 25. The patient would begin to answer a question and suddenly stop short, and could give only the first part of his name, though he recognized the rest of it when it was told him. On the second day, vomiting, frontal pain, twitching of the fingers of the right hand when asleep, somnolence, and apathy. Tempera-

ture, 101°–99°; pulse, 115–80; respiration, 28–22. Hea
ache and delirium which were not constant continued ti
the eighth day, and occasional attacks of headache till th
end of the third week, when he left the hospital.

CASE CCLIX.—Male, aged twenty-six years, injure
by having his head caught in its occipito-mental diamet
between a descending elevator and an iron bar. On a
mission to hospital, hemorrhage from left ear, mouth
and both nostrils, consciousness unimpaired, and pain i
the head, most severe in the region of the left ear. The
were no external injuries, though the eyes were great
swollen and closed as a result of intracranial lesion
Temperature, 98°; pulse, 66; respiration, 18. No othe
symptom, except a little later hæmatemesis.

The swelling in the palpebral regions and the hemo
rhage from the ear gradually disappeared during th
week; the temperature rose to 101.4° on the second da
and then declined to normal, without further disturbance

CASE CCLX.—Male, aged forty-five years, fell eigh
teen feet, striking upon his head; primary unconsciou
ness. On admission to hospital, semi-consciousness, hem
orrhage from right ear, mouth, and both nostrils wit
hæmatemesis and no other symptoms. Temperature
97.4°; pulse, 100; respiration, 60. Consciousness was full
restored in ten hours; severe frontal pain persiste
till the sixth day, when it became occipital; no late
symptoms, and no headache when discharged from th
hospital on the eleventh day; highest temperature, 100.4°
pulse, 120–90.

CASE CCLXI.—Male, aged forty-five years, fell twelv
feet; transient primary unconsciousness. On admissio
to hospital, hemorrhage from right ear, slight dilatatio
of right pupil, pain in the right ear, nausea, and n
other symptoms. Temperature, 97.8°; pulse, 100; resp
ration, 24. One hour later, right radial pulse fuller an
stronger than the left. On the second day, frequen
vomiting, delirium; temperature, 100.4°–101.2°; pulse

96–100; respiration, 20–24. On the third day, mind clear, both pupils moderately dilated, the right more than the left, severe pain in the frontal region and right ear, and ecchymosis apparent in right mastoid region. No further general symptoms during the week. The patient when discharged in the second week had deafness in the right ear, impaired memory, and some mental aberration.

CASE CCLXII.—Male, aged thirty years, fell five stories, striking upon his head and shoulder; found unconscious; small hæmatoma in left frontal region, hemorrhage from both ears, nose, and mouth; right pupil dilated, muscular twitching in right arm, and fracture of right radius and ulna. On admission to hospital, patient restless and slightly delirious; fracture not disclosed by incision. On the second and third days, frontal pain, delirium, and lack of urinary control. On the fourth day there were noted an indistinctness of articulation, and a profuse perspiration, which continued at intervals while the patient remained in the hospital. The perspiration usually began about seven o'clock each evening and lasted two hours, but the time was not invariable. For several days the mental condition and urinary control were normal by day, with delirium and loss of urinary control each night. On the sixth day there were diplopia and internal strabismus, and on the seventh, the appearance of left subconjunctival hemorrhage. On the eighth day delirium ceased, and urinary control was permanently restored. On the tenth day examination of the eyes by Dr. Callan disclosed hyperæmia and blurring of both optic discs. The patient was removed from the hospital on the fifteenth day; at that time articulation was more distinct, but the perspirations were not diminished. The temperature was normal on admission and was afterward usually 99°+–100°+, occasionally rising to 101°–102°; the pulse declined from 112 to 88; respiration, 22–26.

CASE CCLXIII.—Male, aged fifty-five years, struck on the head by a descending elevator; dazed. On arrival of

ambulance, the patient was unable to speak, but had pe
fect comprehension of what was said and of all that we
on about him; compound linear fracture of left pariet
bone posteriorly and extending through mastoid proce
into posterior fossa; hemorrhage from left ear, mout
and left nostril; left pupil contracted; same conditions
admission to hospital. On the second day incomple
paralysis of the muscles of the lower face and tongue, a
later dysphagia, with pain in the head and restlessnes
The paralysis continued, with improvement in the gener
condition when discharged on the thirteenth day. Tem
perature, 98°, 100°+, 98° −; pulse, 78, 92, 76; respiratio
12, 26, 22.

CASE CCLXIV.—Male, aged eight years, knock
down by a bicycle; transient loss of consciousness, profu
hemorrhage from right ear, vomiting; temperature, 98
pulse, 98; respiration, 26. Hemorrhage ceased on t
seventh day; a later serous discharge continued when t
patient left the hospital on the twenty-sixth day; no oth
symptom except pain in the right side of the face a
ear; temperature once reached 103.4°, apparently fro
pain and a disturbance of digestion with constipation.

CASE CCLXV.—Male, aged twenty-four years, f
twenty feet, striking upon his head; no loss of consciou
ness and mental condition normal: compound linear fra
ture in left occipital bone; moderate hemorrhage fro
the left ear; no other symptoms. Patient walked to t
ward and was immediately seized with a severe gener
convulsion, followed by severe pain in the head whi
continued for one week. Temperature on admissio
100°, and did not afterward exceed that degree; puls
88–64; respiration, 20, 24, 16.

CASE CCLXVI.—Male, aged thirty-one years, w
struck by a brick which had fallen five stories; no oth
immediate general symptom but unconsciousness. A co
pound depressed fracture crossed the median line at t
vertex. Second day, there was accurate memory

events up to the time of injury, no recollection of anything that occurred afterward. Third day, fragments of depressed bone were removed, leaving an opening in the skull two by one and a half inches in its diameters; no lesion of dura mater or of the sinus. Temperature on admission, 104.4°; at time of operation, 100°; subsequently 99°+. Pulse and respiration at all times normal.

CASE CCLXVII. — Male, aged thirty-three years, struck on the head with a hammer and momentarily unconscious, after which he walked to the hospital. Compound depressed fracture of the mid-vertex; both pupils dilated; left radial pulse markedly fuller and stronger than the right till after operation, five days later; no other general symptoms. Depressed fragments of bone were removed, leaving an opening in the skull one and a half inches by one inch in its diameters; hemorrhage from a large wound of the longitudinal sinus controlled by gauze packing. Pulse and respiration became normal on the following day, and radial pulsations symmetrical on the third day. Elevation of temperature was maintained by a slough and inflammatory conditions produced by an accidental burn. Temperature on admission was 99.2°, rose in a few hours to 101.4°, and after the operation to 102°+; pulse and respiration, normal at first, were subsequently only moderately accelerated.

CASE CCLXVIII.—Male, aged eight years, kicked in the forehead by a horse; compound depressed fracture of right frontal bone, just above frontal sinus, and near median line; no loss of consciousness; depressed bone elevated and spicula removed, leaving an opening three-fourths of an inch in diameter; dura mater uninjured. Temperature normal to 99°+ till the fifth day, when it rose to 103°, and on the sixth to 104°; on the seventh day it declined to 102.8°, and on the ensuing four days was 101°; it was then 99°+ for ten days longer. On the fifteenth day there was a free discharge of serous fluid, and the patient, who for twenty-four hours had been som-

nolent, immediately aroused. On the twentieth day one or two drachms of laudable pus welled up through the wound, and a probe was inserted two and one-half inches directly backward and for the same distance along the external surface of the lobe. On the following day, under ether the dural opening was enlarged and from two to three ounces of pus were evacuated. The cavity was irrigated with sol. hyd. perchlor., 1–10,000, and drained by a tube. The temperature rose on the next day from 99.5° to 100.6°–102°, and on the third day declined to 100° and on the sixth to 99°; it was afterward 99°+ to 98.5°. No general symptom succeeded the operation except incomplete left lower facial paralysis; no mental disorder at any time. The facial paralysis disappeared on the tenth day. A fungus cerebri became evident on the seventh day; the wound was entirely healed forty-two days after operation.

CASE CCLXIX.—Male, aged forty-four years, was admitted to the alcoholic ward and next day transferred to the surgical service of the hospital. On admission he was completely unconscious, with rigidity of the muscles of left upper and lower extremities, and irregular pupils. On reception into a surgical ward consciousness had been in part regained and rigidity had been replaced by left hemiplegia and hemianæsthesia; there were abrasion of the nose, contusion of the left eye, and œdema of the right occipito-parietal region. On the fifth day hemiplegia had become complete, movements from the bowels were conscious but involuntary, and speech was rambling; the mental condition was otherwise normal, and the patient's explanation of his hurt, that he fell and was struck by a plank, never varied. An incision was made over the right motor area, an open fissure which crossed the parietal bone obliquely and extended into the occipital was disclosed, and a large cranial opening made by the trephine and rongeur. An epidural clot extended from the coronal suture into the superior occipital fossa, and from the

median line to the base; it was one and one-half inches in thickness at the site of trephination, and measured four and one-half fluid ounces. The dura mater was uninjured. As hemorrhage was free from some inaccessible point beneath the bone, posteriorly, the large cavity was packed with gauze, which was removed some hours later. In two hours after operation there was some motility of the left leg and in twelve hours sensibility of the left arm. On the following day temperature was normal and fæcal control was regained. On the second day the brain had regained the volume lost by compression; mind clear.

CASE CCLXX.—Male, aged twenty-five years, was struck with an iron poker; no loss of consciousness; compound linear fracture of left parietal bone; paralysis of right forearm and sensation of numbness; no pain or elevation of temperature; trephination and removal of several small depressed fragments of inner table of bone; no apparent subdural lesion. Temperature rose to 101°+. Paralysis had diminished at time of patient's removal from hospital.

CASE CCLXXI.—Male, aged fifty-five years, returned to his house in a dazed condition and unable to speak. On admission to the hospital complete motor aphasia, and two hours later incomplete paralysis of right upper extremity which rapidly increased. Temperature, 100.2°; pulse, 104. A compound fracture of the left parietal bone, nearly circular, three-fourths of an inch in diameter, was situated just above the fissure of Sylvius and just behind the fissure of Rolando. Operation: dural wounds enlarged; cerebral laceration discovered, which extended into lateral ventricle; clot of large size extruded; wound lightly tamponed and closed in part of its extent. The paralysis immediately diminished, but anæsthesia and aphasia were not improved till the third week. A small fungus cerebri appeared on the fourth day, over which on the tenth day the scalp was sutured; there was then right

facial paralysis, and the mental condition was dull. From the third week the fungus gradually disappeared under firm pressure, brachial motion and sensation were gradually restored, and aphasia slowly diminished. The temperature but twice reached 101°; the pulse was usually 80; and the respiration, 20–16. At the end of two months the only remaining symptom was a slight difficulty in speaking when under excitement.

CASE CCLXXII.—Male, aged thirty-eight years, fell from a second-story window; delirious and but semi-conscious upon immediate admission to the hospital, and in same condition when transferred from alcoholic ward to a surgical service next day. Compound depressed fracture of left temporal bone extending into superior occipital fossa; unsymmetrical dilatation of the pupils; pulse full and slow; breathing stertorous; no control of urine and fæces. The bone was elevated, and an epidural clot which extended only toward the base was removed as far as practicable; no discoverable dural or subdural lesion. Third day, left radial pulse fuller and stronger than the right; partial left lower facial paralysis and dysphagia; fourth day, violent delirium; fifth day, dysphagia and cessation of bilateral variation in radial pulse; delirium continued with a short interval, in which it intermitted. The symptoms were variable until the end of the fourth week; delirium of different grades at different times alternated with periods of quietude and rational intelligence; various delusions were more or less persistent; dysphagia, lack of urinary and fæcal control, and facial paralysis still continued. After this time mental improvement was progressive, and in the seventh week the mind was clear. At the end of eight weeks recovery was complete, and twenty pounds lost in weight had been regained. The temperature on admission was 97.6°, on the second day 102°, and after operation 104.4°; it declined to normal at the end of the second week and subsequently varied from normal to 99°+. The pulse and respiration

were never frequent. No mental impairment existed when patient was examined fifteen months later.

CASE CCLXXIII.—Male, aged thirty-five years, fell while dancing and struck the back of his head on the ball-room floor; no loss of consciousness, and no other indication of injury till thirty minutes afterward, when the right upper eyelid began to droop. On examination five hours later, symptoms were confined to right eye and appendages; complete ptosis, external strabismus, paresis of all the ocular muscles, imperfect accommodation, and diplopia; normal pupil and retina. At the end of eighteen months there was still some weakness of the ocular muscles, but no ptosis. The right pupil was permanently dilated.

CASE CCLXXIV.—Male, aged twenty-eight years, received a contusion of the right parietal region, and on the second day began to exhibit symptoms which were observed at the time of examination ten days later: wide dilatation of left pupil; incomplete paralysis of all the ocular muscles and of the elevator of the upper lid of the left eye; anæsthesia of the left conjunctiva and of the mucous membrane of the left nostril, with loss of smell on that side; and intense and constant pain in all the parts included in the distribution of the fifth cranial nerve on the left side. No paralysis of the facial muscles. Some numbness of the left upper extremity. No other symptoms. Ophthalmic examination by Dr. Callan disclosed some cloudiness of the fundus and enlargement of its veins in both eyes; accommodation very imperfect. Two weeks after the injury the hearing in the left ear was lost. The patient eventually entirely recovered.

CASE CCLXXV.—Male, aged sixty-five years, fell thirty feet; consciousness lost, and regained twenty hours after admission to the Presbyterian Hospital; left hemiplegia; temperature, 98°, which fell in four hours to 97°; pulse, 70 to 80; normal pupils; lacerated wound of scalp. Transferred to Belleuve Hospital eighty-two hours after

reception of the injury. There were then delirium with delusions; restlessness; no recognition of changed surroundings; normal pupils and respiration; no paralysis; temperature, 100.5°; pulse, 112. For ten days continued restlessness and at times delirium, with lack of urinary control; temperature, 102.6°; pulse and respiration moderately accelerated. After that time mental condition became normal, at first only during the day, and all symptoms disappeared. Seventeen months afterward his mental and physical condition was entirely restored.

CASE CCLXXVI.—Male, aged thirty-one years, fell two stories upon an iron beam; unconscious and delirious on immediate admission. Wound above the left eye and contusion of the left shoulder; loss of urinary and fæcal control, which was not regained. Subsequently the patient was usually delirious at night and stupid during the day, and without other general symptoms; he was only once or twice able to make coherent reply to a question asked. He died in profound coma at the end of twelve days. Temperature on admission was 99°, rose gradually to 105° on the ninth day, and was 104.8° just before death. The pulse was 82 on admission and the respiration 24, and both afterward varied each day from moderate to extreme frequency.

CASE CCLXXVII.—Male, aged thirty-two years, fell from his truck and struck the back of his head upon the pavement; partial loss of consciousness and delirium, which continued for three days. Fourth day, limited power of comprehension, no response to questions asked, attention fixed only with difficulty, occipital headache which was not increased by pressure or percussion, and somnolence. At the end of four weeks the patient sat up, but walked with difficulty on account of imperfect muscular co-ordination in both legs; patellar reflexes normal; mind clear but slow in action, which he himself noted; vertigo, which was not of previous occurrence; occipital headache relieved. Dr. P. A. Callan discovered upon ocular exam-

ination a neuritis, more advanced upon the right side than upon the left, and a paralysis of the ocular muscles. Temperature on admission was 99°, rose to 100.4° on the same day, was from 99° to 101° till the sixth day, 98.5° to 99°+ till the twenty-first day, and afterward continuously normal. The pulse was normal. The respiration was 12 for three days, 16 to 18 for six days, 8 to 12 for thirteen days, and afterward 16 to 20.

CASE CCLXXVIII. — Male, aged thirty years, fell twenty-five feet from a ship's deck to a raft alongside; consciousness lost for a few moments only; hæmatoma over the right posterior parietal region; moderate contraction of the left pupil; right radial pulse fuller than the left; urine retained; complete paralysis of the left lower extremity; nearly complete paralysis of the left arm; partial paralysis of the right upper extremity; anæsthesia of the right side of the body below the third rib; hyperæsthesia of the left lower extremity; great pain and tenderness in cervico-dorsal region, and evident fracture of the first dorsal spine; mental condition apparently normal.

During the first week vomiting occurred at least once in each twenty-four hours, and pain in the frontal and in the upper dorsal region was constant and severe. The bilateral variation of the pulse was distinct till the fifth day. The paresis, hyperæsthesia, and anæsthesia, and the contraction of the left pupil persisted in greater or less degree for several months and a paresis of the left lower extremity and the anæsthetic and hyperæsthetic conditions and the contracted pupil existed at the time of final discharge from the hospital.

An ophthalmic examination was made by Dr. Callan, and repeated at a later period, with negative result. The eye was retracted and a little less sensitive than the other, but there was no retinal change, and no loss of power in the ocular muscles.

There was no mental disturbance till the occurrence of nocturnal delirium and restlessness at the beginning

of the third week. A few days later the nocturnal delirium ceased, but the restlessness at night increased, and delusions of a painful character began to occur, which occasioned the patient much distress. The first trouble which came to him was the fancied death of his wife, and when, a little later, he became convinced that this bereavement was imaginary, he was equally positive that another delusion, the death of his child, was real, and this new conceit possessed his mind for many weeks. He suffered acute mental anguish in each instance, which could have been scarce exceeded had these pure fancies been actual facts. The facial expression grew a little stupid, and an inclination to weep was manifested on ordinary occasions, equally when the amount of cutaneous hyperæsthesia was tested, or when discourse turned upon his family afflictions, but speech was always coherent. At the end of the second month there was some improvement; the facial expression brightened, delusions were less constant and of a more trivial character, and the mental condition was less uniformly clouded. In the third month delusions altogether disappeared, and mental processes, though slow, were no longer distorted; he was enabled for the first time to recall the manner of his injury; vertigo, which had been an early symptom, still persisted.

The temperature on admission was 98.4°, rose during the day to 101.8°, and on the fifth day reached 105°. It was habitually high till late in the second month at some time in each twenty-four hours, not less than 101°+ to 102°+, the diurnal variations being also considerable. The left axillary temperature was markedly higher than the right, usually five-tenths of a degree or even more. The pulse was ordinarily from 80 to 90, occasionally 60 to 70, and rarely exceeded 100. The respiration during the first month was not often less than 30 and later ranged from 28 to 24.

The patient left the hospital seven months after admission. There was then no trace remaining of the cere-

bral injury beyond a little heaviness of manner and a little slowness of thought. The persistence of the spinal lesions was indicated by a stationary paresis of the left lower extremity and by a continuance of the disorders of sensation which immediately followed the traumatism. The left eye was still retracted and insensitive, and its pupil small.

CASE CCLXXIX.—Male, aged nine years, fell ten feet from a dump into a scow; consciousness lost for fifteen minutes; no external injury; temperature, 98.2°; pulse, 67; respiration, 28. Third to fifth days, right radial pulse fuller and stronger than the left; somnolence till seventh day, and recurrence on the tenth and eleventh days with a condition of mental indifference; occipital pain continued at intervals during ten days. The temperature five hours after admission was 100.2°, in twelve hours was 101°, and did not exceed that degree; it was 99°+ to 100°+ for fourteen days, with an occasional decline to normal for a single observation or for a few hours. The axillary temperatures were observed four times daily, and the left was habitually six-tenths of a degree or more higher than the right, and sometimes the difference was as great as a degree and eight-tenths; they were occasionally symmetrical, but in sixty-eight observations the right was never the higher. The pulse was usually 52 to 84, and more frequently approximated the lower figure. The respiration was from 18 to 28.

CASE CCLXXX.—Male, aged forty-two years, fell in the street, striking the back of his head; consciousness lost, but regained on the way to the hospital; mental condition stupid, but rational, becoming normal in a few hours; slight general headache; later, frontal pain, followed same day by a single general convulsion of five minutes' duration; head and eyes turned to the right; left side and extremities actively convulsed; right arm and leg motionless. On the third day there was transient posterior cervical rigidity, and on the third and fourth days

the left radial pulse was fuller and stronger than the right. During the first ten days the patient's condition was marked by stupor, occasional somnolence, slowness or refusal to answer when questioned, nocturnal delirium becoming continuous, frontal pains, and contracted pupils. In the week following there were delusions, lack of fæcal and urinary control, increased somnolence and stupor, some muttering delirium, and pains in the back of the head and left extremities, suceeded by left paresis. After this time the patient occasionally indicated more intelligence when roused from his habitual stupor, and once conversed intelligently with his wife. The pupils remained contracted and insensitive to light, the urine and fæces uncontrolled, the limbs drawn upward, and any disturbance of the left side of the body was resented. On the twenty-fifth, the last day of life, articulation indistinct, deglutition difficult, and death preceded by restlessness and some brightening of the mental condition. The temperature on admission was 98°, rose to 103.2° on the third day, and was subsequently 99° to 100°+ till the last day, when it was 107.2°. The pulse on admission was 80, on the fifth day 42 to 58, and at other times 68 to 100. The respiration varied from 18 to 24. A few hours before death both pulse and respiration became frequent.

CASE CCLXXXI.—Male, aged twenty (*café au lait*); of feeble intelligence. Was admitted to Bellevue after one day at the Harlem Hospital. He had been struck by a bootblack or by a railroad bridge, as it occurred to his mind at different times. He had a trivial scalp wound in the left parietal region near the median line and a large hæmatoma extending from that point outward and backward. He had no general symptoms except paraplegia with flaccid muscles. There had been no paralysis previous to injury, and there was no evidence of specific disease. The case was regarded as one of pial hemorrhage involving both motor areas, and iodide of potassium was administered; recovery was rapid.

CASE CCLXXXII. — Male, aged twenty-one years, found unconscious in the street; regained consciousness after some hours. He was then unable to give his surname, or to speak beyond reiterating his Christian name. On admission to the hospital, restlessness, general muscular rigidity, hyperæsthesia, dilatation of both pupils which responded slowly and only to strong light, and a small wound in the right temporal region; no fracture disclosed by incision. The muscular rigidity diminished and on the third day there was evident a slight left facial paralysis. The subsequent symptoms were essentially mental. The patient at the end of the first week was actively delirious, and in the second week was the subject of various delusions, and his speech though coherent was voluble and his words were foolish. In the third and fourth weeks his demeanor was more natural and his mind clearer but weak; he remembered some of the circumstances which preceded his injury, but nothing which occurred from that time. He was unable to write figures correctly, writing 186 for 180 or 490005 for 495, and he insisted that he was born in 1891, the ensuing year. The temperature never exceeded 101°, nor after the first five days 99°+; the pulse was 58 to 88.

The patient revisited the hospital two months after his discharge, and was then noisy and excitable.

CASE CCLXXXIII.—Male, aged forty-seven years, was knocked down, the back of his head striking heavily upon the pavement. On admission to the hospital, loss of consciousness, stertor, and slight contusions of the face; pupils normal and pulse 72; subsequent delirium subsiding into stupor, inability of articulation, dysphagia, and left facial paralysis; and later gradual improvement until the end of the third week, when there were for a few days some irritability and mild delirium. From that time until he left the hospital late in the second month the patient had no memory of events immediately preceding his injury or of later occurrence, and no recognition of his sur-

roundings. He usually thought that he was in a man factory and that the medical men were foremen, or, might be, lawyers. His memory of distant events w confused, his laugh was rather vacant, and there was so loss of muscular power on the right side. The temp ature on admission was 100°+, and later varied from t degree to 99°.

CASE CCLXXXIV. — Male, aged twenty-one, w found unconscious in the street and was supposed to ha been assaulted. On admission to the hospital, consciou ness regained, expression of the face vacant, slight wou above the left superciliary ridge; subsequent sympto entirely mental. The patient at first thought he was home, failed to recognize his sister, but knew his o name. On the fourth day he was motionless and spee less unless disturbed, and when questioned answe mechanically; on the next day he constantly attempted get out of bed and out of the ward, and attacked anot patient with a bottle; and on the day following he w again quiet and apathetic. A little later he was violen delirious for three successive nights, but was afterwa quiet and began to take some interest in what went about him; his mind became less confused and he co remember circumstances immediately preceding his hu He was until the fifth week unable to suggest a subject conversation, or to connect ideas, and he laughed mu and without sufficient cause. At a later period his men condition was apparently normal; a slightly weak expr sion of face only remained.

CASE CCLXXXV.—Female, aged seventeen years, f three stories through a hatchway; contusion of left occi tal region; no fracture discovered on incision; gene muscular rigidity; irritability when disturbed; tempe ture, 100.2°; consciousness not fully restored upon adm sion to the hospital. Noisy delirium began on the fou and continued till the ninth day. On the tenth day complete left hemiplegia, dilatation of left pupil, and

loss of fæcal and urinary control which continued for eight days. The paretic condition subsequently improved, and the mental condition was good, when an attack of nostalgia caused the patient's removal from the hospital. The temperature was 100.2° on admission, and was 100°+ for five days, 99°+ for five days and then became normal; it rose on the thirteenth day in fourteen hours from 99° to 103.5°, and in the next twenty-four hours declined to 101°, and rose to 104.5°, and was for two days from 102° to 104°; its subsequent range was from 101.4° to 99.6° to 102°.

CASE CCLXXXVI.—Male, aged thirty-three years, fell three stories and struck upon the right side of his head, causing contusion but no fracture. On admission to the hospital, active delirium, and dilatation of right pupil. The active delirium continued for eleven days with brief daily intermissions, the dilatation of the right pupil for three days, and loss of memory and fæcal control for two days. Facial paralysis, involving both upper and lower face and the tongue, was observed on the eleventh day and existed when patient was discharged from the hospital on the thirty-third day. His mental condition was normal on the thirteenth day, though some transitory delusions occurred a little later. The highest temperature was on the first day, 100.2°, and became normal on the nineteenth day. The pulse never exceeded 100, and was 70 for eight days. The respiration was from 18 to 20.

CASE CCLXXXVII.—Female, aged fifty-seven years, fell one flight of stairs and was unconscious for five minutes. Wound in right frontal region, no fracture, and no general symptoms; no recollection of the manner of injury for twenty-four hours; stupor through the third day, and subsequent vertigo, which existed at the time of the patient's discharge from the hospital on the eighteenth day. The temperature was highest on the second day, 100.2°, and was normal on the tenth day. The right

axillary temperature was one degree higher than the left from the sixth to the ninth days, and the axillary temperatures were afterward symmetrically subnormal.

CASE CCLXXXVIII.—Male, aged twenty-eight years, thrown from a truck against an elevated-railway pillar; loss of consciousness for fifteen minutes, and after an interval of thirty minutes, in which he was able to talk, a recurrence of unconsciousness which was permanent. On admission to the hospital some hours later, pupils dilated, slight muscular contractions in left extremities, irritability, loss of urinary control, right radial pulsations fuller and stronger than the left, respiration irregular, temperature of 99.4°, and a little later contraction of the left pupil. Coma became profound, pulse increased from 68 to 140, both pupils were dilated, the face became cyanotic, respiration momentarily ceased and was artificially restored; death occurred one hour later, twenty-four hours after admission, the respirations having been three in the minute. Temperature, 101.4°, with immediate post-mortem recession.

CASE CCLXXXIX.—Male, aged fourteen years, fell from a truck, and was unconscious for thirty minutes. On admission to the hospital, stupor, vomiting of a dark brown fluid; temperature, 99°; pulse, 100°; respiration, 20. Second and third days, stupor continued, head and eyes turned to the right, posterior cervical muscular rigidity, left radial pulse much stronger than the right, retention of urine; temperature, 99° to 102.4°; pulse, 78, 60, 72; respiration, 28–20. Fourth to sixth days, mental condition brighter, cervical rigidity continued, temperature, 101.6°, declining to 98.6°; pulse, 58–68; respiration, 22–18. Seventh day, several left unilateral convulsions beginning in the upper extremity and involving the face; temperature, 99.8°–99.6°; loss of urinary control after the third day. The patient's condition became normal on the sixteenth day, with no subsequent symptoms; convulsions did not recur.

CASE CCXC.—Male, aged fifty-three years; fell and

struck his head, was dazed for a few moments, walked home, was stupid and somnolent; lost fæcal and urinary control from the first day. On admission to hospital three days later, no external injury or evidence of previous hemorrhage, pupils normal, rigidity of right side, left subconjunctival ecchymosis, and stupid mental condition; answered "Yes" to all questions. On the following day mental condition brighter, but no speech; lack of fæcal and urinary control continued. At the end of the week, patient still answered "Yes" to all questions or began an irrelevant answer which was never finished, and had still lack of urinary and fæcal control, with a slight diminution of muscular power on the right side. In the second week, there were no symptoms except those of mental disorder. He still failed to complete the aswer to a question if it were more than the usual "Yes"; but his mental processes seemed to be normal and his facies was bright. In the third week he answered a greater number of questions intelligently, though many still incongruously with "Yes." He indicated some slowness of comprehension, often going back to a previous question in framing an answer to the one proposed. He recognized his family, but had forgotten where he lived. In the fourth week he was out of bed and ceased to answer "Yes" to questions in general, but under the mental strain of attention his mind often wandered and he was inarticulate or incoherent. He could not give his address, but selected the right one out of several which were suggested. His facial expression was weak. In the sixth week he seemed rational and intelligent, though if questioned he soon broke down and began to answer "Yes" at random, and was unable to tell where he lived. His facies was still weak, and he smiled too much. The temperature on admission was 99°, and never exceeded that degree; his pulse was from 60 to 74, and respiration from 20 to 17. His head was shaved soon after admission, and a contusion then discovered in the left parietal region.

CASE CCXCI.—Male, aged eight years, fell five stories head foremost through an air shaft, and struck his head upon a pile of paper; primary unconsciousness, and convulsions while in the ambulance. On admission to hospital, temperature, 97.4°; pulse and respiration slightly accelerated, lacerated wounds above the right orbit and below the occipital tuber, pupils normal, and great restlessness. The patient during the first week was stupid, heedless of questions, resented disturbance, and required mechanical restraint. His mental condition then became one of dementia; his manner and speech were silly and he wept much; no muscular disorders after the first day, and no loss of fæcal or urinary control at any time. At the end of a month there was no further evidence of mental derangement, but there was a drawl in his speech. The temperature rose to 101°+, and afterward varied from 98.6 to 99°; pulse and respiration were moderately accelerated. The child before his injury was of more than ordinary intelligence, as was indicated by his mental condition after recovery.

CASE CCXCII.—Male, aged fifty-three, stabbed himself with a penknife through an existent trephine opening. Eight years previously he had been struck upon the head by a heavy piece of timber, and had subsequently suffered from left unilateral convulsions, which occurred at two-weeks intervals. Two years later he was trephined at two points in the right parietal bone, anteriorly and posteriorly, near the median line, for their relief, but they afterward increased in frequency and severity. In a fit of rage and despondency he stabbed himself with a knife blade one-half inch in width and two inches in length, through the cutaneous and membranous coverings of the anterior osseous wound. On immediate admission to the hospital, incomplete facial paralysis and complete paralysis of the left side, with muscular rigidity, loss of urinary control, and loss of patellar reflex; mental condition apathetic, and attention fixed with difficulty; nutrition bad, and gen-

eral condition weak; temperature, 99.4°; pulse, 120; respiration, 20. The wound closed by primary union, urinary control was regained, convulsions did not recur; the left elbow was flexed and the left fingers contracted when he left the hospital in the eighth week. Temperature did not exceed 100°+.

INTRACRANIAL LESION FROM PISTOL-SHOT WOUNDS WITH RECOVERY.

CASE CCXCIII.—Male, aged twenty-eight years, shot himself in the right temporal region, using all five barrels of a pistol of 0.22 cal. All the bullets entered a space one inch in diameter just behind and a little above the right external angular process. Each wound was distinct, and apparently made at contact, as there were no burns or traces of powder upon the surface. External hemorrhage was profuse, but there were no shock and no general symptoms. Two bullets were removed from the cutaneous wounds, and one from the masseter muscle, into which it had been deflected. One bullet was undiscovered, and one only penetrated the cranium and was lodged at some distant and unknown point between it and the dura mater, which was uninjured. There were no subsequent symptoms.

CASE CCXCIV.—Bullet of 0.32 cal. External wound one inch above the right zygoma; considerable hemorrhage externally and beneath the conjunctiva; so much protrusion of the eye that the lids could not be closed; entire loss of sight and muscular control. The wound was enlarged by crucial incision, and the skull trephined. The bullet was then detected by an ordinary probe, near the right orbital plate; the eye was removed, the fissured bone sufficiently chiselled away, the dura mater incised, and the ball extracted from the cerebral cortex at the margin of the optic foramen. The wound was drained by tube for two weeks, and the patient when discharged at

the end of two months was apparently entirely well. The only symptoms succeeding operation were delirium for two days, and headache.

CASE CCXCV.—External wound one inch above right zygoma; eye removed by operation, as sight was destroyed, and patient transferred to Bellevue Hospital one week later. The ball was detected beneath the mucous membrane, just above the alveolar process of the right superior maxilla and removed; no subsequent symptoms.

CASE CCXCVI.—External wound above right frontal sinus; calibre of ball, 0.38; range, eighteen inches; smoke area of one-half inch; powder grains embedded in an area, size not noted. The patient was knocked down by the concussion, but did not lose consciousness; walked to the hospital; no general symptom except frontal headache. The external table was fissured in all directions; the bullet was lodged in and below the inner table, with its apex penetrating the dura but not wounding the brain, and was removed, included in a button of bone. No subsequent symptoms.

CASE CCXCVII.—External wound at inner canthus of right eye; calibre of ball, 0.32; range, eight to ten feet; no loss of consciousness or of vision; hemorrhage from the nose. An exploration of its track did not reveal the ball, but led to the opinion that it was located in the body of the sphenoid bone. Violent delirium, which was regarded as a secondary alcoholic mania, supervened, and continued for several days. There were no subsequent symptoms and no further attempt was made to determine the location of the bullet.

CASE CCXCVIII.—External wound one and one-half inches above, and one-half inch in front, of right ear; admitted to Bellevue Hospital four days after the reception of injury; smoke stain still visible upon the ear, and ten or twelve grains of powder embedded in its surface. An incision of the wound had been made at another hospital; the temporal muscle and the bone about the bullet open-

ing was powder stained; osseous wound circular and larger than the ball, which was of 0.32 cal. There had been loss of urinary control for two or three days, but none was observed after admission to Bellevue; no motor or sensory disturbance. Temperature, 100°; pulse, 92; respiration, 20.

CASE CCXCIX.—Female, aged twenty-eight years; pistol-shot wound through right temporal region, inflicted during a paroxysm of suicidal mania; ball of 32 calibre; primary unconsciousness. On admission three hours later no general symptoms; wound of entrance, half an inch posterior to right external angular process, Y-shaped, three-quarters of an inch in length in each of its arms; surface powder stained; some grains of powder embedded in the substance of the temporal muscle, but none in the skin; profuse hemorrhage had occurred from the wound and still continued from the mouth and nose; bullet entrance through the bone small and circular, and covered by a valve of muscular tissue. On examination the patient was fully conscious, rational, and self-possessed. The right eye was swollen, the lids were ecchymotic, and vision on that side was entirely lost. The ball had passed from the temporal fossa beneath the lesser wing of the sphenoid and through the floor of the middle fossa at the margin of the sphenoid body. The track was easily followed through the anterior cerebral lobe, and the bony margin of exit could be defined by slightly opening the blades of the short bullet forceps which had been inserted. A small portion of brain matter, not larger than a pea, escaped from the eternal wound. On the following day she was rather stupid, and another trivial amount of brain matter was extruded. On the third day the left eyelids became moderately ecchymotic and the right side of the face and neck much swollen and painful. There were convulsive movements of the hands and feet, and a loss of smell in the right nostril was confirmed by careful examination. On the fourth day she was quiet and somnolent,

and had some headache. The left side of the mouth was drawn a little upward and tenderness existed behind the left ear. On the fifth day somnolence and headache ceased, pain and swelling of the right side of the face and neck diminished, and the mental condition became brighter. On the tenth day she was restless and began to suffer pain on the right side of the head, which on the succeeding day was intense. The eye became more vascular, swollen, and prominent, and on the fourteenth day was extirpated under ether. At the end of a month the bullet wound of entrance had become simply cutaneous and was in process of cicatrization. The swelling of the right side of the face and neck and the tenderness behind the left ear had ceased to exist. The pain on the right side of the head, which persisted in some degree, was no longer constant or the source of any considerable discomfort. There had been no indication of any form of mental impairment at any time since the slight hebetude on the second and third days after the reception of injury, and no loss of fæcal or urinary control.

The temperature on admission was 100°; rose to 102.4° in twelve hours, and declined to 99.8° on the second day, and then varied from 101°+ to 99°+ till the twelfth day; it did not exceed 100° after the fifteenth day and was subsequently from 99° to 100°. The right axillary temperature was habitually two-tenths of a degree higher than the left. The pulse was from 72 to 80 till the third day, from 68 to 52 till the twelfth day, and subsequently from 70 to 78. The respiration was 28 on admission and afterward normal—16 to 22.

In the sixth week the wound had healed and there were no symptoms. At the end of three months her mental and physical condition was normal—in her own opinion better than before the injury was received. One year later the recurrence of her malady necessitated a return to an asylum for the insane.

CASE CCC.—Male, aged thirty years, transferred from

another hospital two weeks after the infliction of a suicidal pistol-shot wound of the head; ball said to have been of small calibre. A wound, one inch in length, existed one inch above the right external angular process, which was then nearly closed by granulations, but through which a cranial opening could be detected; pupils contracted; radial pulsations symmetrical; diplopia, and internal strabismus of both eyes; perceptible weakness of the muscles of the left arm; burning and tingling sensations in left leg; all reflexes normal; mental condition apathetic with some slowness of comprehension. Ten days later, internal strabismus and diplopia had disappeared, while paretic condition of the muscles of the left arm had increased and extended to the pectoral muscles and to the extensors of the forearm. The flexor muscles of the fingers of the left hand were also involved, and the extensor muscles of the left thigh were weakened and painful. He was discharged from the hospital at the end of the third week after admission without appreciable change in his condition. The temperature had varied from 100.6° to 98.4°; pulse, 96–68; respiration, 24 to 18.

This patient was re-admitted to Bellevue Hospital six months later. In the mean time he had been subjected to the action of the Röntgen rays as a means of discovering the position of the bullet, with the result noted in a subsequent chapter. At this time the paralysis of the left side had increased with contraction of the fingers and of the elbow-joint. His mental condition was one of pronounced dementia with paroxysms of acute mania. The occiput, which had been shaved for exposure to the rays, was still entirely denuded of hair, and the hair bulbs were apparently destroyed.

REFERENCES.

Aran: Archiv. Gén. de Méd., v. vi.

Amidon, R. W.: Annals of Surgery, 1885, v. i., p. 197.

Bergman, E. von: Clin. Lects. Translated by J. W. C. S
nals of Surg., 1882.

Boise, Eugene: Nature of Shock. N. Y. J. of Gyn. and
tober, 1895.

Bourneville: Études Chirurg. et Thermom. sur les Mal.
p. 116.

Bradford, E. H., and Smith, H. L.: Trans. Am. Med. A
ix.

Chaumel-Neimeir: Pratique de Chirurg. d'Armée, 1890.

Clark, Alonzo: Lectures, 1856–60.

Dana, C. L.: Hamilton's Syst. of Legal Med., v. ii., p. 2

Dennis, F. S.: Head-Injs. Med. News, January 5, 1894.

Duret: Études Expér. et Chirurg., t. i., 1878.

Eskridge, J. T.: N. Y. M. J., v. lxii., p. 168.

Eulenberg, A.: Deutsche medicinische Wochenschrift, N

Fluhrer, W. F.: N. Y. M. J., 1885.

Girdner, Jno. H.: N. Y. M. J., March, 1893.

Gouley, J. W. S.: Diseases of Men, etc., 1888.

Gross, S. W.: Am. J. Med. Sci., v. lxvi., p. 69.

Hare, A. H.: Lancet, 1888, v. i., p. 207 *et seq.*

Hewitt, Prescott: Holmes' Syst. of Surg., v. ii., pp. 298–

Hunter, Jno.: Blood, Inflam., and Gs. Wds., 1794.

Hutchinson, Jonathan: London Hosp. Reports, v. iv.

Hurst, C. L.: Trans. Aust. Intercol. Med. Asso., 1892.

Legarde, L. A.: Report of Surg.-Gen. U. S. Army, 1892

Longmore, Thos.: Lancet, 1865, v. i., p. 649.

Macewen, Wm.: Pyogen. Infect. Dis. of Brain and Spina

Meyer, Willy: Annals of Surgery, April, 1897.

Miles, Alex.: Brain, 1892, p. 153.

McCosh, A. J.: Am. J. Med. Sci., March, 1894.

Park, Roswell: Dennis' Syst. of Surg., v. ii., p. 497.

Ruth, C. E.: Kans. City Med. Index, 1893, v. xiv., p. 281

Starr, M. A.: Brain Surgery, 1893, p. 161.

Sutton, J. Bland: Evolution and Disease.

Wharton, R. M.: Phila. Med. Times, July, 1879, p. 316.

Established by EDWARD L. YOUMANS.

THE POPULAR SCIENCE MONTHLY,

Edited by WILLIAM JAY YOUMANS,

Well known as a trustworthy medium for the spread of scientific truth in popular form, is filled with articles of interest to everybody, by the ablest writers of the time. Its range of topics, which is widening with the advance of science, includes--

PREVENTION OF DISEASE AND IMPROVEMENT OF THE RACE.
AGRICULTURAL AND FOOD PRODUCTS.
SOCIAL AND DOMESTIC ECONOMY.
POLITICAL SCIENCE, OR THE CONDUCT OF GOVERNMENT.
SCIENTIFIC ETHICS; MENTAL SCIENCE AND EDUCATION.
MAN'S ORIGIN AND DEVELOPMENT.
RELATIONS OF SCIENCE AND RELIGION.
THE INDUSTRIAL ARTS.
NATURAL HISTORY; DISCOVERY; EXPLORATION, ETC.

With other illustrations, each number contains a finely engraved Portrait of some eminent scientist, with a Biographical Sketch.

Among its recent contributors are :

W. A. HAMMOND, M. D.,
HERBERT SPENCER,
DAVID A. WELLS,
T. H. HUXLEY,
Sir JOHN LUBBOCK,
EDWARD ATKINSON,
T. D. CROTHERS, M. D.,
W. K. BROOKS,
E. D. COPE,
DAVID STARR JORDAN,
T. MITCHELL PRUDDEN, M. D.,
JOSEPH LE CONTE,
APPLETON MORGAN,
FELIX L. OSWALD,
J. S. BILLINGS, M. D.,
BENJ. WARD RICHARDSON, M. D.,
ANDREW D. WHITE,
F. W. CLARKE,
HORATIO HALE,
EDWARD S. MORSE,
J. S. NEWBERRY,
WALTER B. PLATT, M. D.,
EUGENE L. RICHARDS,
THOMAS HILL,
N. S. SHALER,
D. G. THOMPSON,
AMBROSE L. RANNEY, M. D.,
GRANT ALLEN,
Sir WILLIAM DAWSON,
J. HUGHLINGS JACKSON, M. D.

Subscription price, $5.00 per Annum.

New York: D. APPLETON & CO., 72 Fifth Avenue.

THE PRINCIPLES OF SURGERY A SURGICAL PATHOLOGY.

General Rules governing Operations and the Application of Dress

By Dr. HERMANN TILLMANNS,

Professor at the University of Leipzig.

Translated from the third German edition, by JOHN ROGERS, M. D., Nev and BENJAMIN TILTON, M. D., New York.

Edited by LEWIS A. STIMSON, M. D., Professor of Surgery in the Univ the City of New York, Medical Department.

8vo. 800 pages. With 441 Illustrations.

Cloth, $5.00; sheep, $6.00.

"It was a wise combination of subjects in considering the principles of sur its pathology in the same treatise. It enables the surgeon to refer to both bra the subject without loss of time, and each serves to accentuate the importanc other. Not since Billroth's classic treatise on surgical pathology, that appear twenty-three years ago, has there been a more satisfactory exposition of pathology than here given by Tillmanns. It is brought down to the immediate under the light afforded by the most modern researches in bacteriology. A should be taught pathology before he is instructed in surgical diseases and These latter he will then understand with a clearness that could not be possib method of teaching were reversed. The editor and the translators appreciat fact have duly emphasized it in bringing out and making available as a text-b of the best treatises on the principles of surgery and surgical pathology that been written. It is impossible in the space now at our disposal for us to do m express our opinion of this excellent work and to commend it to student an tioner as a safe and scientific guide, which we do here and now."—*Buffalo and Surgical Journal.*

"It is strange that this excellent work has been allowed to pass to a third in German, without a translation in English until this time. The arrange the book is different from that of the average text-book on the subject. It is into three sections: First, General Principles governing Surgical Operations; Methods of applying Surgical Dressings; and third, Surgical Pathology and T The work of translators and editor has been excellently done. The book is and bound in the correct and elegant style for which the publishers are note work is strictly modern, and none of the recent advances in surgical patholc been left unconsidered."—*Chicago Medical Recorder.*

"It is just the book for surgeons who entered practice before surgical bact had been developed so as to afford, as it now does, a firm foundation for clinical work. By its aid one's knowledge of the results of most recent invest can be, so to speak, brought up to date. No surgeon, however experienced, c it without having his *technique* consciously or unconsciously improved, and h upon the fixed facts of surgical science made more secure. In illustration paper, and binding, Tillmanns's 'Surgical Pathology' is up to the Appleton st and that standard, as we all know, is unsurpassed."—*Canada Lancet.*

New York: D. APPLETON & CO., 72 Fifth Avenue.

August, 1897.

MEDICAL

AND

HYGIENIC WORKS

PUBLISHED BY

D. APPLETON & CO., 72 Fifth Avenue, New York.

AULDE (JOHN). The Pocket Pharmacy, with Therapeutic Index. A *résumé* of the Clinical Applications of Remedies adapted to the Pocket-case, for the Treatment of Emergencies and Acute Diseases. 12mo. Cloth, $2.00.

BARKER (FORDYCE). On Sea-Sickness. A Popular Treatise for Travelers and the General Reader. Small 12mo. Cloth, 75 cents.

BARKER (FORDYCE). On Puerperal Disease. Clinical Lectures delivered at Bellevue Hospital. A Course of Lectures valuable alike to the Student and the Practitioner. Third edition. 8vo. Cloth, $5.00; sheep, $6.00.

BARTHOLOW (ROBERTS). A Treatise on Materia Medica and Therapeutics. **Ninth edition.** Revised, enlarged, and adapted to "The New Pharmacopœia." 8vo. Cloth, $5.00; sheep, $6.00.

BARTHOLOW (ROBERTS). A Treatise on the Practice of Medicine, for the Use of Students and Practitioners. **Seventh edition,** revised and enlarged. 8vo. Cloth, $5.00; sheep, $6.00.

BARTHOLOW (ROBERTS). On the Antagonism between Medicines and between Remedies and Diseases. Being the Cartwright Lectures for the Year 1880. 8vo. Cloth, $1.25.

BASTIAN (H. CHARLTON). Paralyses: Cerebral, Bulbar, and Spinal. A Manual of Diagnosis for Students and Practitioners. With 136 Illustrations. Small 8vo, 671 pages. Cloth, $4.50.

BASTIAN (H. CHARLTON). Paralysis from Brain Disease in its Common Forms. With Illustrations. 12mo, 340 pages. Cloth, $1.75.

BILLINGS (F. S.). The Relation of Animal Diseases to the Public Health, and their Prevention. 8vo. Cloth, $4.00.

BILLROTH (THEODOR). General Surgical Pathology and Therapeutics. A Text-Book for Students and Physicians. Translated from the tenth German edition, by special permission of the author, by Charles E. Hackley, M. D. **Fifth American edition, revised and enlarged.** 8vo. Cloth, $5.00; sheep, $6.00.

BOYCE (RUBERT). A Text-Book of Morbid Histology. For Students and Practitioners. With 130 Colored Illustrations. Cloth, $7.50.

BRAMWELL (BYROM). Diseases of the Heart and Thoracic Aorta. Illustrated with 226 Wood-Engravings and 68 Lithograph Plates—showing 91 Figures—in all 317 Illustrations. 8vo. Cloth, $8.00; sheep, $9.00.

BRYANT (JOSEPH D.). A Manual of Operative Surgery. **New edition, revised and enlarged.** 793 Illustrations. 8vo. Cloth, $5.00; sheep, $6.00.

BURT (STEPHEN S.). Exploration of the Chest in Health and Disease. 8vo. 210 pages. With Illustrations. Cloth, $1.50.

CAMPBELL (F. R.). The Language of Medicine. A Manual giving the Etymology, Pronunciation, and Meaning of the Technical Terms fo Medical Literature. 8vo. Cloth, $3.00.

CARMICHAEL (JAMES). Disease in Children. A Manual for Studer Practitioners. Illustrated with Thirty-one Charts. 12mo, 591 (STUDENTS' SERIES.) Cloth, $3.00.

CHAUVEAU (A.). The Comparative Anatomy of the Domesticated A Revised and enlarged, with the co-operation of S. Arloing, Director Lyons Veterinary School. Second English edition. Translated and by George Fleming, C. B., LL. D., F. R. C. V. S., late Principal Vet Surgeon of the British Army; Foreign Corresponding Member Société Royale de Médecine, and of the Société Royale de Médecin lique, of Belgium, etc. 8vo, 1084 pages, with 585 Illustrations. Cloth,

CORNING (J. L.). Brain Exhaustion, with some Preliminary Conside on Cerebral Dynamics. Crown 8vo. Cloth, $2.00.

CORNING (J. L.). Local Anæsthesia in General Medicine and Surgery. the Practical Application of the Author's Recent Discoveries. Wit trations. Small 8vo. Cloth, $1.25.

DAVIDSON (ANDREW). Geographical Pathology: An Inquiry in Geographical Distribution of Infective and Climatic Diseases. 8vo. Cloth, $7.00.

DENCH (E. B.). Diseases of the Ear. A Text-Book for Practitione Students of Medicine. With 8 Colored Plates and 152 Illustrations text. 8vo. Cloth, $5.00; sheep, $6.00.

DEXTER (FRANKLIN). The Anatomy of the Peritonæum. 12mo. 39 colored Illustrations. Cloth, $1.50.

DOTY (ALVAH H.). A Manual of Instruction in the Principles of F Aid to the Injured. Including a Chapter on Hygiene and the Drill F tions for the Hospital Corps, U. S. A. Designed for Military and Civ **Second edition, revised and enlarged.** 12mo. 121 Illustrations. Cloth,

ELLIOT (GEORGE T.). Obstetric Clinic: A Practical Contribution to the of Obstetrics and the Diseases of Women and Children. 8vo. Cloth,

EVANS (GEORGE A.). Hand-Book of Historical and Geographical P ology. With Special Reference to the Distribution of Consumption United States. 8vo. Cloth, $2.00.

EWALD (C. A.). Lectures on the Diseases of the Stomach. By Dr. Ewald, Professor of Pathology and Therapeutics in the University of etc. Translated from the German by special permission of the auth Morris Manges, A. M., M. D. **Second edition, revised and rearranged.** $5.00; sheep, $6.00.

FLINT (AUSTIN). Medical Ethics and Etiquette. Commentaries National Code of Ethics. 12mo. Cloth, 60 cents.

FLINT (AUSTIN). Medicine of the Future. An Address prepared f Annual Meeting of the British Medical Association in 1886. With I of Dr. Flint. 12mo. Cloth, $1.00.

FLINT (AUSTIN, JR.). Text-Book of Human Physiology; designed Use of Practitioners and Students of Medicine. Illustrated with hundred and sixteen Woodcuts and Two Plates. **Fourth edition,** Imperial 8vo. Cloth, $6.00; sheep, $7.00.

FLINT (AUSTIN, JR.). The Physiological Effects of Severe and Pro Muscular Exercise; with Special Reference to its Influence upon the tion of Nitrogen. 12mo. Cloth, $1.00.

FLINT (AUSTIN, JR.). The Source of Muscular Power. Arguments and Conclusions drawn from Observation upon the Human Subject under Conditions of Rest and of Muscular Exercise. 12mo. Cloth, $1.00.

FLINT (AUSTIN, JR.). Physiology of Man. Designed to represent the Existing State of Physiological Science as applied to the Functions of the Human Body. Complete in 5 vols., 8vo. Per vol., cloth, $4.50; sheep, $5.50.

*** Vols. I and II can be had in cloth and sheep binding; Vol. III in sheep only. Vol. IV is at present out of print.

FLINT (AUSTIN, JR.). Manual of Chemical Examinations of the Urine in Disease; with Brief Directions for the Examination of the most Common Varieties of Urinary Calculi. Revised edition. 12mo. Cloth, $1.00.

FOSTER (FRANK P.). Illustrated Encyclopædic Medical Dictionary: Being a Dictionary of the Technical Terms used by Writers on Medicine and the Collateral Sciences in the Latin, English, French, and German Languages. The work consists of Four Volumes, and is sold in Parts; Three Parts to a Volume. (*Sold only by subscription.*)

FOSTER (FRANK P.). A Reference-Book of Practical Therapeutics, by various writers. In Two Volumes. Edited by Frank P. Foster, M. D., Editor of The New York Medical Journal. Vol. I. Cloth, $5.00; sheep, $6.00; half morocco, $6.50. (*Sold only by subscription.*)

FOURNIER (ALFRED). Syphilis and Marriage. Translated by P. Albert Morrow, M. D. 8vo. Cloth, $2.00; sheep, $3.00.

FREY (HEINRICH). The Histology and Histochemistry of Man. A Treatise on the Elements of Composition and Structure of the Human Body. Translated from the fourth German edition by Arthur E. J. Barker, M. D., and revised by the author. With 608 Engravings on Wood. 8vo. Cloth, $5.00; sheep, $6.00.

FRIEDLANDER (CARL). The Use of the Microscope in Clinical and Pathological Examinations. Second edition, enlarged and improved, with a Chromolithograph Plate. Translated, with the permission of the author, by Henry C. Coe, M. D. 8vo. Cloth, $1.00.

FUCHS (ERNEST). Text-Book of Ophthalmology. By Dr. Ernest Fuchs, Professor of Ophthalmology in the University of Vienna. With 178 Woodcuts. Authorized translation from the second enlarged and improved German edition, by A. Duane, M. D. Cloth, $5.00; sheep, $6.00.

GARMANY (JASPER J.). Operative Surgery on the Cadaver. With Two Colored Diagrams showing the Collateral Circulation after Ligatures of Arteries of Arm, Abdomen, and Lower Extremity. Small 8vo. Cloth, $2.00.

GERSTER (ARPAD G.). The Rules of Aseptic and Antiseptic Surgery. A Practical Treatise for the Use of Students and the General Practitioner. Illustrated with over two hundred fine Engravings. 8vo. Cloth, $5.00; sheep, $6.00.

GIBSON-RUSSELL. Physical Diagnosis: A Guide to Methods of Clinical Investigation. By G. A. Gibson, M. D., and William Russell, M. D. With 101 Illustrations. 12mo. (STUDENT'S SERIES.) Cloth, $2.50.

GOULEY (JOHN W. S.). Diseases of the Urinary Apparatus. Part I. Phlegmasic Affections. Being a Series of Twelve Lectures delivered during the autumn of 1891. With an Addendum on Retention of Urine from Prostatic Obstruction in Elderly Men. Cloth, $1.50.

GROSS (SAMUEL W.). A Practical Treatise on Tumors of the Mammary Gland. Illustrated. 8vo. Cloth, $2.50.

GRUBER (JOSEF). A Text-Book of the Diseases of the Ear. Translated from the second German edition by special permission of the author, and edited by Edward Law, M. D., and Coleman Jewell, M. D. With 165 Illustrations and 70 Colored Figures on Two Lithographic Plates. 8vo. Cloth, $6.50 sheep, $7.50.

GUTMANN (EDWARD). The Watering-Places and Mineral Springs of Germany, Austria, and Switzerland. Illustrated. 12mo. Cloth, $2.50.

HAMMOND (W. A.). A Treatise on Diseases of the Nervous System. With the Collaboration of Graeme M. Hammond, M. D. With One Hundred and Eighteen Illustrations. **Ninth edition,** with corrections and additions. 8vo. Cloth, $5.00; sheep, $6.00.

HAMMOND (W. A.). A Treatise on Insanity, in its Medical Relations. 8vo. Cloth, $5.00; sheep, $6.00.

HAMMOND (W. A.). Clinical Lectures on Diseases of the Nervous System. Delivered at Bellevue Hospital Medical College. Edited by T. M. B. Cross, M. D. 8vo. Cloth, $3.50.

HARVEY (A.). First Lines of Therapeutics. 12mo. Cloth, $1.50.

HIRT (LUDWIG). The Diseases of the Nervous System. A Text-Book for Physicians and Students. Translated, with permission of the Author, by August Hoch, M. D., assisted by Frank R. Smith, A. M. (Cantab.), M. D., Assistant Physicians to the Johns Hopkins Hospital. With an Introduction by William Osler, M. D., F. R. C. P., Professor of Medicine in the Johns Hopkins University, and Physician-in-Chief to the Johns Hopkins Hospital, Baltimore. 8vo, 671 pages. With 178 Illustrations. Cloth, $5.00; sheep, $6.00.

HOFFMANN-ULTZMANN. Analysis of the Urine, with Special Reference to Diseases of the Urinary Apparatus. By M. B. Hoffmann, Professor in the University of Grätz, and R. Ultzmann, Tutor in the University of Vienna. **Third edition, revised and enlarged.** 8vo. Cloth, $2.00.

HOLT (L. EMMETT). The Diseases of Infancy and Childhood. 8vo. Cloth, $6.00; sheep, $7.00; half morocco, $7.50. (*Sold only by subscription.*)

HOLT (L. EMMETT). The Care and Feeding of Children. A Catechism for the Use of Mothers and Children's Nurses. 16mo. Cloth, 50 cents.

HOWE (JOSEPH W.). Emergencies, and how to treat them. Fourth edition, revised. 8vo. Cloth, $2.50.

HOWE (JOSEPH W.). The Breath, and the Diseases which give it a Fetid Odor. With Directions for Treatment. **Second edition,** revised and corrected. 12mo. Cloth, $1.00.

HUEPPE (FERDINAND). The Methods of Bacteriological Investigation. Written at the request of Dr. Robert Koch. Translated by Hermann M. Biggs, M. D. Illustrated. 8vo. Cloth, $2.50.

JACCOUD (S.). The Curability and Treatment of Pulmonary Phthisis. Translated and edited by Montagu Lubbock, M. D. 8vo. Cloth, $4.00.

KEYES (E. L.). A Practical Treatise on Genito-Urinary Diseases, including Syphilis. Being a new edition of a work with the same title by Van Buren and Keyes. Almost entirely rewritten. 8vo. With Illustrations. Cloth, $5.00; sheep, $6.00.

KEYES (E. L.). The Tonic Treatment of Syphilis, including Local Treatment of Lesions. **Second edition.** 8vo. Cloth, $1.00.

KINGSLEY (N. W.). A Treatise on Oral Deformities as a Branch of Mechanical Surgery. With over 350 Illustrations. 8vo. Cloth, $5.00; sheep, $6.00.

LEGG (J. WICKHAM). On the Bile, Jaundice, and Bilious Diseases. With Illustrations in Chromolithography. 8vo. Cloth, $6.00; sheep, $7.00.

LITTLE (W. J.). Medical and Surgical Aspects of In-Knee (Genu-Valgum): Its Relation to Rickets, its Prevention, and its Treatment, with and without Surgical Operation. Illustrated by upward of Fifty Figures and Diagrams. 8vo. Cloth, $2.00.

LORING (EDWARD G.). A Text-Book of Ophthalmoscopy.

Part I. The Normal Eye, Determination of Refraction, and Diseases of the Media. With 131 Illustrations, and 4 Chromolithographs. 8vo. Buckram, $5.00.

Part II. Diseases of the Retina, Optic Nerve, and Choroid: their Varieties and Complications. The manuscript of this volume, which the author finished just prior to his death, has been thoroughly edited and revised by F. B. Loring, M. D., of Washington, D. C., and is now issued in the same style as the first volume. Profusely illustrated. Part II, buckram, $5.00. Two Parts, buckram, $10.00.

LUSK (WILLIAM T.). The Science and Art of Midwifery. With 246 Illustrations. **Fourth edition, revised and enlarged.** 8vo. Cloth, $5.00; sheep, $6.00.

MARCY (HENRY O.). The Anatomy and Surgical Treatment of Hernia. 4to, with about Sixty full-page Heliotype and Lithographic Reproductions from the Old Masters, and numerous Illustrations in the Text. *(Sold only by subscription.)*

MARKOE (T. M.). A Treatise on Diseases of the Bones. With Illustrations. 8vo. Cloth, $4.50.

MATHEWS (JOSEPH M.). A Treatise on Diseases of the Rectum, Anus, and Sigmoid Flexure. 8vo. With Six Chromolithographs, and Illustrations in the text. **Second edition.** *(Sold only by subscription.)*

MILLS (WESLEY). A Text-Book of Animal Physiology, with Introductory Chapters on General Biology and a full Treatment of Reproduction for Students of Human and Comparative Medicine. 8vo. With 505 Illustrations. Cloth, $5.00; sheep, $6.00.

MILLS (WESLEY). A Text-Book of Comparative Physiology. For Students and Practitioners of Veterinary Medicine. Small 8vo. Cloth, $3.00.

MORROW (PRINCE A.). A System of Genito-Urinary Diseases, Syphilology, and Dermatology. By various Authors. In Three Volumes, beautifully illustrated. Vol. I. Genito-urinary Diseases. Vol. II. Syphilography Vol. III. Dermatology. *(Sold only by subscription.)*

THE NEW YORK MEDICAL JOURNAL (Weekly). Edited by Frank P. Foster, M. D. Terms, $5.00 per annum.

Binding Cases, cloth, 50 cents each.

"Self-Binder" (this is used for temporary binding only), 90 cents.

GENERAL INDEX, from April, 1865, to June, 1876 (23 vols.). 8vo. Cloth, 75 cts.

NIEMEYER (FELIX VON). A Text-Book of Practical Medicine, with particular reference to Physiology and Pathological Anatomy. Containing all the author's Additions and Revisions in the eighth and last German edition. Translated by George H. Humphreys, M. D., and Charles E. Hackley, M. D. 2 vols., 8vo. Cloth, $9.00; sheep, $11.00.

NIGHTINGALE'S (FLORENCE) Notes on Nursing. 12mo. Cloth, 75 cents.

OSLER (WILLIAM). Lectures on Angina Pectoris and Allied States. Small 8vo. Illustrated. Cloth, $1.50.

OSLER (WILLIAM). Lectures on the Diagnosis of Abdominal Tumors. Small 8vo. Illustrated. Cloth, $1.50.

OSLER (WILLIAM). The Principles and Practice of Medicine. Designed for the Use of Practitioners and Students of Medicine. **Second edition, revised and enlarged.** Cloth, $5.50; sheep, $6.50; half morocco, $7.00. (*Sold only by subscription.*)

PELLEW (C. E.). A Manual of Practical Medical Chemistry. 12mo. With Illustrations. Cloth, $2.50.

PIFFARD (HENRY G.). A Practical Treatise on Diseases of the Skin. By Henry G. Piffard, A. M., M. D., assisted by Robert M. Fuller, M. D. With Fifty full-page Original Plates and Thirty-three Illustrations in the Text. 4to. (*Sold only by subscription.*)

POMEROY (OREN D.). The Diagnosis and Treatment of Diseases of the Ear. With One Hundred Illustrations. **Second edition,** revised and enlarged. 8vo. Cloth, $3.00.

POORE (C. T.). Osteotomy and Osteoclasis, for the Correction of Deformities of the Lower Limbs. 50 Illustrations. 8vo. Cloth, $2.50.

QUAIN (RICHARD). A Dictionary of Medicine, including General Pathology, General Therapeutics, Hygiene, and the Diseases peculiar to Women and Children. By Various Writers. Edited by Sir Richard Quain, Bart., M. D., LL. D., etc. Assisted by Frederick Thomas Roberts, M. D., B. Sc., and J. Mitchell Bruce, M. A., M. D. With an American Appendix by Samuel Treat Armstrong, Ph. D., M. D. In two volumes. (*Sold only by subscription.*)

RANNEY (AMBROSE L.). Applied Anatomy of the Nervous System, being a Study of this Portion of the Human Body from a Standpoint of its General Interest and Practical Utility, designed for Use as a Text-Book and as a Work of Reference. **Second edition, revised and enlarged.** Profusely illustrated. 8vo. Cloth, $5.00; sheep, $6.00.

ROBINSON (A. R.). A Manual of Dermatology. Revised and corrected. 8vo. Cloth, $5.00.

ROSCOE–SCHORLEMMER. Treatise on Chemistry.

Vol. 1. Non-Metallic Elements. 8vo. Cloth, $5.00.

Vol. 2. Part I. Metals. 8vo. Cloth, $3.00.

Vol. 2. Part II. Metals. 8vo. Cloth, $3.00.

Vol. 3. Part I. The Chemistry of the Hydrocarbons and their Derivatives. 8vo. Cloth, $5.00.

Vol. 3. Part II. The Chemistry of the Hydrocarbons and their Derivatives. 8vo. Cloth, $5.00.

Vol. 3. Part III. The Chemistry of the Hydrocarbons and their Derivatives. 8vo. Cloth, $3.00.

Vol. 3. Part IV. The Chemistry of the Hydrocarbons and their Derivatives. 8vo. Cloth, $3.00.

Vol. 3. Part V. The Chemistry of the Hydrocarbons and their Derivatives. 8vo. Cloth, $3.00.

ROSENTHAL (I.). General Physiology of Muscles and Nerves. With 75 Woodcuts. 12mo. Cloth, $1.50.

SAYRE (LEWIS A.). Practical Manual of the Treatment of Club-Foot. **Fourth edition, enlarged and corrected.** 12mo. Cloth, $1.25.

SAYRE (LEWIS A.). Lectures on Orthopedic Surgery and Diseases of the Joints, delivered at Bellevue Hospital Medical College. **New edition,** illustrated with 224 Engravings on Wood. 8vo. Cloth, $5.00; sheep, $6.00.

SCHULTZE (B. S.). The Pathology and Treatment of Displacements of the Uterus. Translated from the German by Jameson J. Macan, M. A., etc.; and edited by Arthur V. Macan, M. B., etc. With one hundred and twenty Illustrations. 8vo. Cloth, $3.50.

SHIELD (A. MARMADUKE). Surgical Anatomy for Students. 12mo. (STUDENT'S SERIES.) Cloth, $1.75.

SHOEMAKER (JOHN V.). A Text-Book of Diseases of the Skin. Six Chromolithographs and numerous Engravings. Second edition, revised and enlarged. 8vo. Cloth, $5.00; sheep, $6.00.

SIMPSON (JAMES Y.). Selected Works: Anæsthesia, Diseases of Women. 3 vols., 8vo. Per volume. Cloth, $3.00; sheep, $4.00.

SIMS (J. MARION). The Story of my Life. Edited by his Son, H. Marion-Sims, M. D. With Portrait. 12mo. Cloth, $1.50.

SKENE (ALEXANDER J. C.). A Text-Book on the Diseases of Women. Illustrated with two hundred and fifty-four Illustrations, of which one hundred and sixty-five are original, and nine chromolithographs. Second edition. 8vo. (*Sold only by subscription.*)

SKENE (ALEXANDER J. C.). Medical Gynecology. A Treatise on the Diseases of Women from the Standpoint of the Physician. 8vo. With Illustrations. Cloth, $5.00.

STEINER (JOHANN). Compendium of Children's Diseases: a Hand-Book for Practitioners and Students. Translated from the second German edition, by Lawson Tait. 8vo. Cloth, $3.50; sheep, $4.50.

STEVENS (GEORGE T.) Functional Nervous Diseases: their Causes and their Treatment. Memoir for the Concourse of 1881–1883, Académie Royal de Médecine de Belgique. With a Supplement, on the Anomalies of Refraction and Accommodation of the Eye, and of the Ocular Muscles. Small 8vo. With six Photographic Plates and twelve Illustrations. Cloth, $2.50.

STONE (R. FRENCH). Elements of Modern Medicine, including Principles of Pathology and of Therapeutics, with many Useful Memoranda and Valuable Tables of Reference. Accompanied by Pocket Fever Charts. Designed for the Use of Students and Practitioners of Medicine. In wallet-book form, with pockets on each cover for Memoranda, Temperature Charts, etc. Roan, tuck, $2.50.

STRECKER (ADOLPH). Short Text-Book of Organic Chemistry. By Dr. Johannes Wislicenus. Translated and edited, with Extensive Additions, by W. H. Hodgkinson and A. J. Greenaway. 8vo. Cloth, $5.00.

STRÜMPELL (ADOLPH). A Text-Book of Medicine, for Students and Practitioners. Translated, by permission, from the sixth German edition by Herman F. Vickery, A. B., M. D., Instructor in Clinical Medicine, Harvard Medical School, etc., and Philip Coombs Knapp, Physician to Outpatients with Diseases of the Nervous System, Boston City Hospital, etc. With Editorial Notes by Frederick C. Shattuck, A. M., M. D., Jackson Professor of Clinical Medicine, Harvard Medical School, etc. Second American edition. With 111 Illustrations. 8vo. 981 pages. Cloth, $6.00; sheep, $7.00.

THOMAS (T. GAILLARD). Abortion and its Treatment, from the Standpoint of Practical Experience. A Special Course of Lectures delivered before the College of Physicians and Surgeons, New York, Session of 1889–'90. From Notes by P. Brynberg Porter, M.D. Revised by the Author. 12mo. Cloth, $1.00.

THOMPSON (W. GILMAN). Practical Dietetics, with Special Reference to Diet in Disease. 8vo. Cloth, $5.00.

THOMSON (J. ARTHUR). Outlines of Zoölogy. With thirty-two full-page Illustrations. 12mo. (STUDENTS' SERIES.) Cloth, $3.00.

TILLMANNS (HERMANN). The Principles of Surgery and Surgical Pathology. Translated by John Rogers, M. D., and Benjamin Tilton, M. D., New York. 8vo. With 441 Illustrations. Cloth, $5.00; sheep, $6.00.

ULTZMANN (ROBERT). Pyuria, or Pus in the Urine, and its Treatment. Translated by permission, by Dr. Walter B. Platt. 12mo. Cloth, $1.00.

VAN BUREN (W. H.). Lectures upon Diseases of the Rectum, and the Surgery of the Lower Bowel, delivered at Bellevue Hospital Medical College. **Second edition, revised and enlarged.** 8vo. Cloth, $3.00; sheep, $4.00.

VAN BUREN (W. H.). Lectures on the Principles and Practice of Surgery. Delivered at Bellevue Hospital Medical College. Edited by Lewis A. Stimson, M. D. 8vo. Cloth, $4.00; sheep, $5.00.

VOGEL (A.). A Practical Treatise on the Diseases of Children. Translated and edited by H. Raphael, M. D. **Third American from the eighth German edition, revised and enlarged.** Illustrated by six Lithographic Plates. 8vo. Cloth, $4.50; sheep, $5.50.

VON ZEISSL (HERMANN). Outlines of the Pathology and Treatment of Syphilis and Allied Venereal Diseases. **Second edition,** revised by Maximilian von Zeissl. Authorized edition. Translated, with Notes, by H. Raphael, M. D. 8vo. Cloth, $4.00; sheep, $5.00.

WAGNER (RUDOLF). Hand-Book of Chemical Technology. Translated and edited from the eighth German edition, with extensive Additions, by William Crookes. With 336 Illustrations. 8vo. Cloth, $5.00.

WALTON (GEORGE E.). Mineral Springs of the United States and Canadas. Containing the latest Analyses, with full Description of Localities, Routes, etc. **Second edition, revised and enlarged.** 12mo. Cloth, $2.00.

WEBBER (S. G.). A Treatise on Nervous Diseases: Their Symptoms and Treatment. A Text-Book for Students and Practitioners. 8vo. Cloth, $3.00.

WEEKS–SHAW (CLARA S.). A Text-Book of Nursing. For the Use of Training-Schools, Families, and Private Students. Second edition, revised and enlarged. 12mo. With Illustrations, Questions for Review and Examination, and Vocabulary of Medical Terms. 12mo. Cloth, $1.75.

WELLS (T. SPENCER). Diseases of the Ovaries. 8vo. Cloth, $4.50.

WORCESTER (A.). Monthly Nursing. **Second edition, revised.** Cloth, $1.25.

WYETH (JOHN A.). A Text-Book on Surgery: General, Operative, and Mechanical. Profusely illustrated. **Second edition. revised and enlarged.** 8vo. (*Sold only by subscription.*)

LANE MEDICAL LIBRARY

To avoid fine, this book should be returned on
or before the date last stamped below.

M593 Phelps,C. 2613
P54 Traumatic injuries of
1897 the brain

NAME | DATE DUE